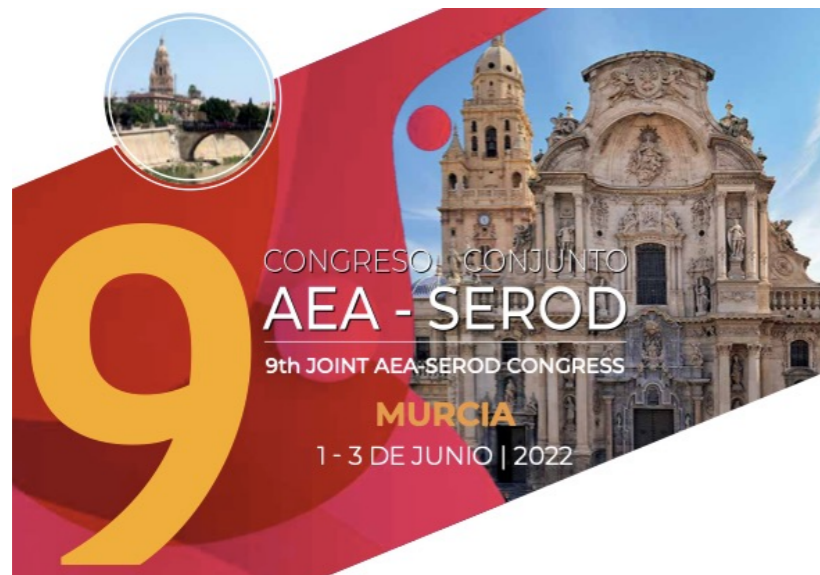

1\_junio\_2022



[www.aearthroscopia.com](http://www.aearthroscopia.com)



[www.serod.org](http://www.serod.org)

# Síndrome Doloroso del Trocánter Mayor (SDTM):

“operadas no van bien nunca”




INSTITUTO DEL APARATO LOCOMOTOR

Iñaki Mediavilla; MD, PhD

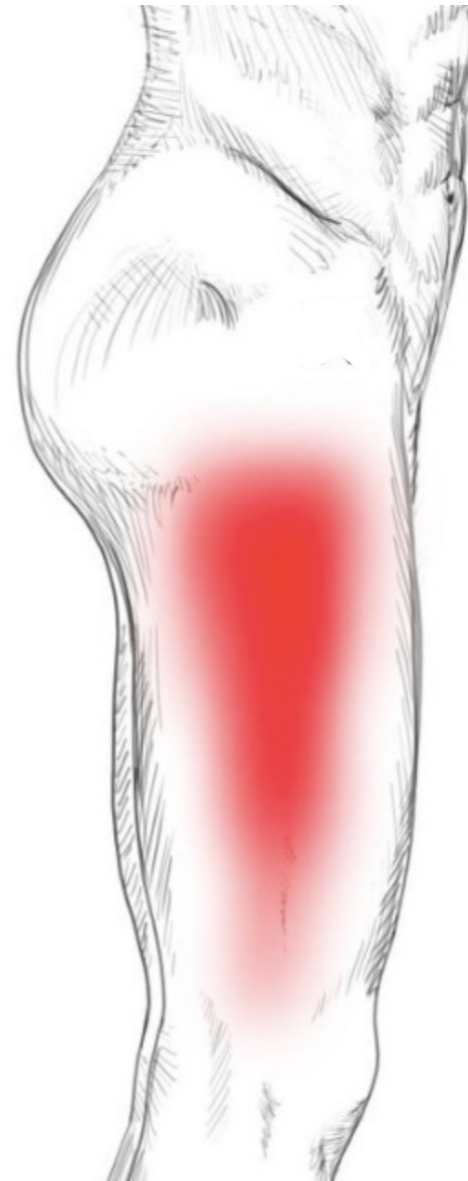


BASURTUKO OSPITALEA  
HOSPITAL DE BASURTO

no tengo conflicto de intereses



# Síndrome Doloroso del Trocánter Mayor (SDTM)

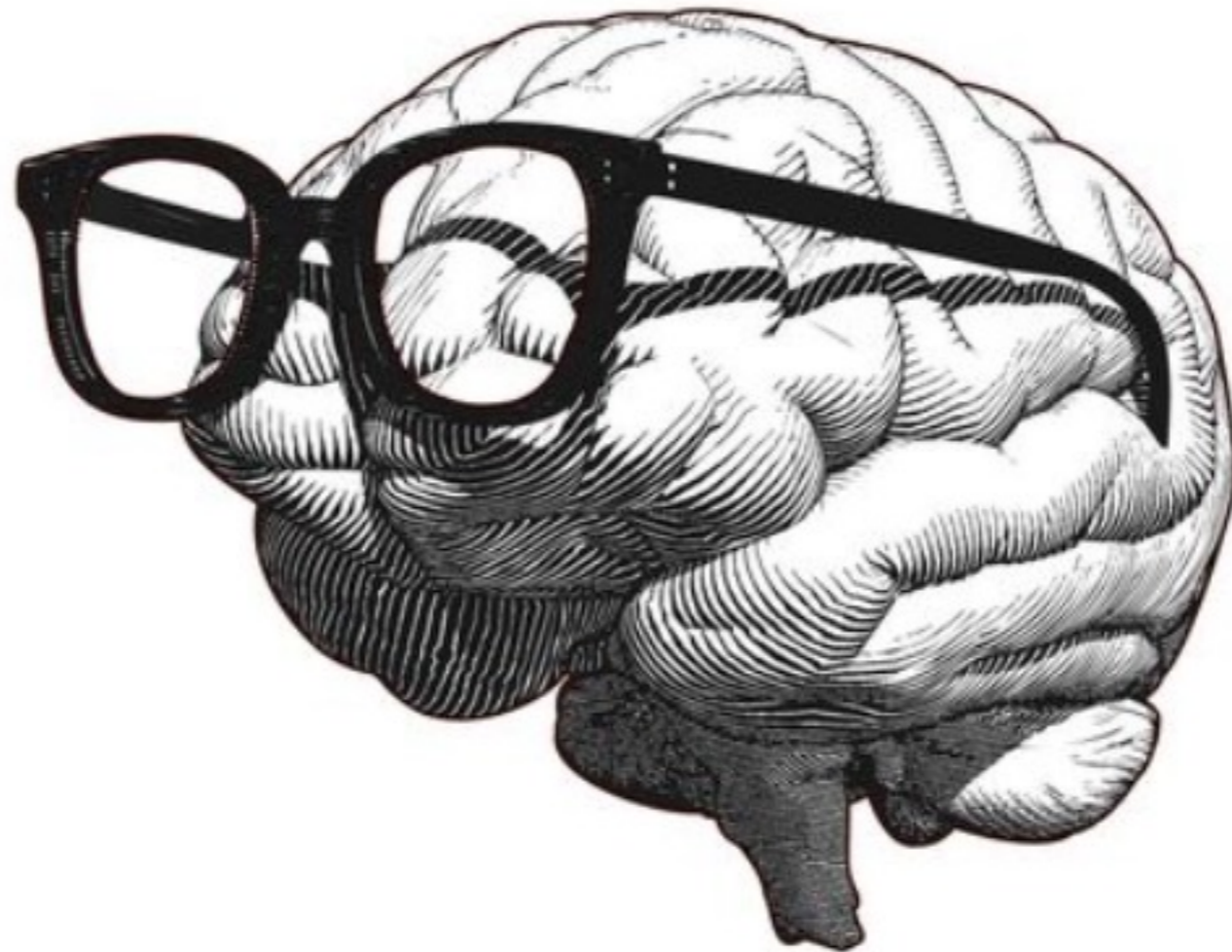

“operadas no van bien nunca”

## **COMENTARIO DE SHARPE**

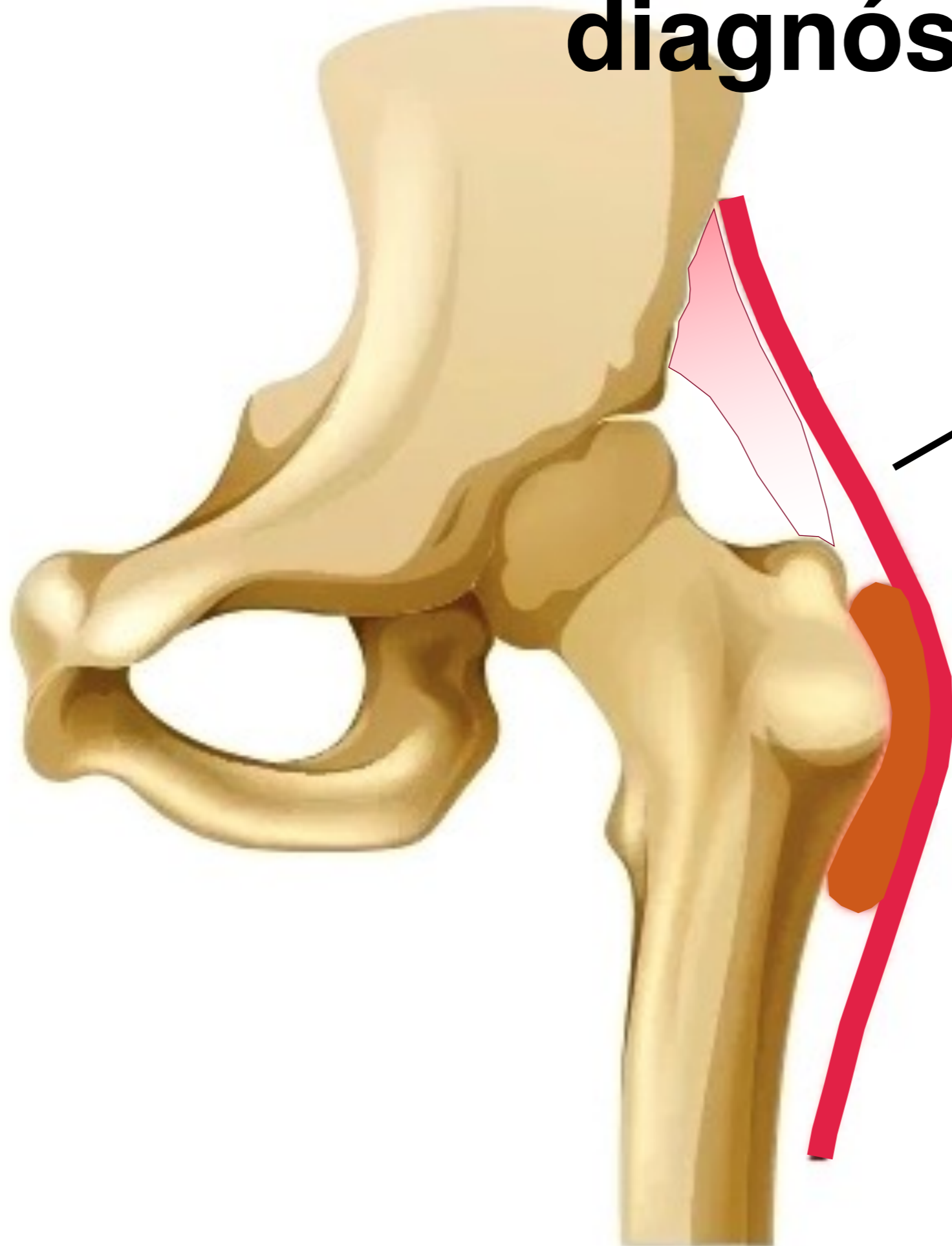
La dermatología es la única especialidad de la medicina en la que existen doscientas enfermedades y sólo tres tipos de crema para curarlas.

¡vamos a pensar un poquito!



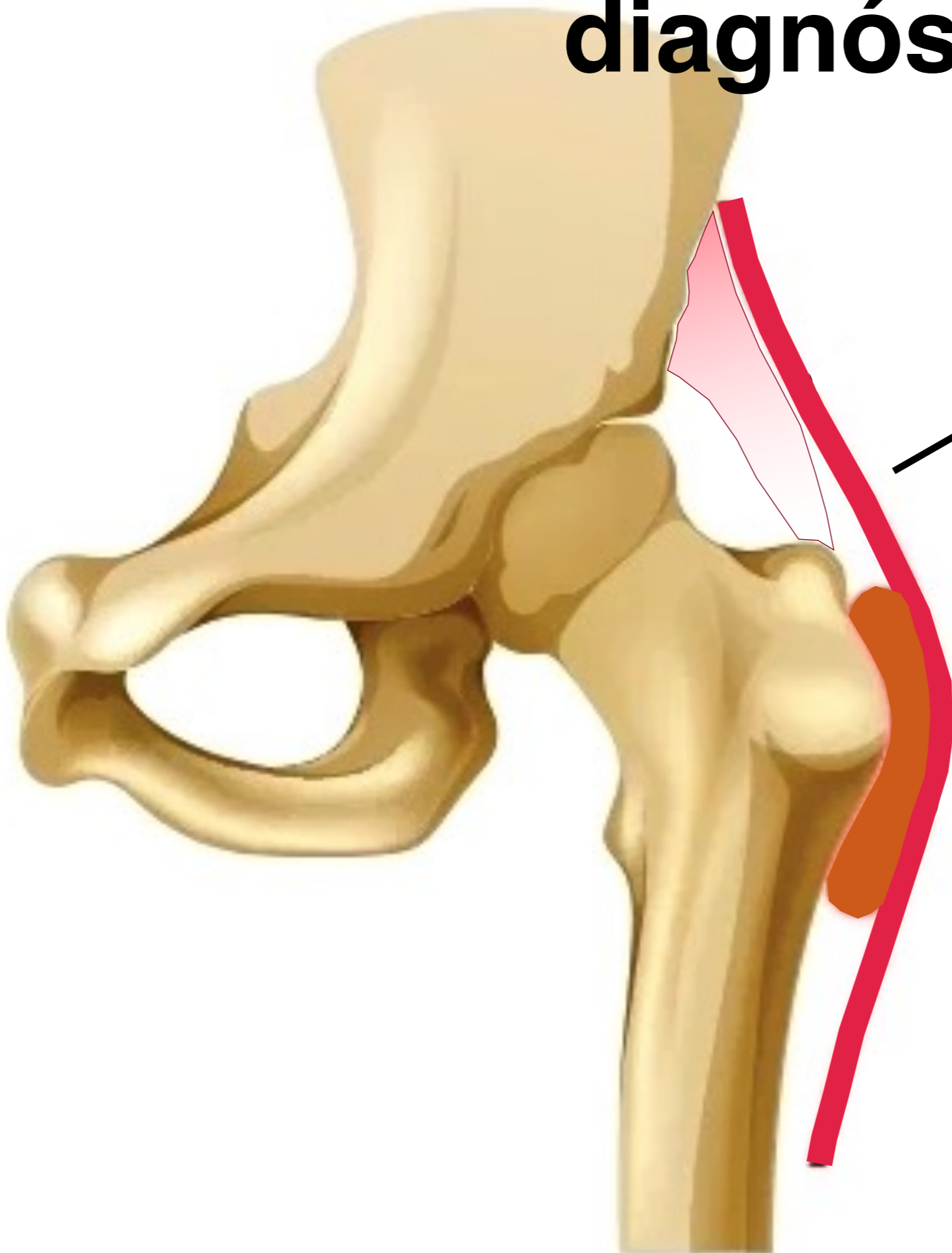
1 un poco de confusión diagnóstica

# diagnóstico

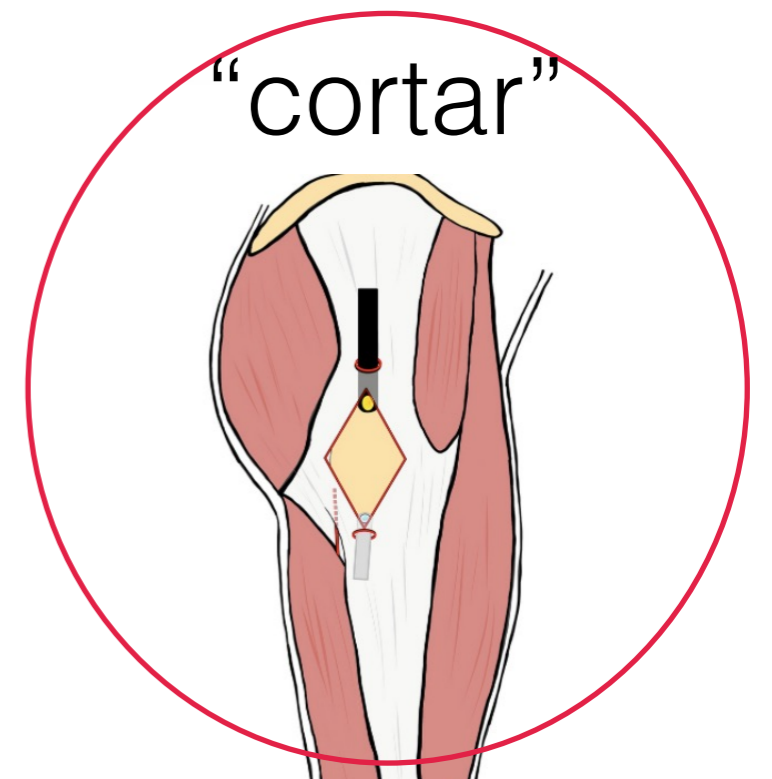


fascia lata

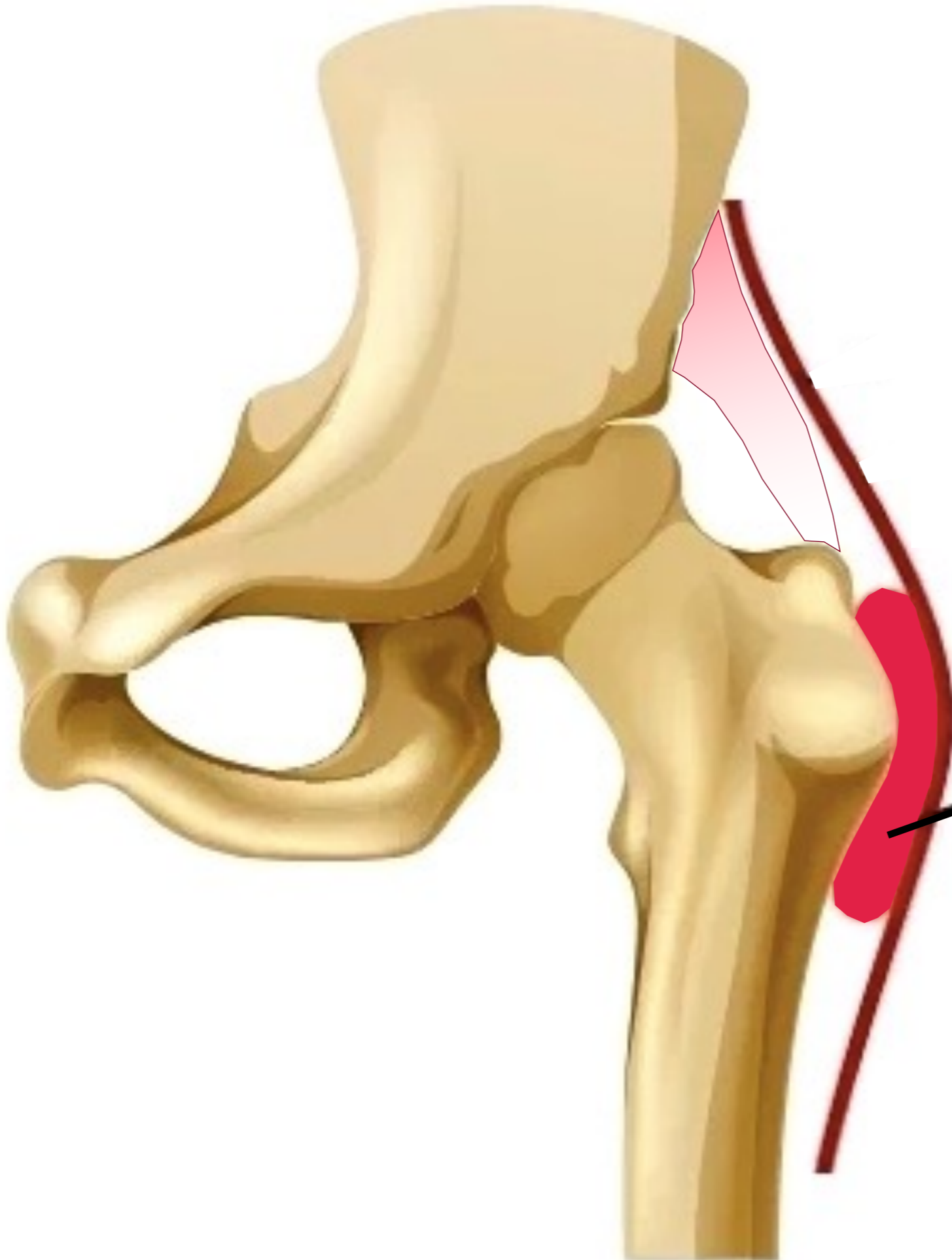
# diagnóstico



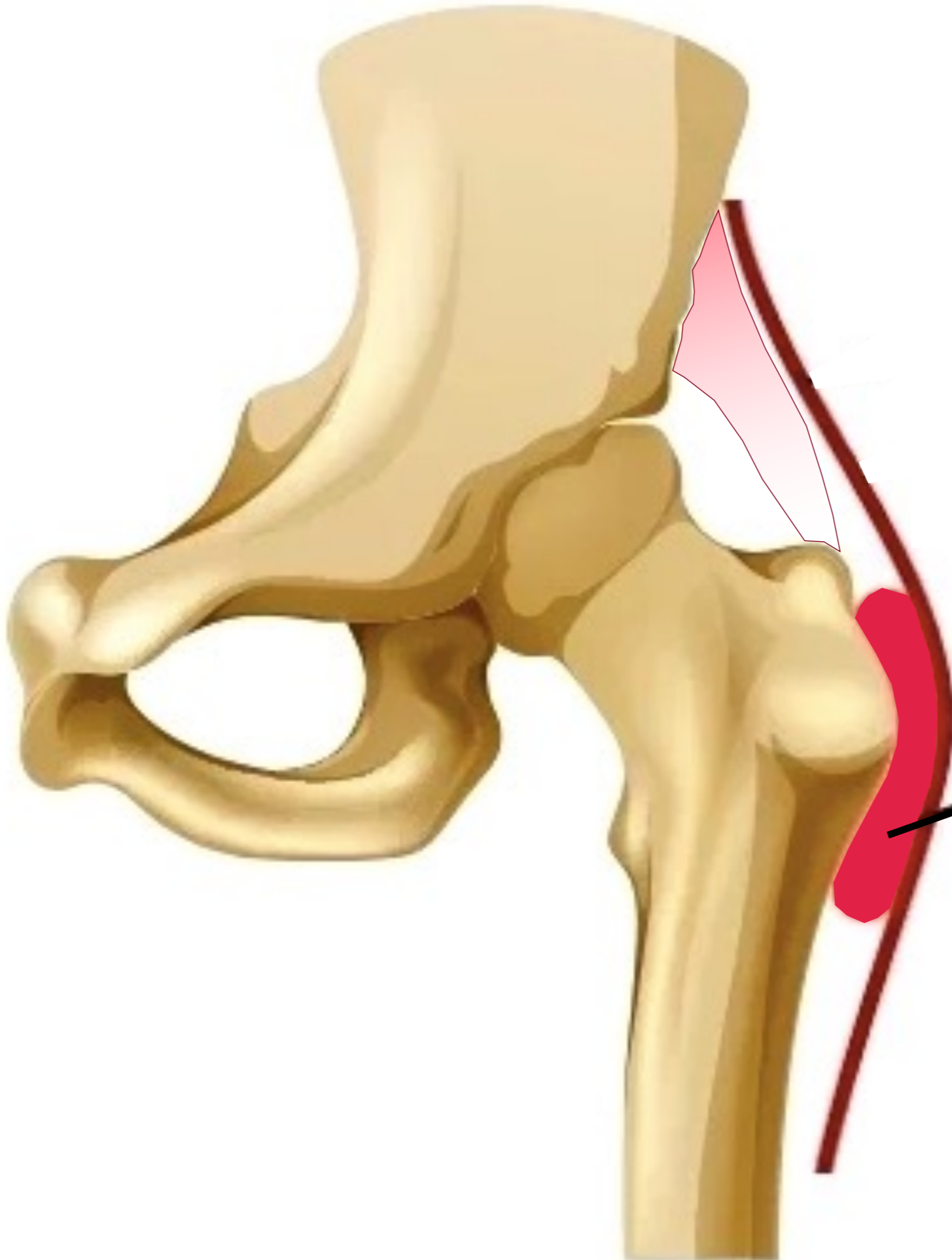
fascia lata





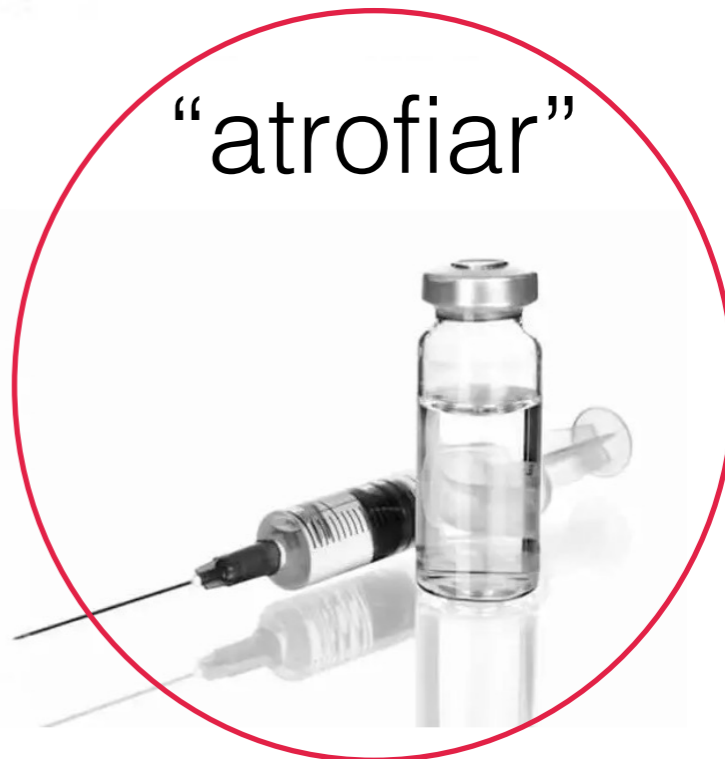

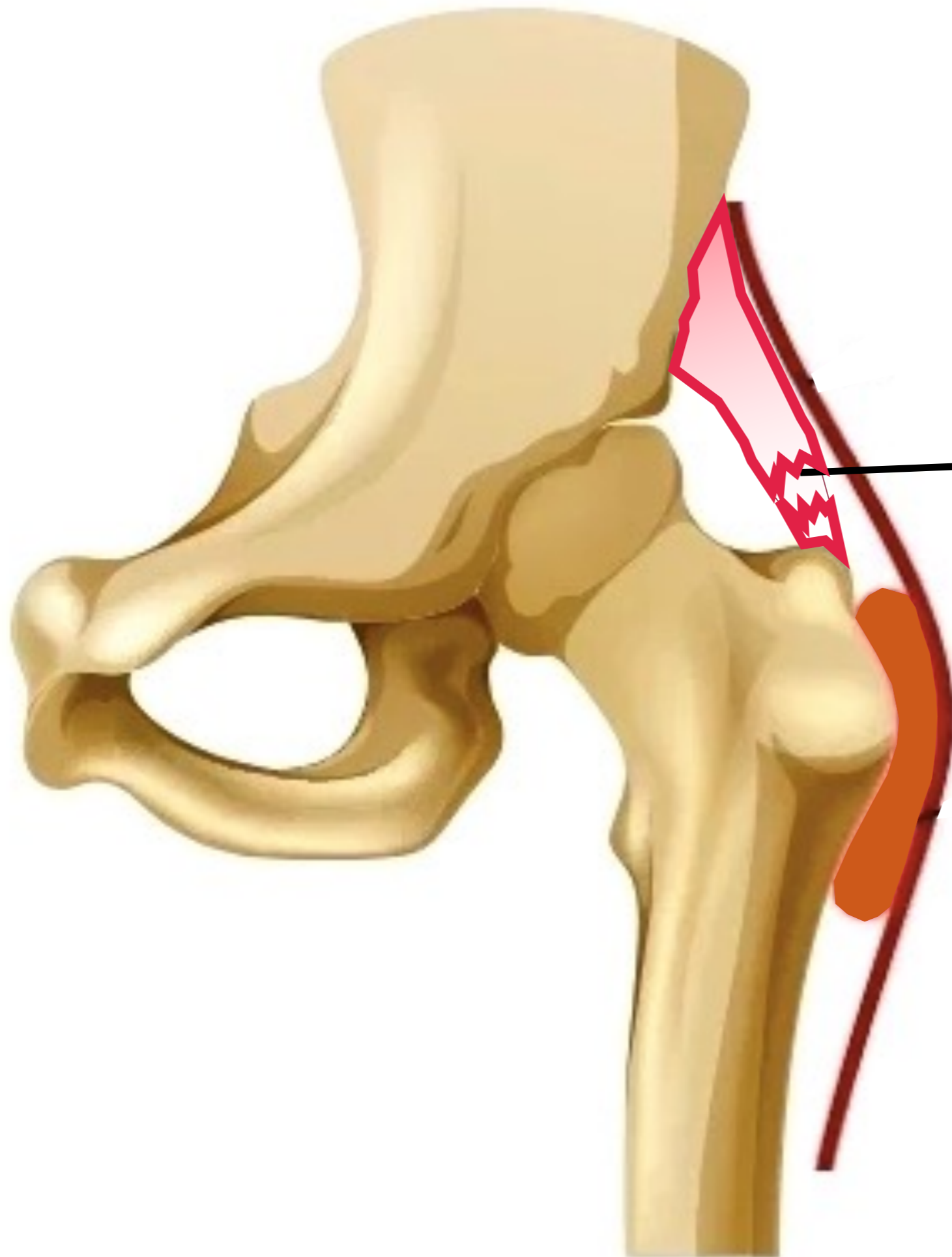
bursa



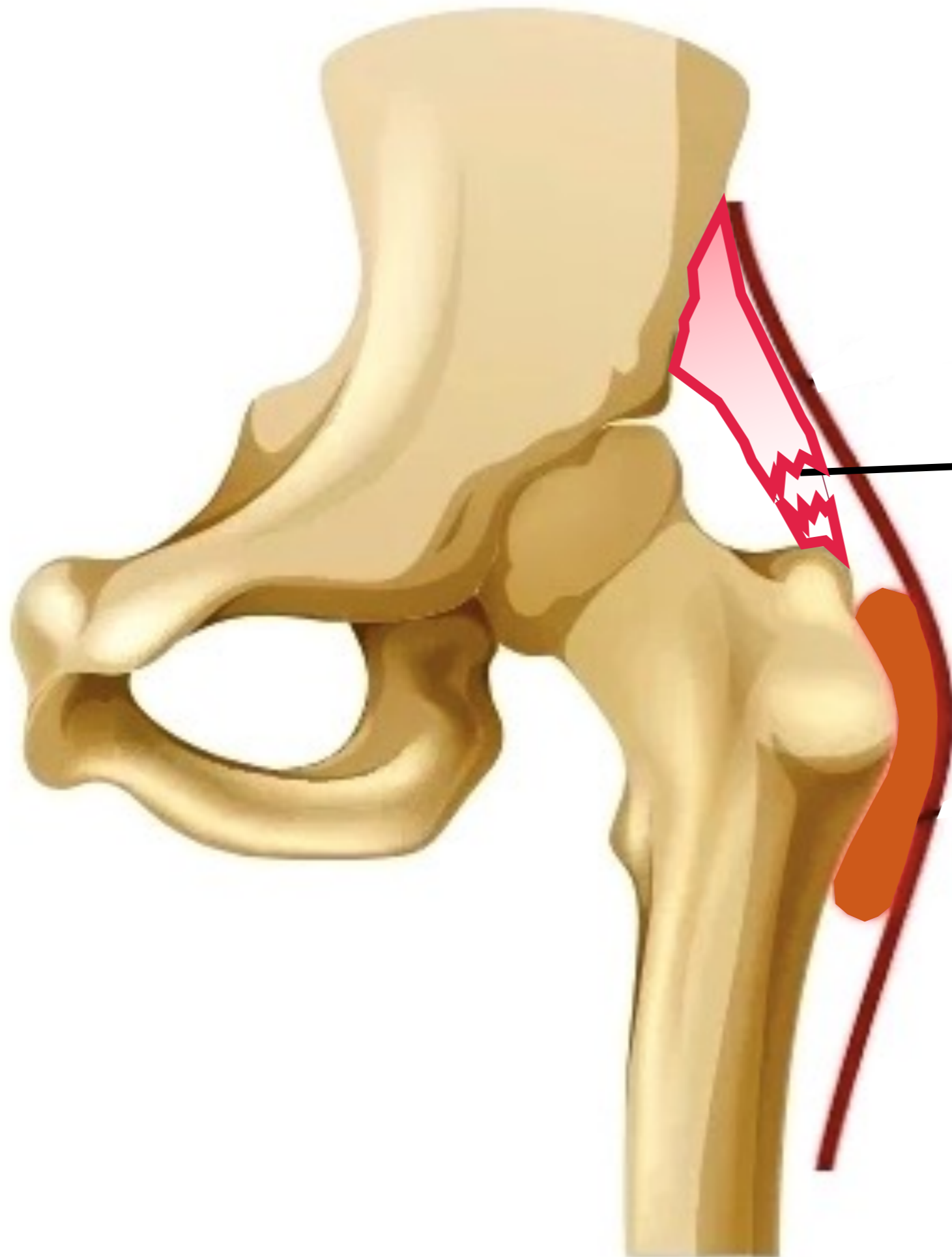
bursa

“atrofiar”

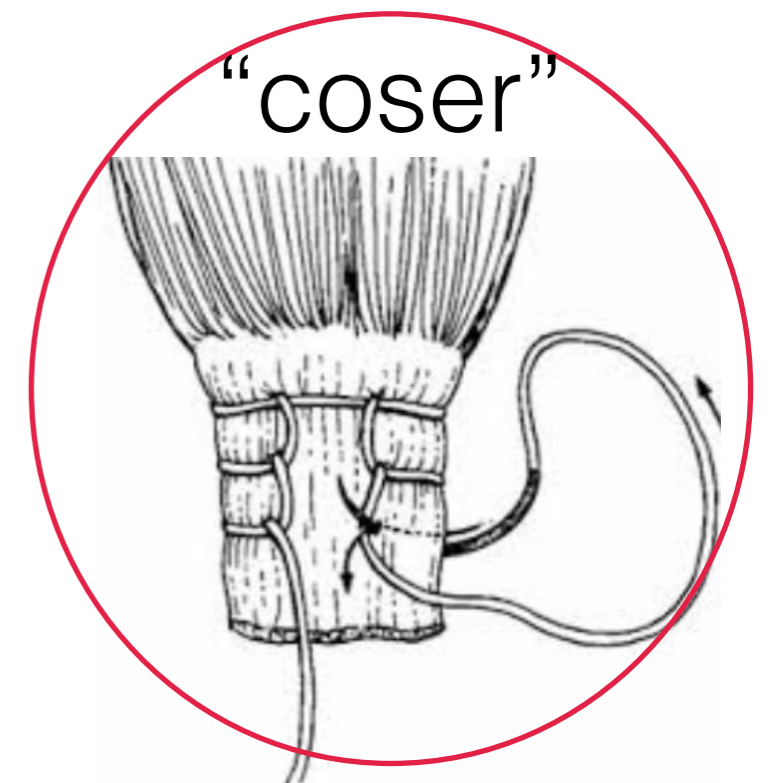




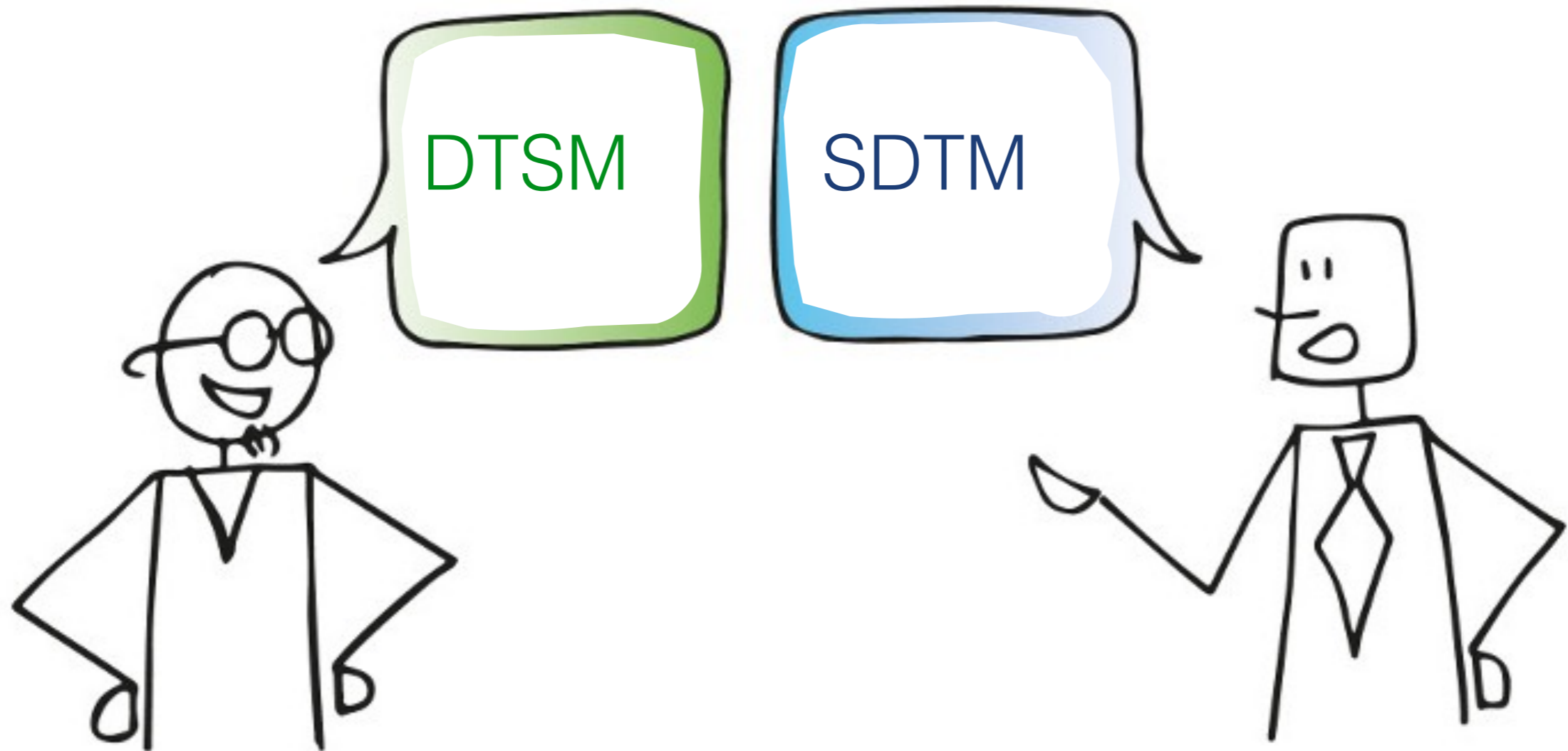
rotura de  
tendones glúteos



rotura de  
tendones glúteos



# Síndrome Doloroso del Trocánter Mayor (SDTM)



Marín-Pena O, Papavasiliou AV, Olivero M, Galanis N, Tey-Pons M, Khanduja V.

**Non-surgical treatment as the first step to manage peritrochanteric space disorders.**

Knee Surg Sports Traumatol Arthrosc. 2021 Aug;29(8):2417-2423.

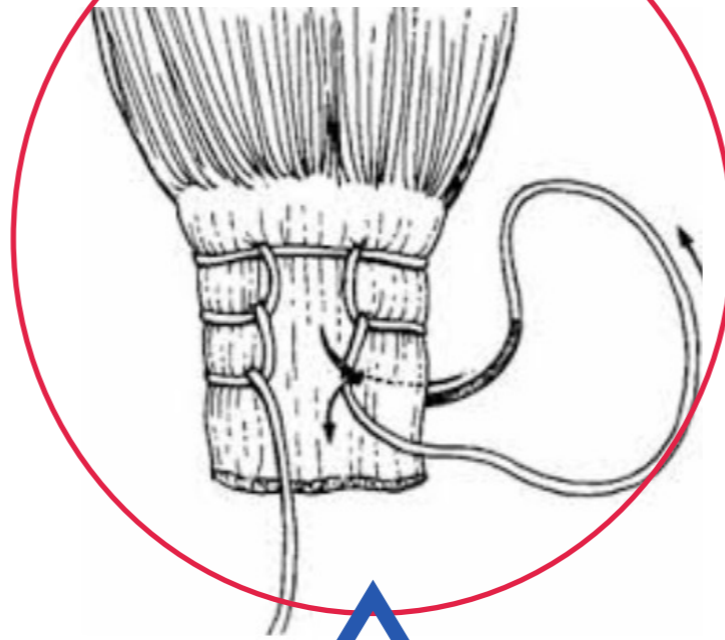
“un tratamiento eficaz depende de un diagnóstico preciso”

Barratt PA, Brookes N, Newson A.

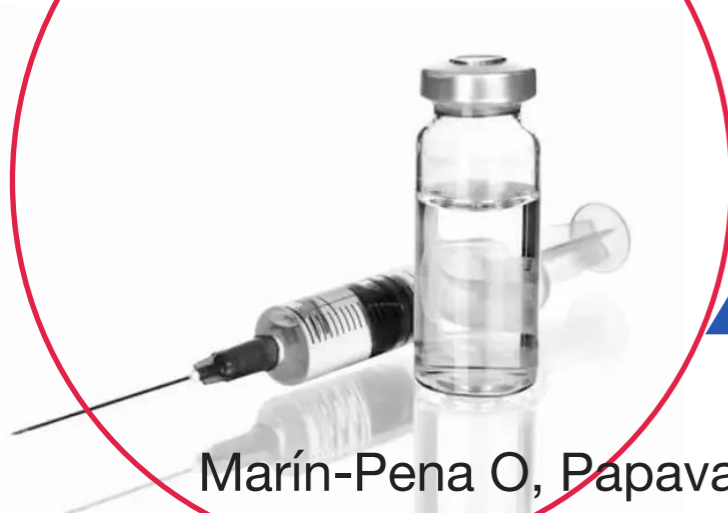**Conservative treatments for greater trochanteric pain syndrome: a systematic review.**

Br J Sports Med. 2017 Jan;51(2):97-104.

“coser”



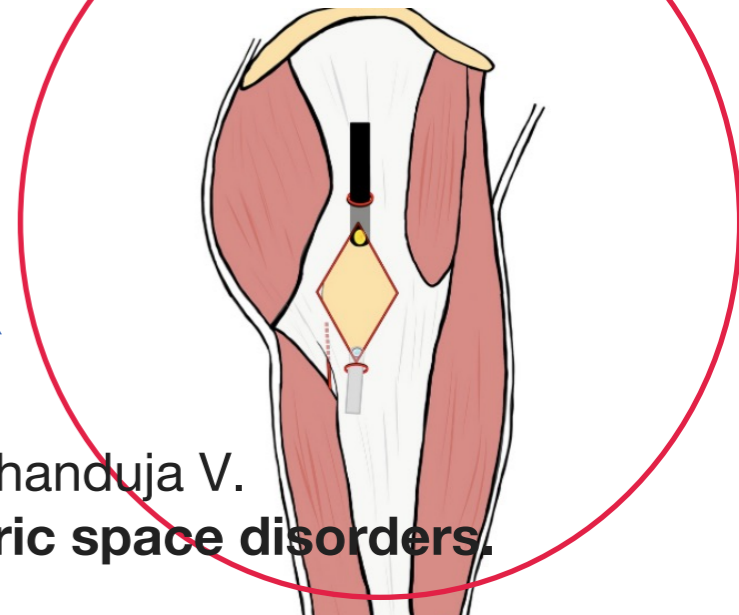
“atrofiar”



**SDTM**

**tratamiento**

“cortar”

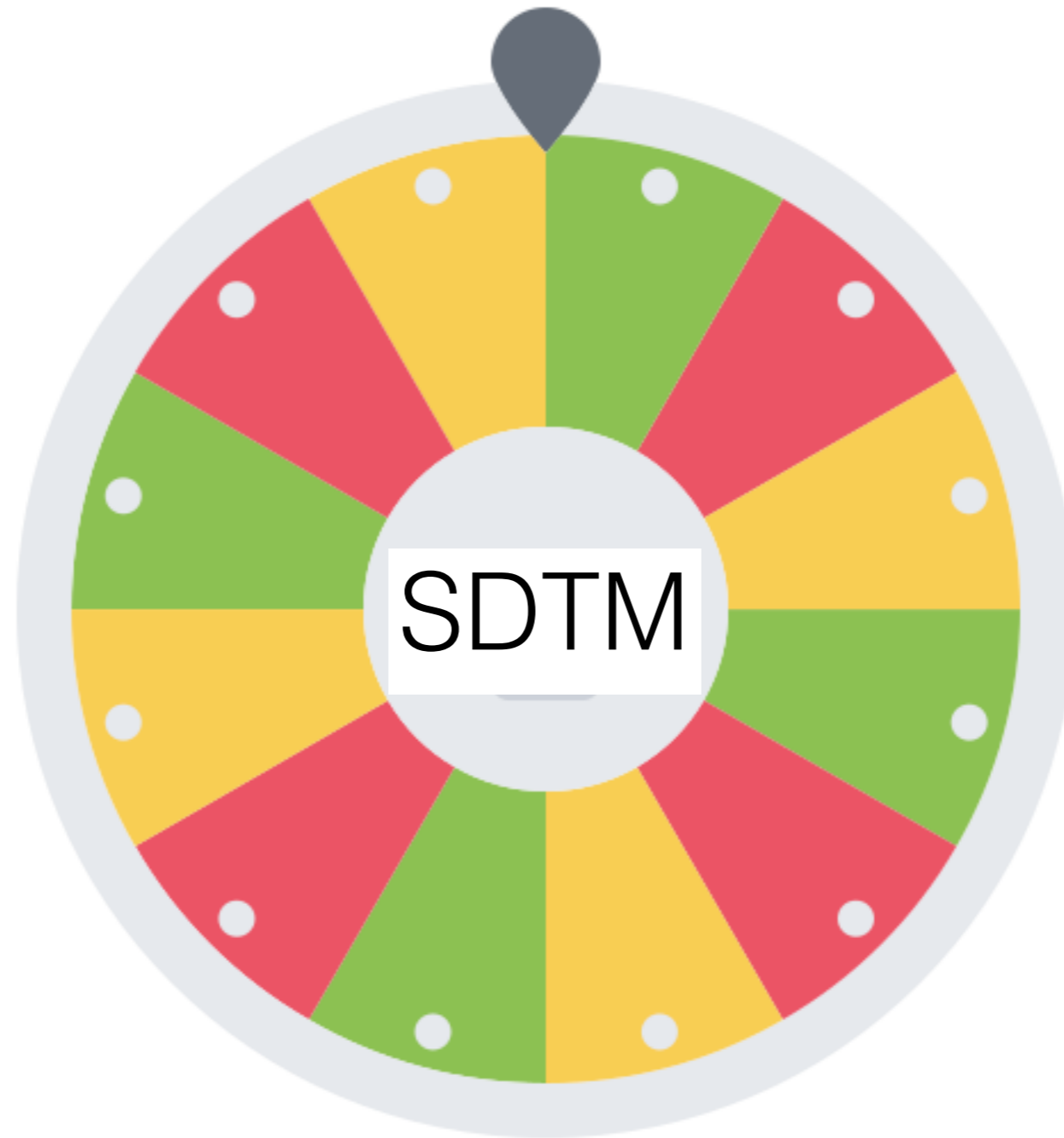


Marín-Pena O, Papavasiliou AV, Olivero M, Galanis N, Tey-Pons M, Khanduja V.

**Non-surgical treatment as the first step to manage peritrochanteric space disorders.**

Knee Surg Sports Traumatol Arthrosc. 2021 Aug;29(8):2417-2423.

# ¿los combinamos bien?



“atrofiar”



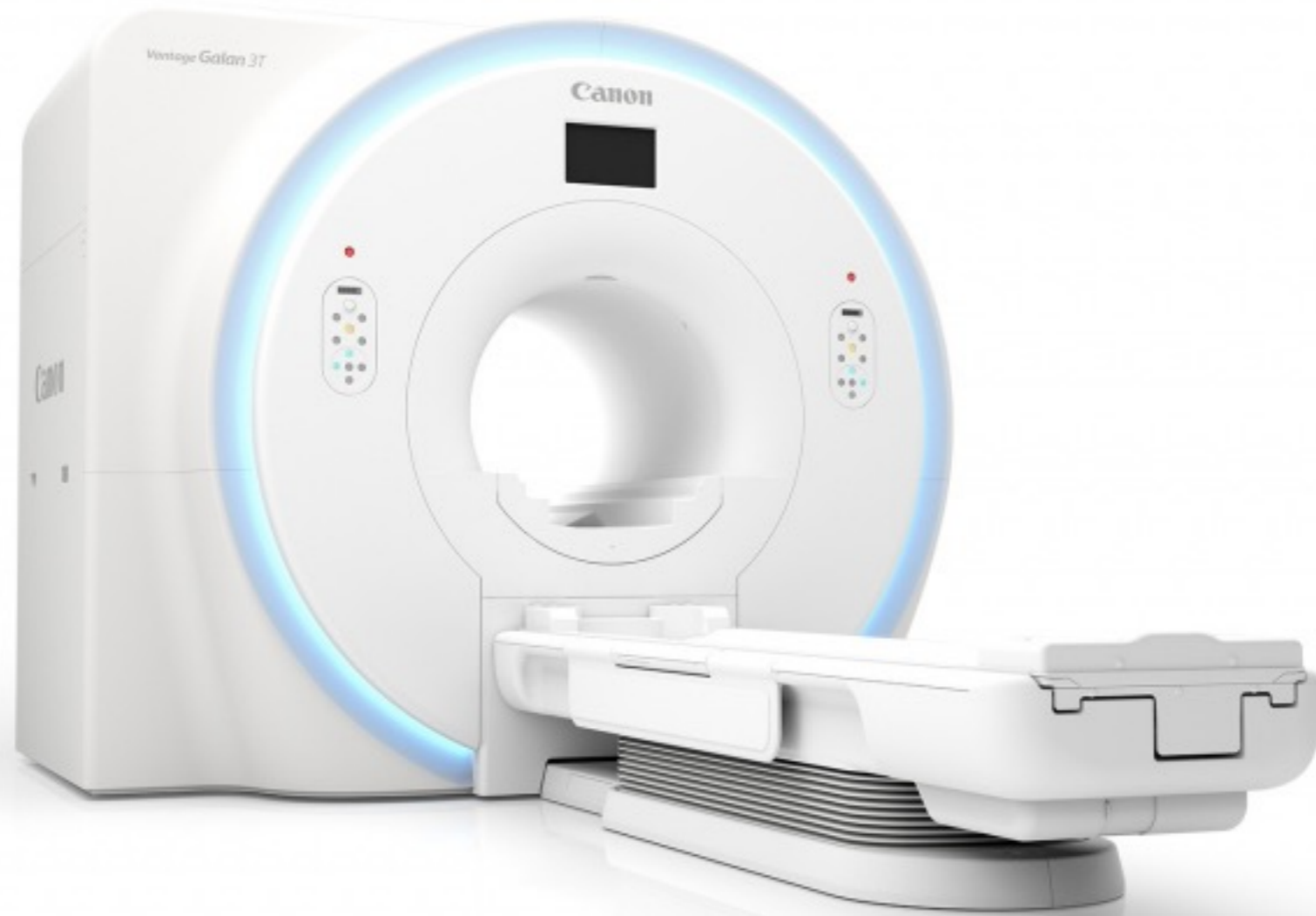“coser”

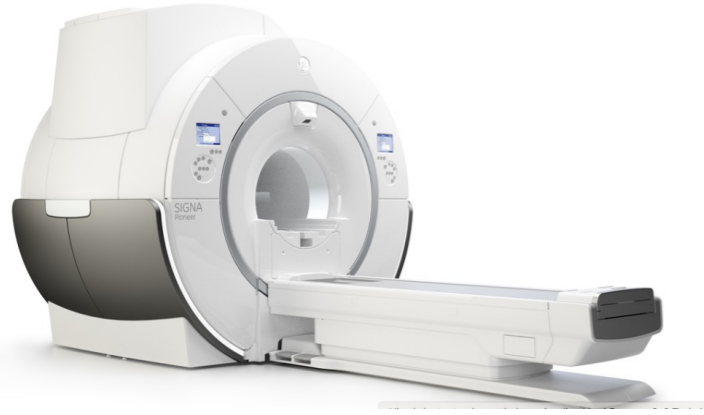

“cortar”



2 un poco de limitaciones diagnósticas





las alteraciones de señal en los tendones glúteos  
son prevalentes en asintomáticos

De Grove V, Buls N, Vandenbroucke F, Shahabpour M, et al..  
**MR of tendons about the hip: A study in asymptomatic volunteers.**  
Eur J Radiol. 2021 Oct;143:109876.



la RM tiende a **subestimar** la presencia  
de patología tendinosa

De Grove V, Buls N, Vandenbroucke F, Shahabpour M, et al..  
**MR of tendons about the hip: A study in asymptomatic volunteers.**  
Eur J Radiol. 2021 Oct;143:109876.

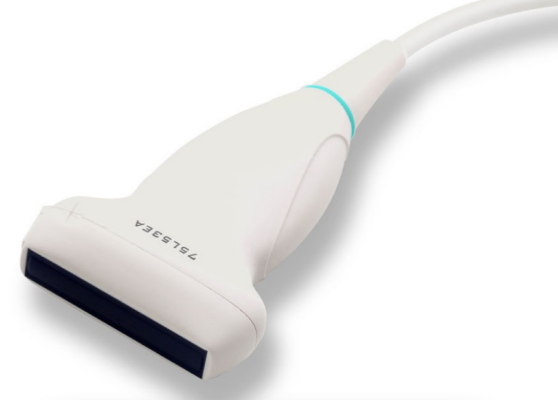

“specific radiological diagnoses like partial/full-thickness tears, were detected by **3.0-T MRI than by 1.5 T** ( $p = 0.019$ )”

Oehler N, Ruby JK, Strahl A, Maas R, Ruether W, Niemeier A.  
**Hip abductor tendon pathology visualized by 1.5 versus 3.0 Tesla MRIs.**  
Arch Orthop Trauma Surg. 2020 Feb;140(2):145-153.



75L53EA

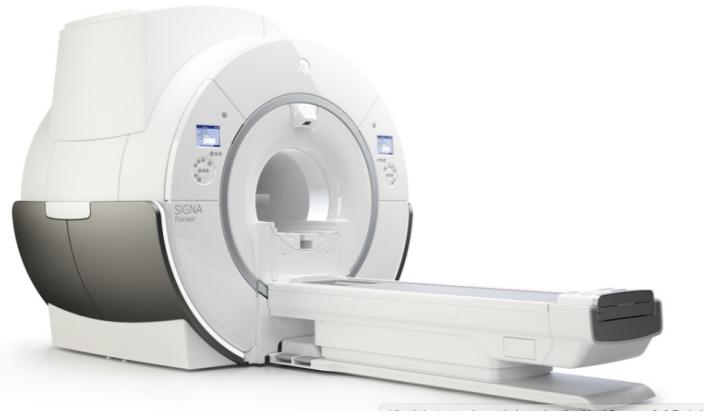


la Eco tiende a **sobre-diagnosticar** la presencia  
de patología tendinosa

Cormick W, Smith P, Fearon A.

**Identification and differentiation of gluteus medius tendon pathology using ultrasound and magnetic resonance imaging. Musculoskelet**

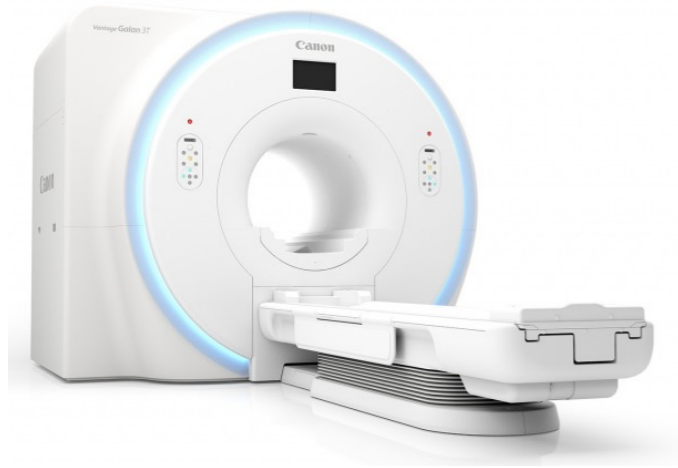Sci Pract. 2019 Jun;41:1-5.



“Overdiagnosis is definitely a risk”

De Grove V, Buls N, Vandenbroucke F, Shahabpour M, et al..  
**MR of tendons about the hip: A study in asymptomatic volunteers.**  
Eur J Radiol. 2021 Oct;143:109876.





las dos modalidades de imagen pueden **desviar** el tratamiento

Cormick W, Smith P, Fearon A.

**Identification and differentiation of gluteus medius tendon pathology using ultrasound and magnetic resonance imaging. Musculoskelet**

Sci Pract. 2019 Jun;41:1-5.

3 un poco de negacionismo

## **Conservative treatment:**

- NSAIDs
- analgesics
- physiotherapy
- home training,
- local **corticosteroid** injection
- shock wave therapy

Marín-Pena O, Papavasiliou AV, Olivero M, Galanis N, Tey-Pons M, Khanduja V.

**Non-surgical treatment as the first step to manage peritrochanteric space disorders.**

Knee Surg Sports Traumatol Arthrosc. 2021 Aug;29(8):2417-2423.

# Conservative treatment:



**corticosteroid** injection



Marín-Pena O, Papavasiliou AV, Olivero M, Galanis N, Teyhenlovas M, Khanduja V.

**Non-surgical treatment as the first step to manage peritrochanteric space disorders.**

Knee Surg Sports Traumatol Arthrosc. 2021 Aug;29(8):2417-2423.

كورونا كذبة

EL COVID ES MENTIRA

EL PRP ES MENTIRA

Handwritten graffiti in Arabic script above the text.



Abat F, Alfredson H, Cucchiarini M et al.

**Current trends in tendinopathy: consensus of the ESSKA basic science committee.**

**Part II: treatment options.**

J Exp Orthop. 2018 Sep 24;5(1):38.

## CONCLUSIONES:

1- No sabemos la evolución natural de las lesiones tendinosas de los tendones glúteos

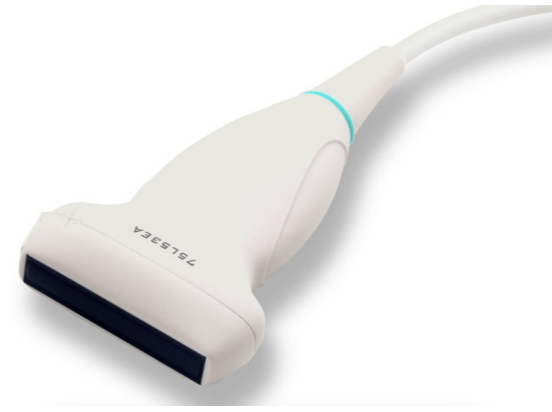
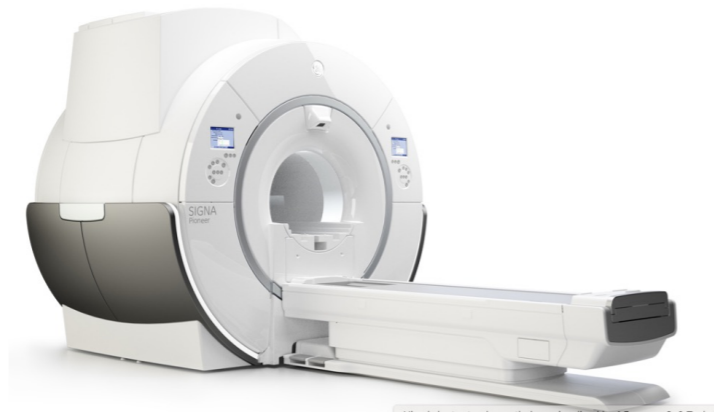




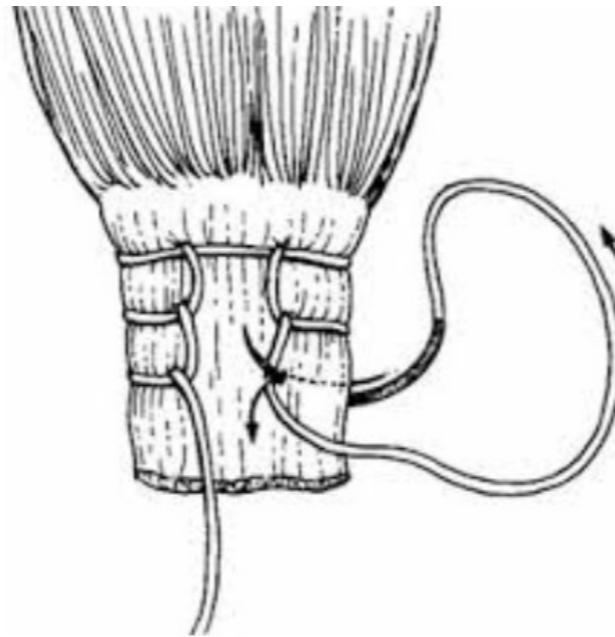
## CONCLUSIONES:

3- que además las sobre diagnosticamos



## CONCLUSIONES:

4- ¿Primero lo atrofiamos y más tarde queremos suturarlo?

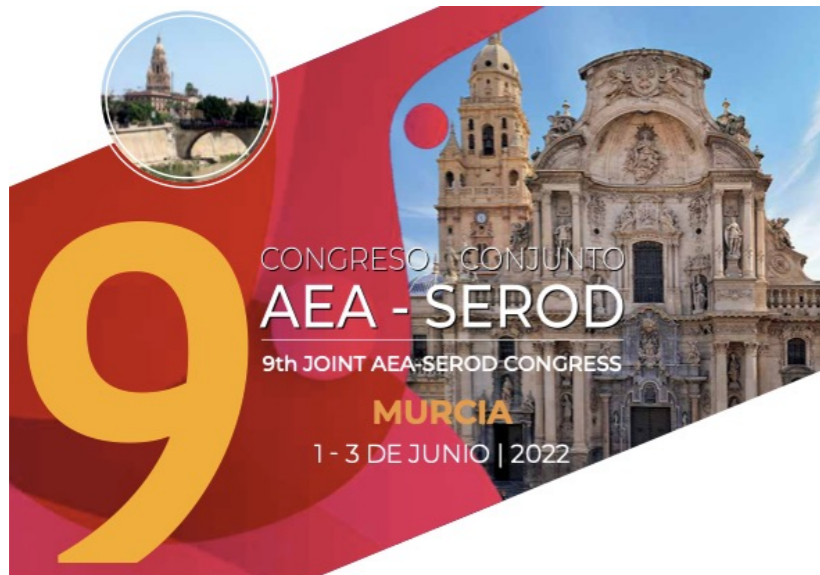





Ahora vas tú....y lo operas...!

1\_junio\_2022




[www.aearthroscopia.com](http://www.aearthroscopia.com)



[www.serod.org](http://www.serod.org)

gracias



**BASURTUKO OSPITALEA**  
HOSPITAL DE BASURTO



INSTITUTO DEL APARATO LOCOMOTOR