

# 4



# AEA

aniversario  
**1982-2022**

J. Vilá y Rico MD. PhD



Hospital Universitario  
12 de Octubre



medartis®

**DePuy Synthes**  
**Institute** LLC  
advancing education and research

**Arthrex**®

 **smith&nephew**  
Professional Education

 **ZIMMER BIOMET**  
Institute

Search

[Advanced](#) [Create alert](#) [Create RSS](#)

[User Guide](#)

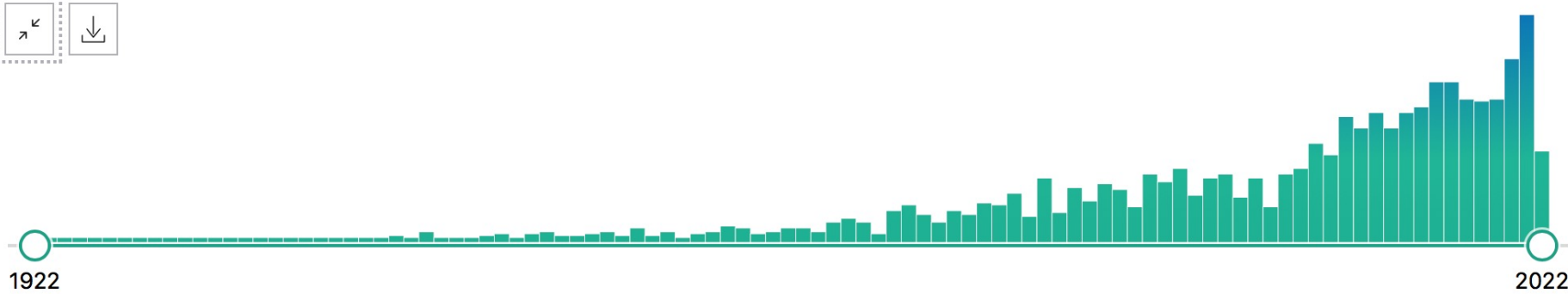
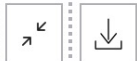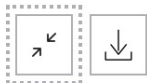
Save Email Send to

Sorted by: Best match Display options ⚙️

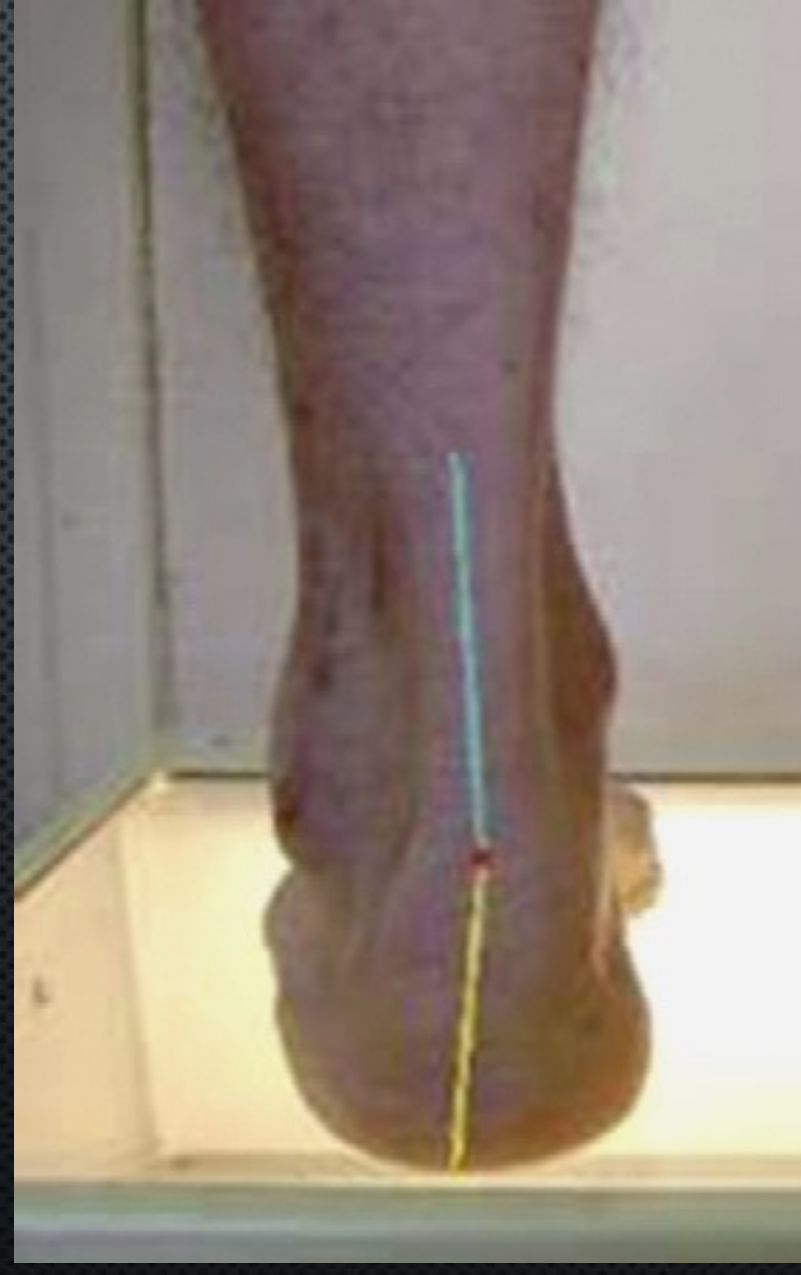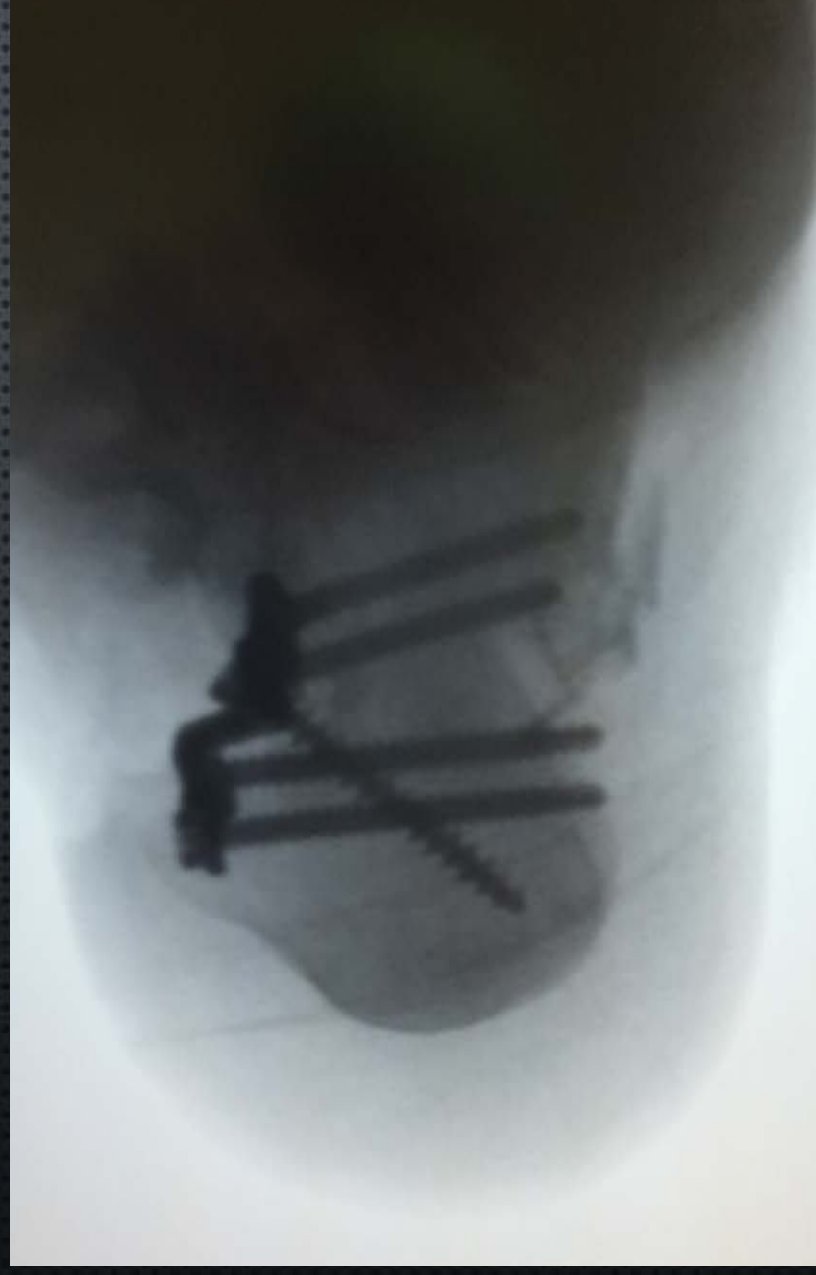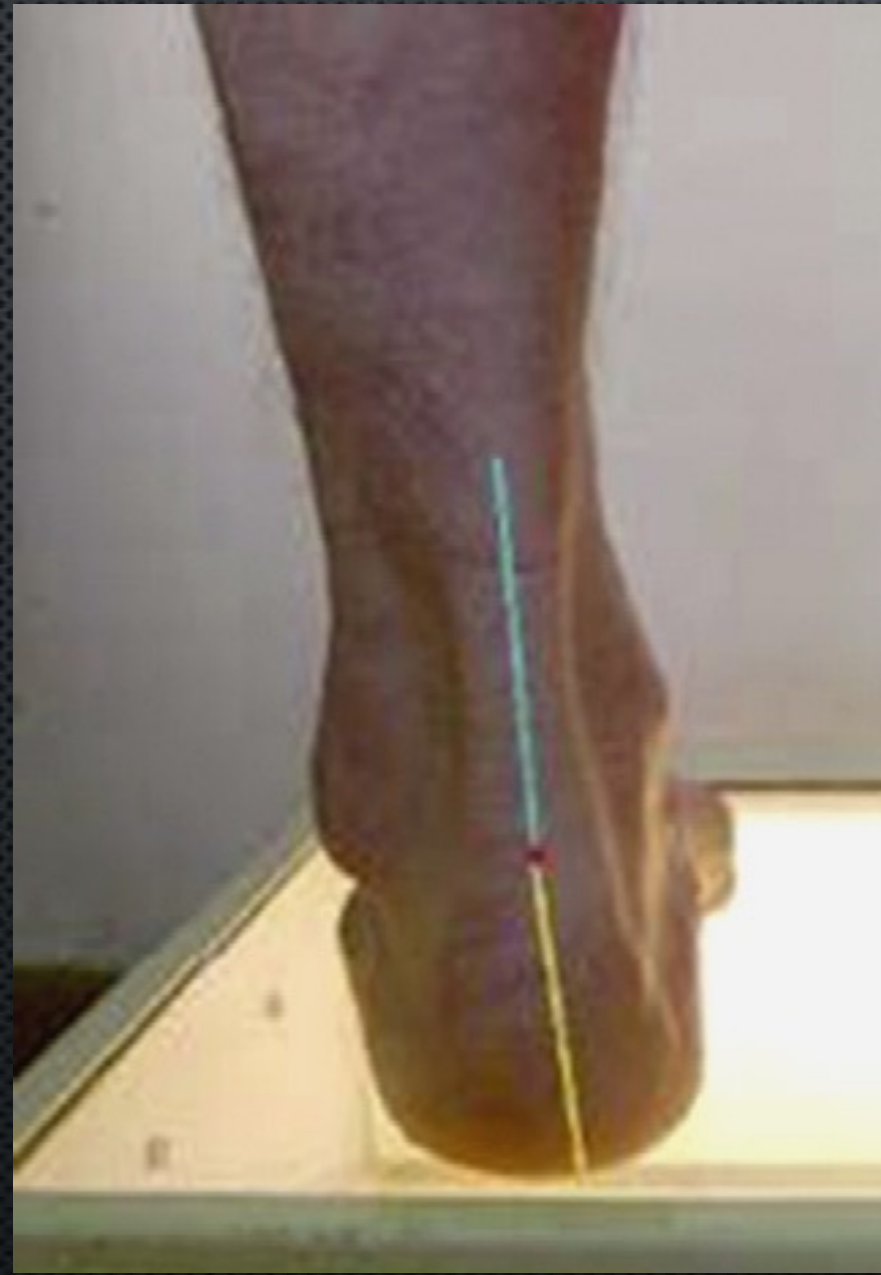RESULTS BY YEAR

1,619 results

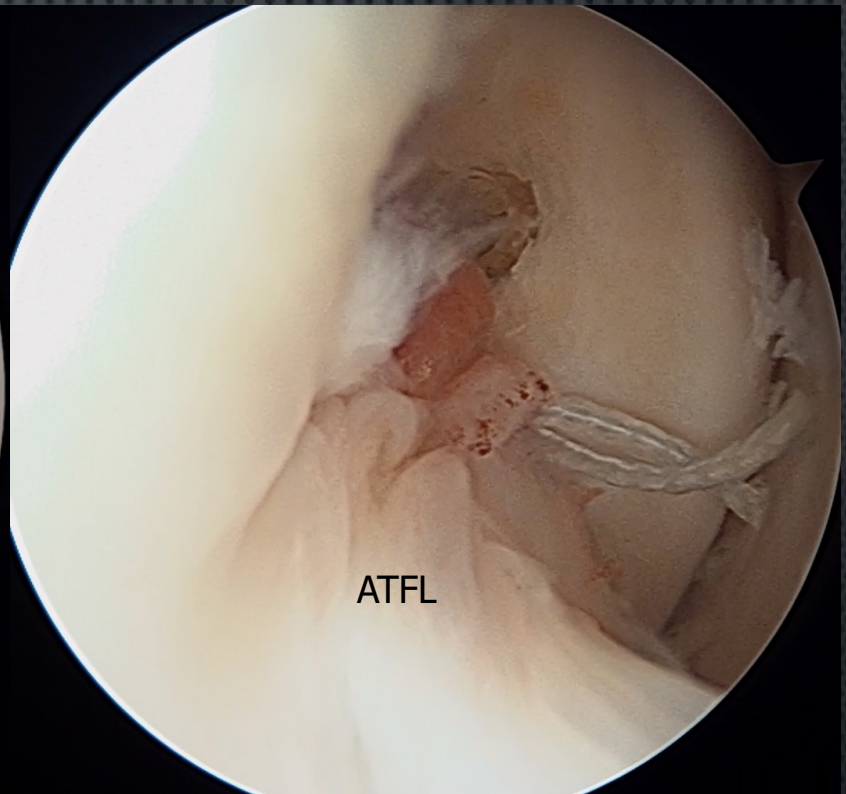
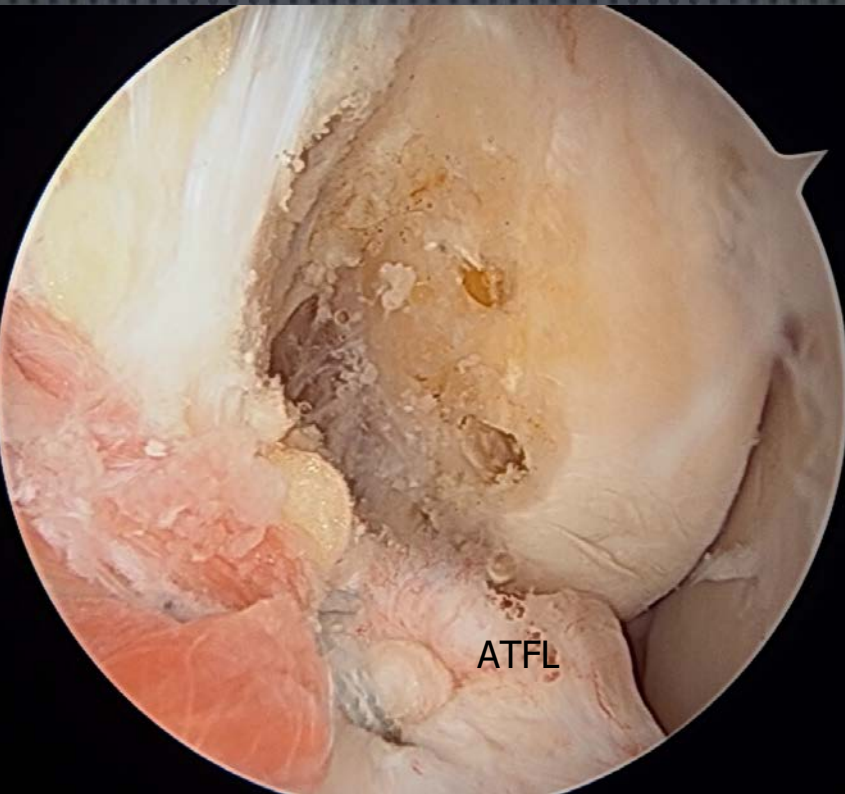
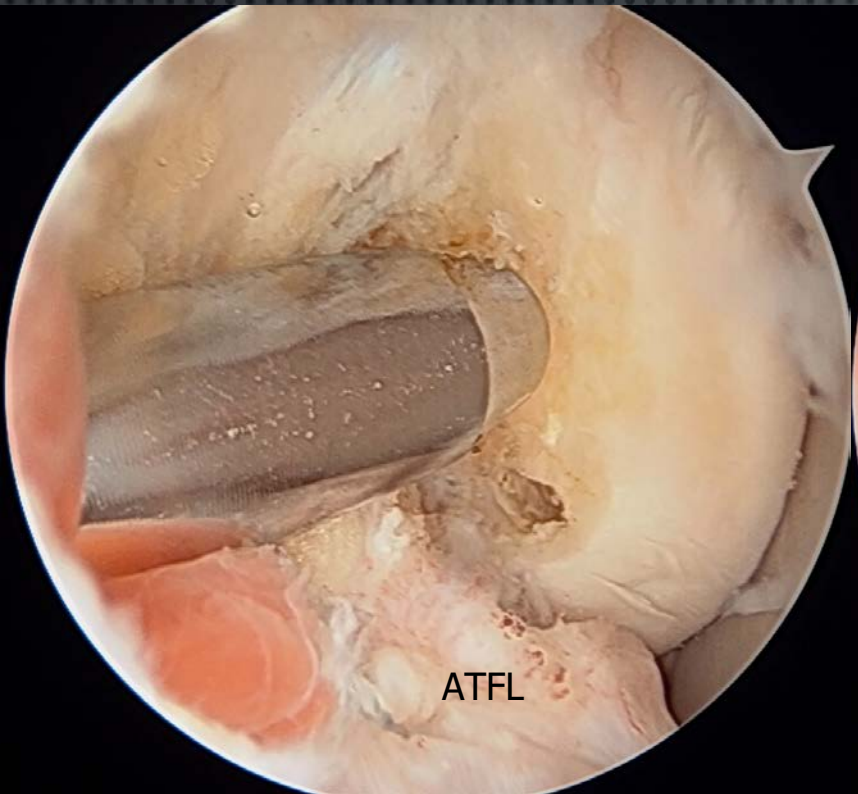
Page 1 of 162



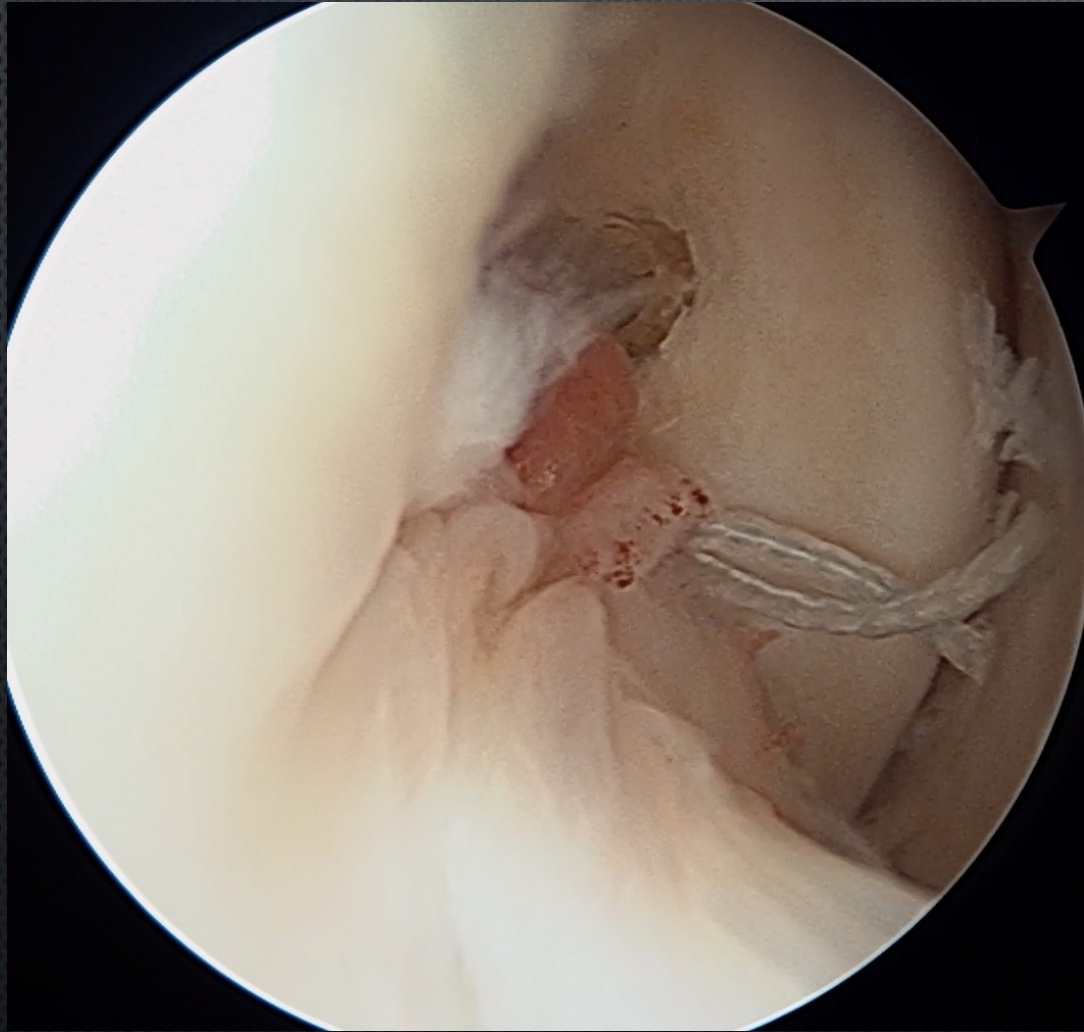
*Varus hindfoot deformity*



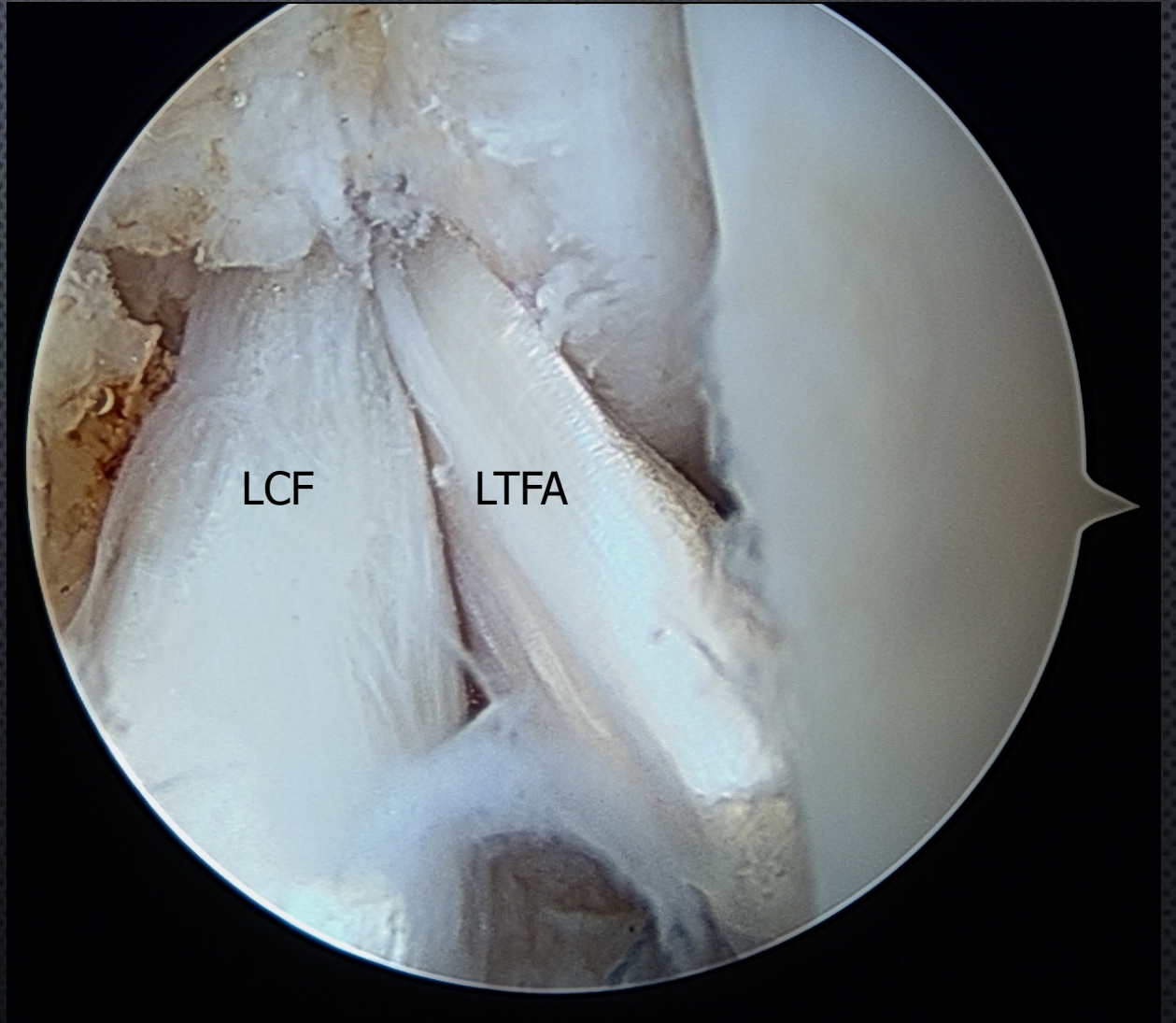
# *Anatomical Direct Repair*



*Anatomical Direct Repair*



*Anatomical Reconstruction  
ATFL + CFL*



Why?

How?

When?

Accessibility

Minimally invasive surgery

Diagnostic and therapeutic tool

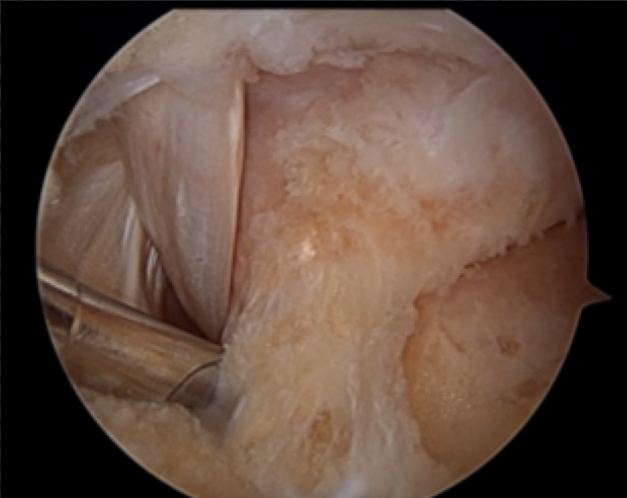
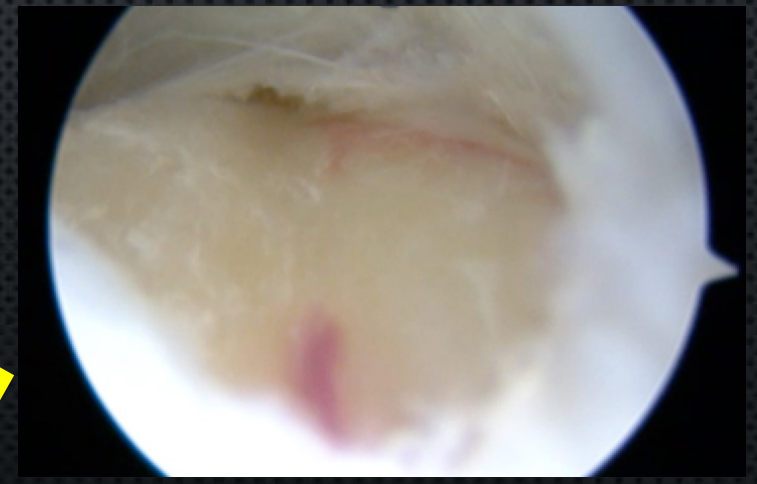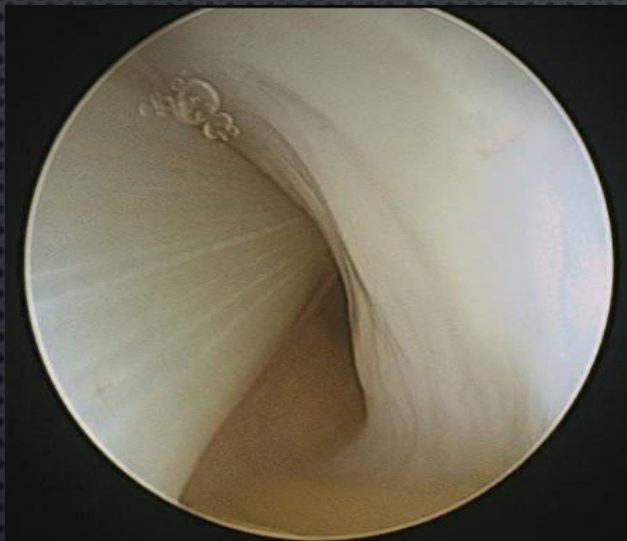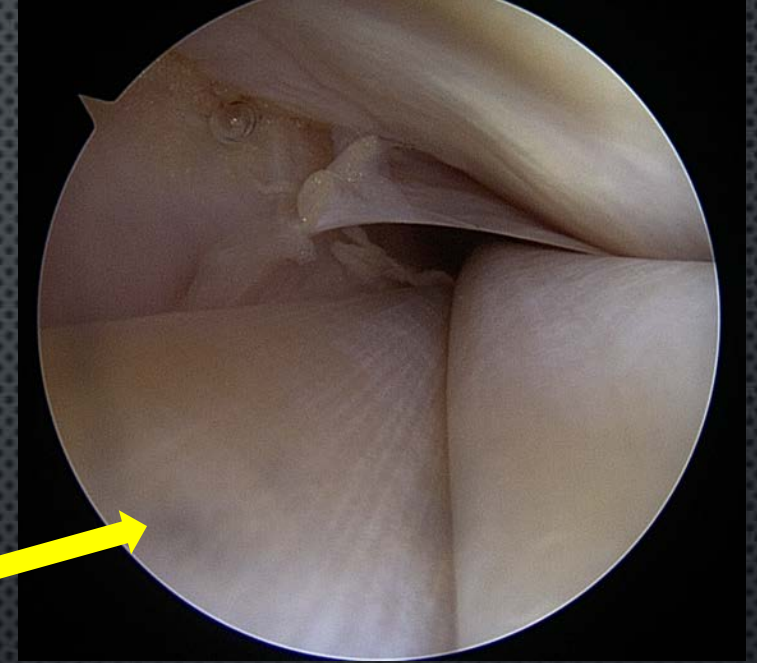
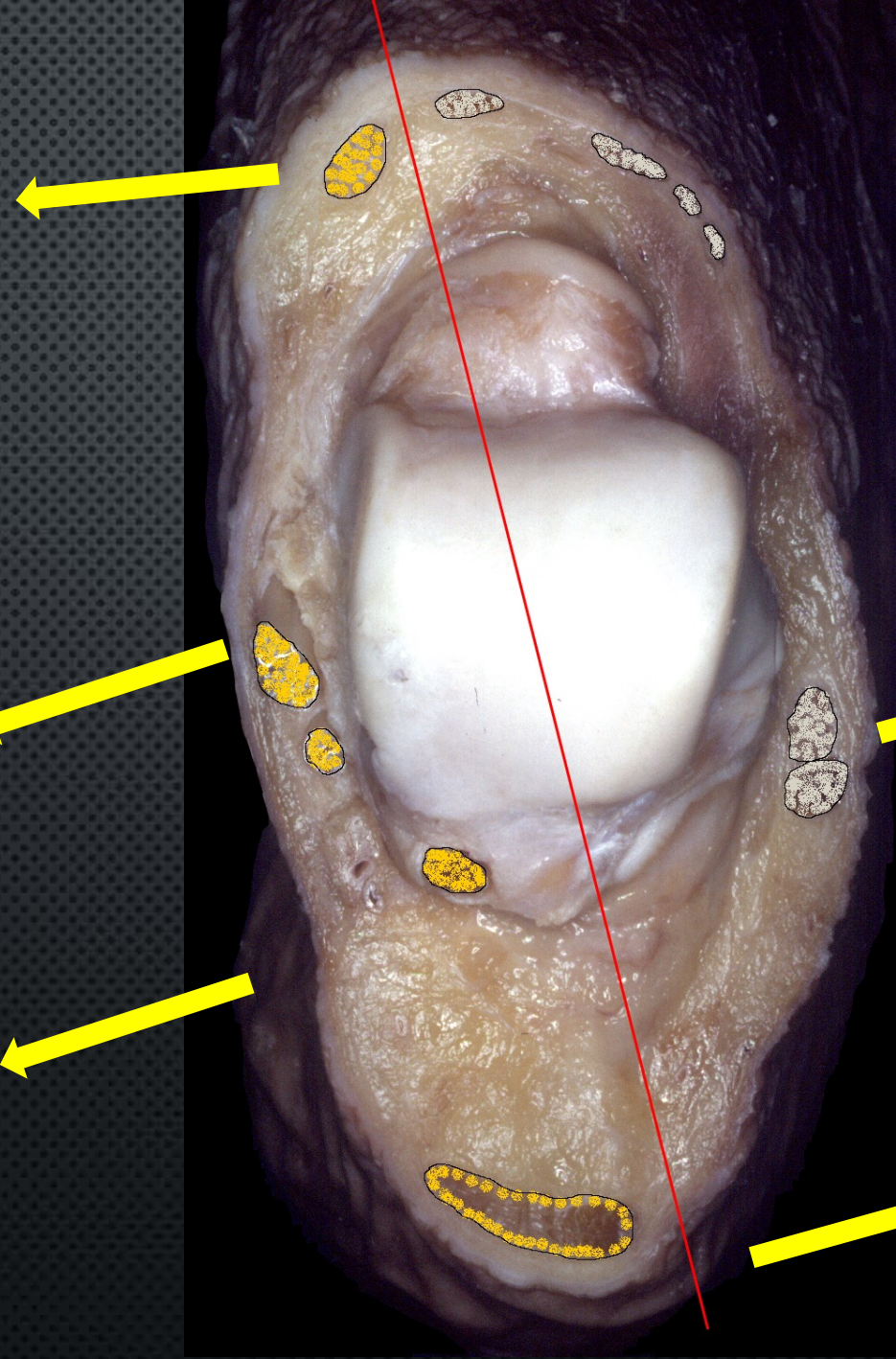
Dynamic evaluation

Less soft tissue damage and neurological injuries

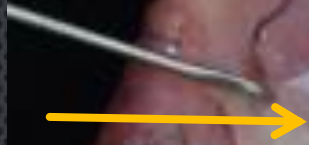Evaluation of associated injuries



*Why?*



A



B



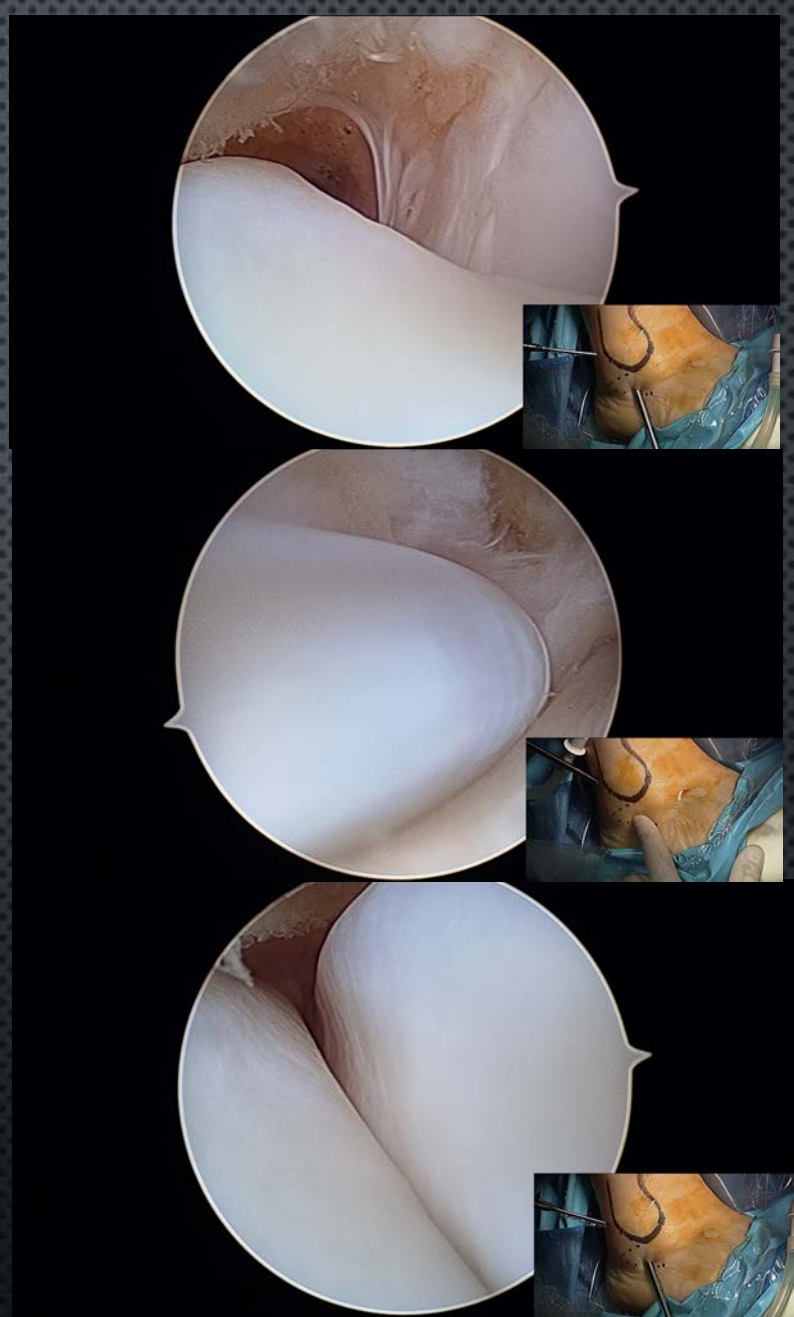
C



D

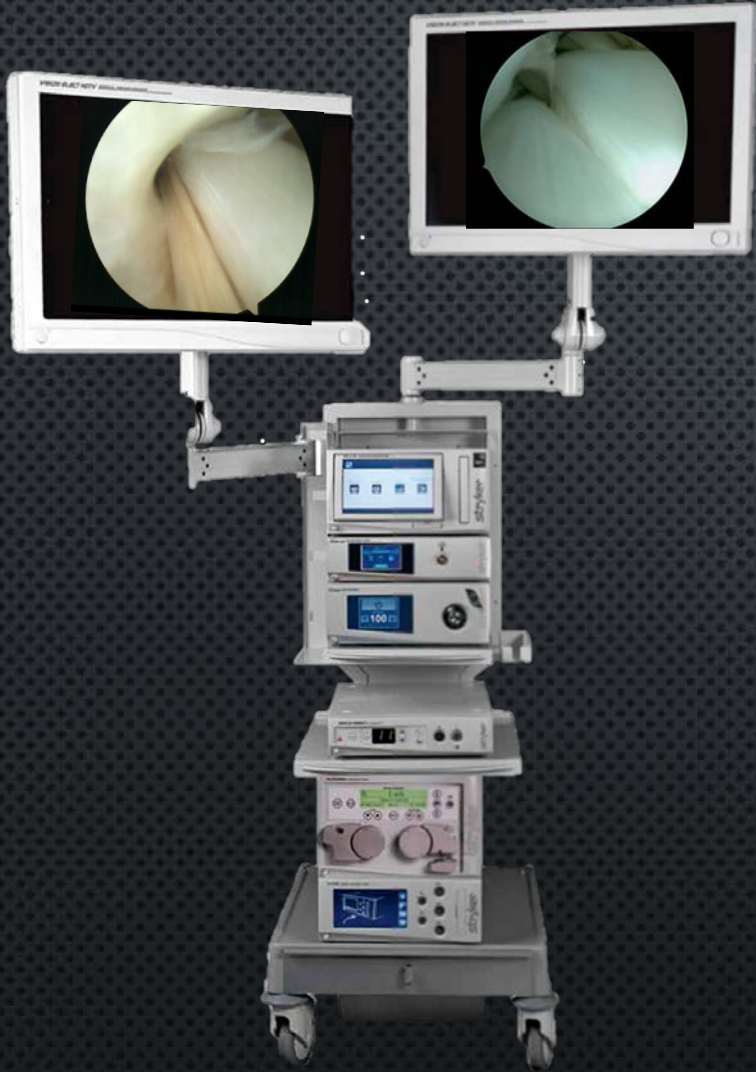

by Xavi Martín



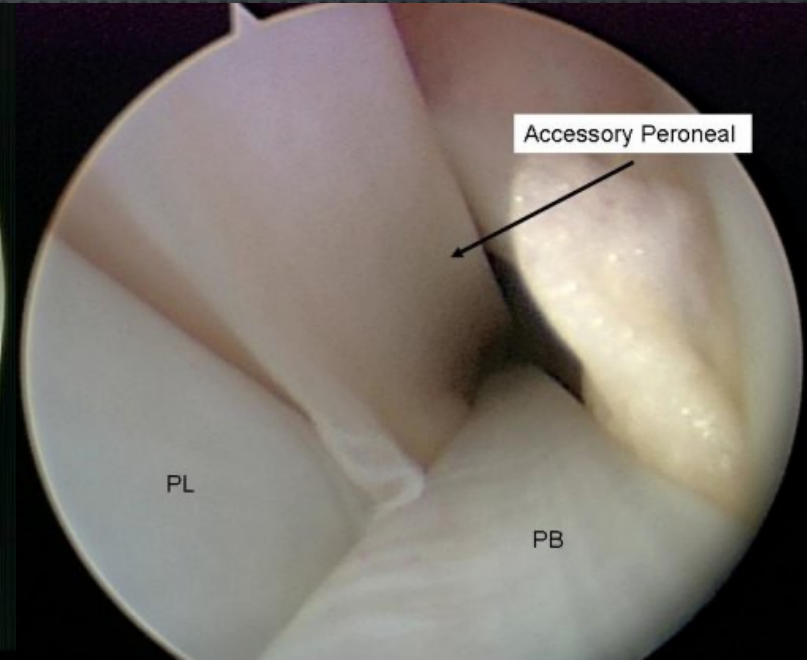
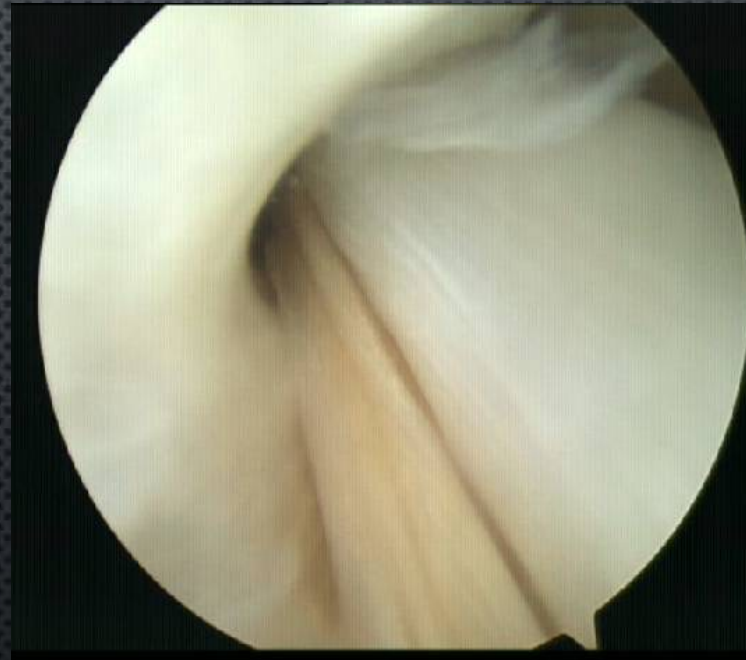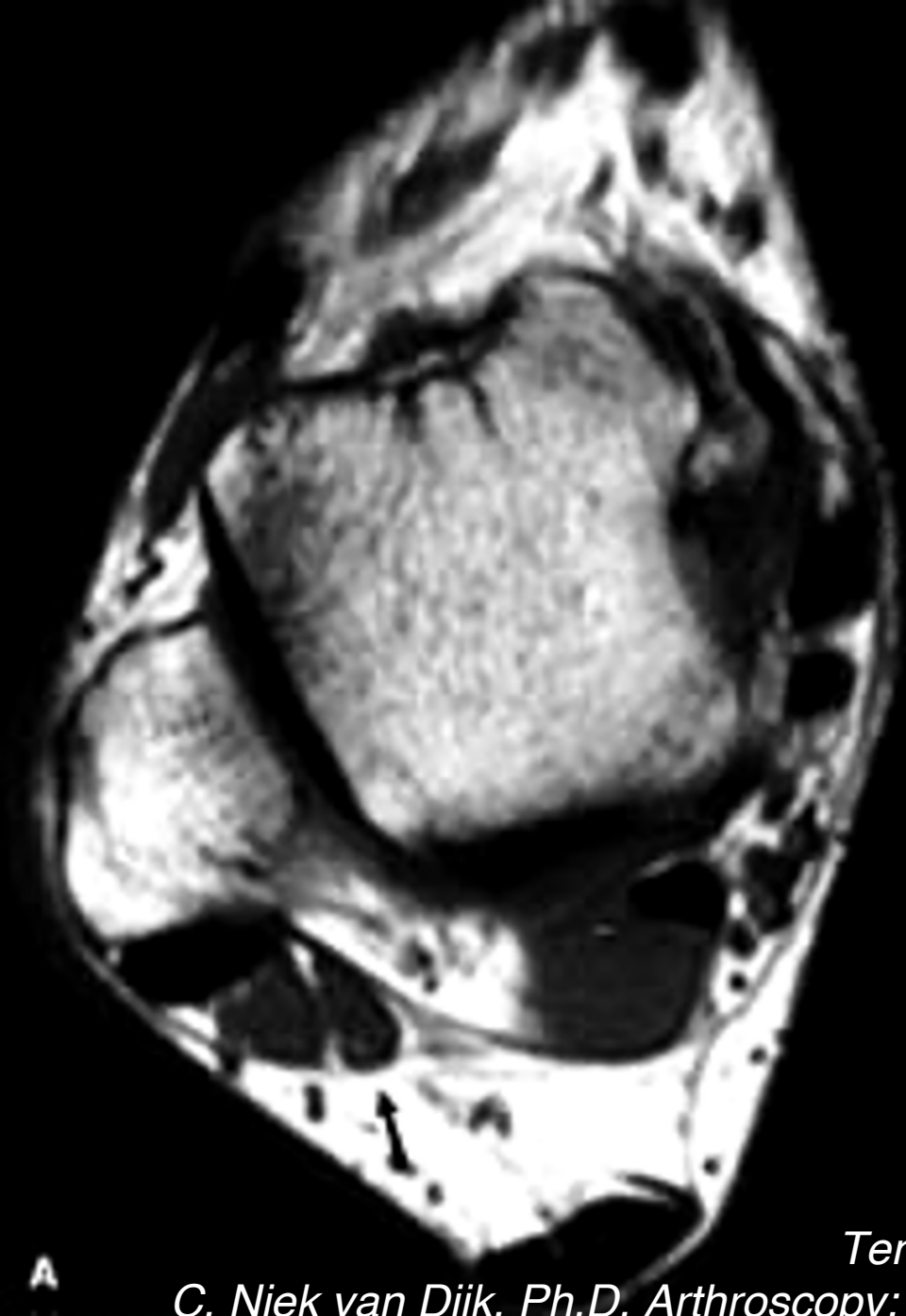
Sammarco VJ. Peroneal tendoscopy: indications and techniques. Sports Med. Arthrosc. 2009.; 17; 94-9.

## *Peroneous tendoscopy*



1. Tenosynovitis y tendinopathy
2. Instability
3. Tears
4. Variant of normality
5. Bone impingement
6. Peroneous quartus
7. Postsurgical adhesion
8. Intrasheath adhesion

*Variants of normality*

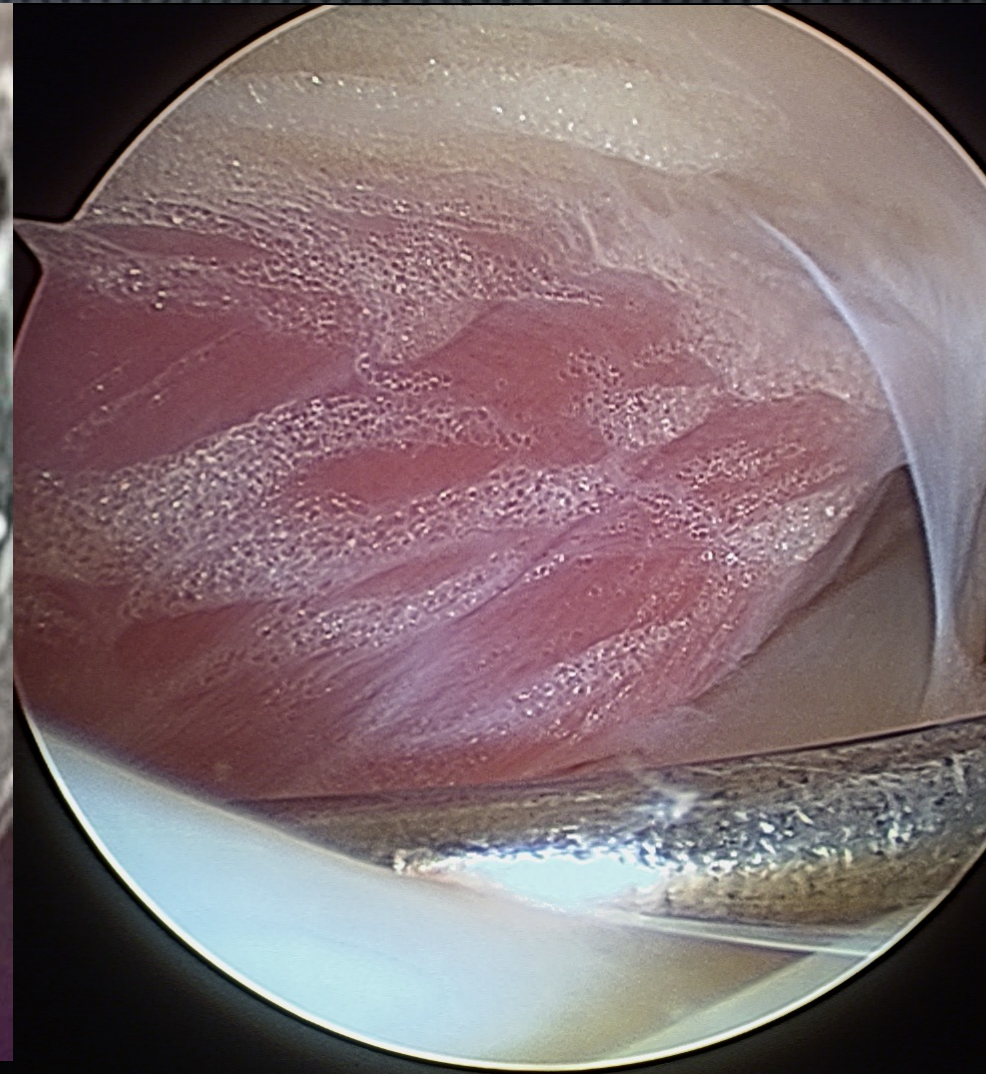
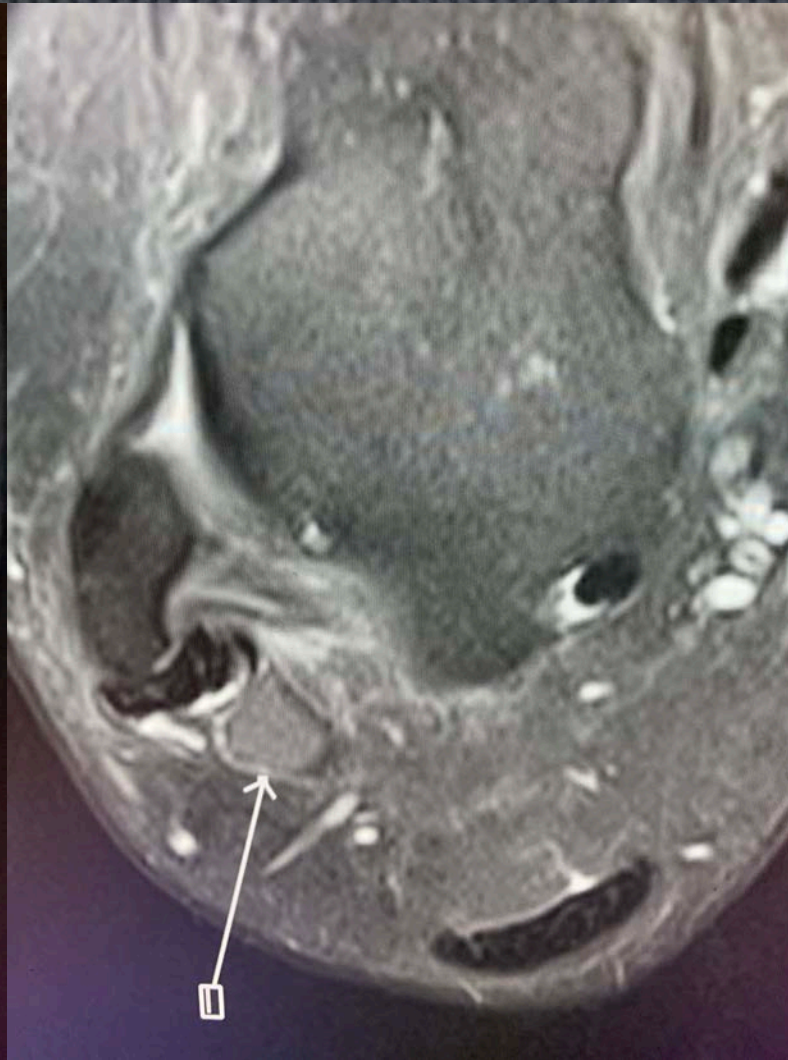
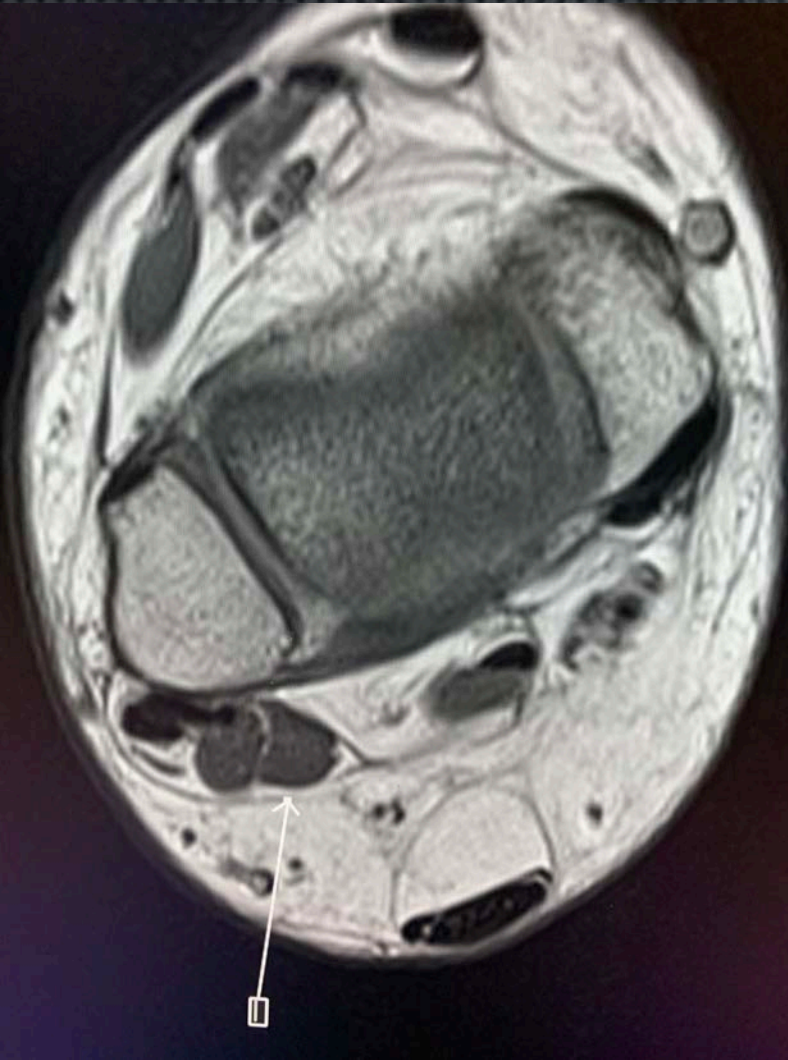


*Tendoscopy of the Peroneal tendons*

*C. Niek van Dijk, Ph.D. Arthroscopy: The Journal of Arthroscopic and Related Surgery. 1998; 14; 471-8.*

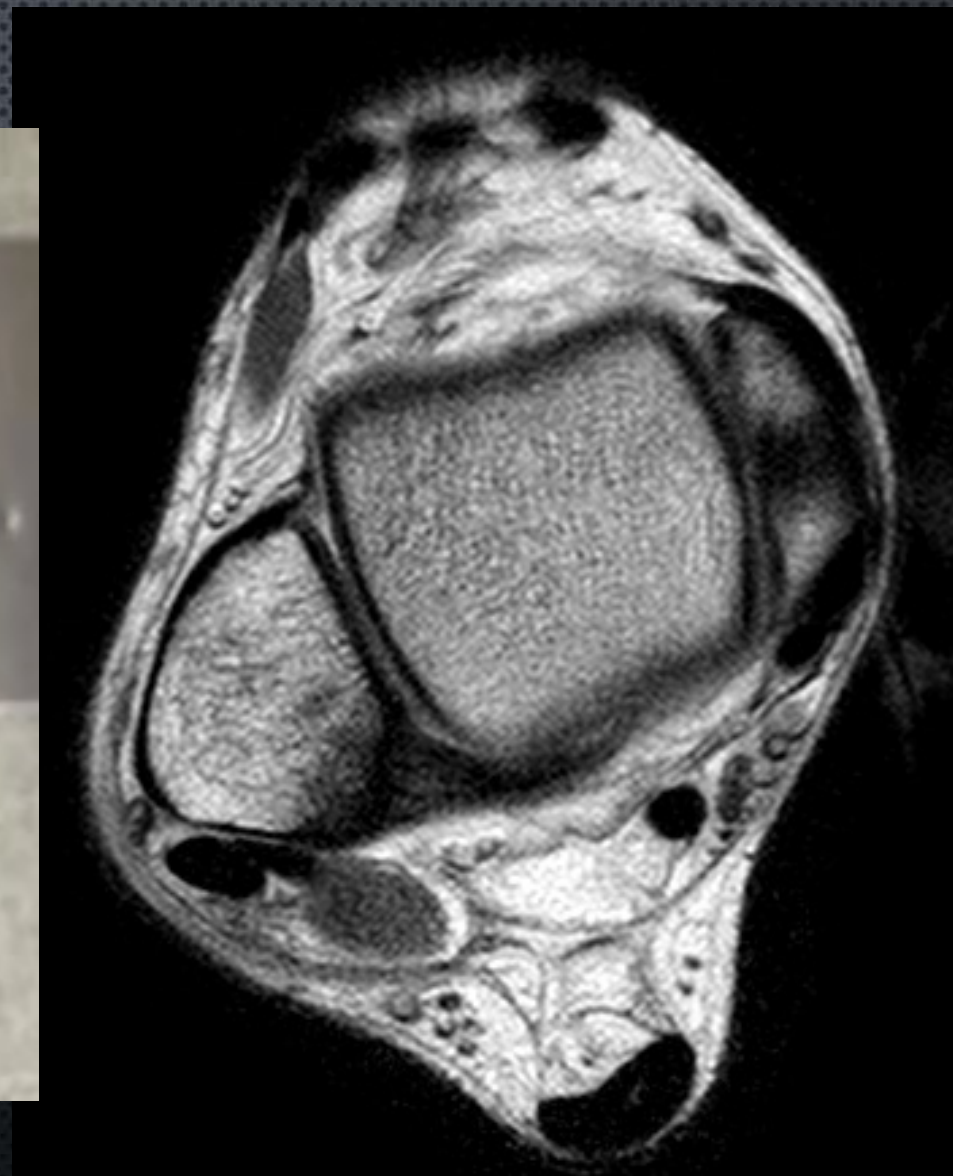
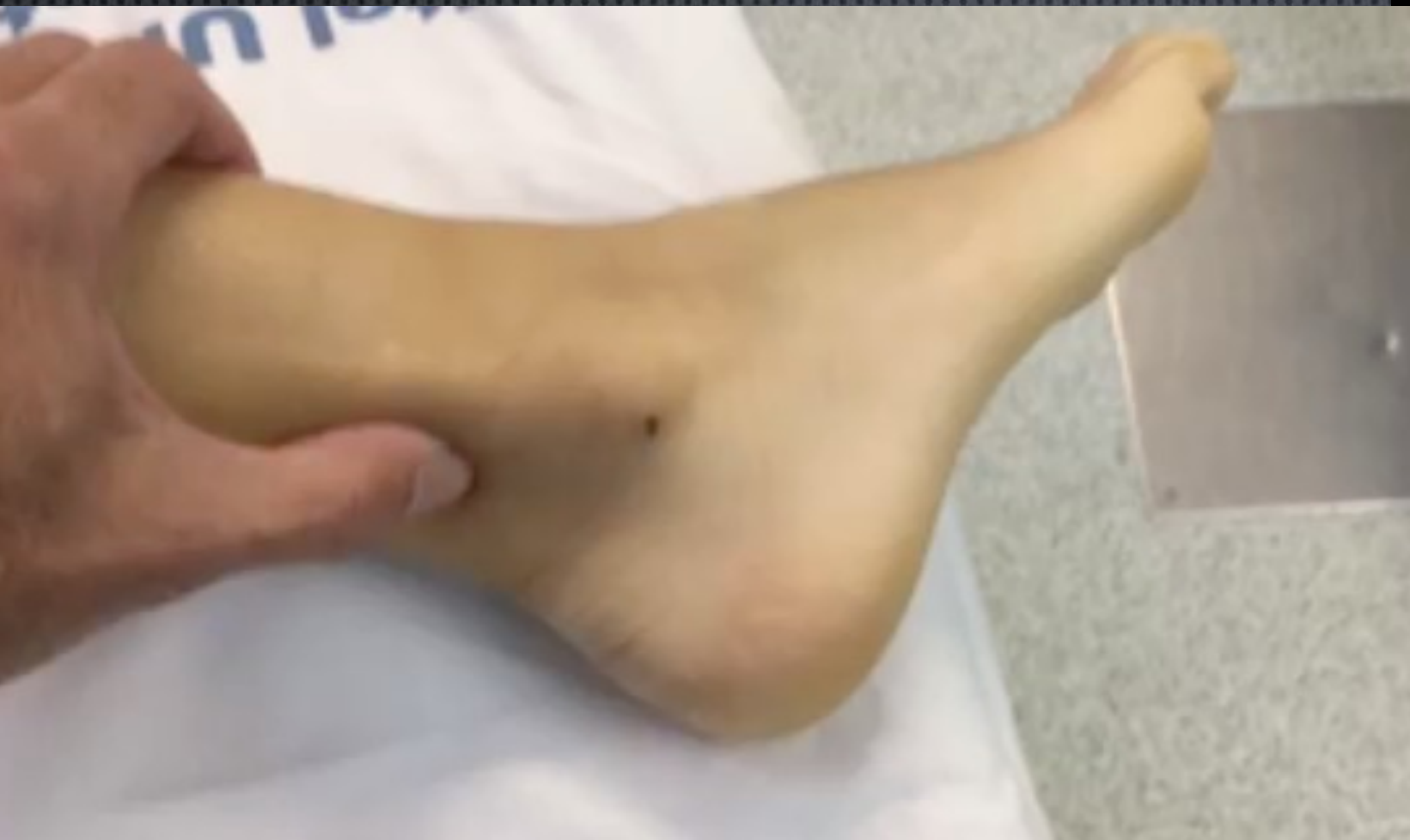A

*Variants of normality*



*Tears*

*Peroneal tendon dislocation*



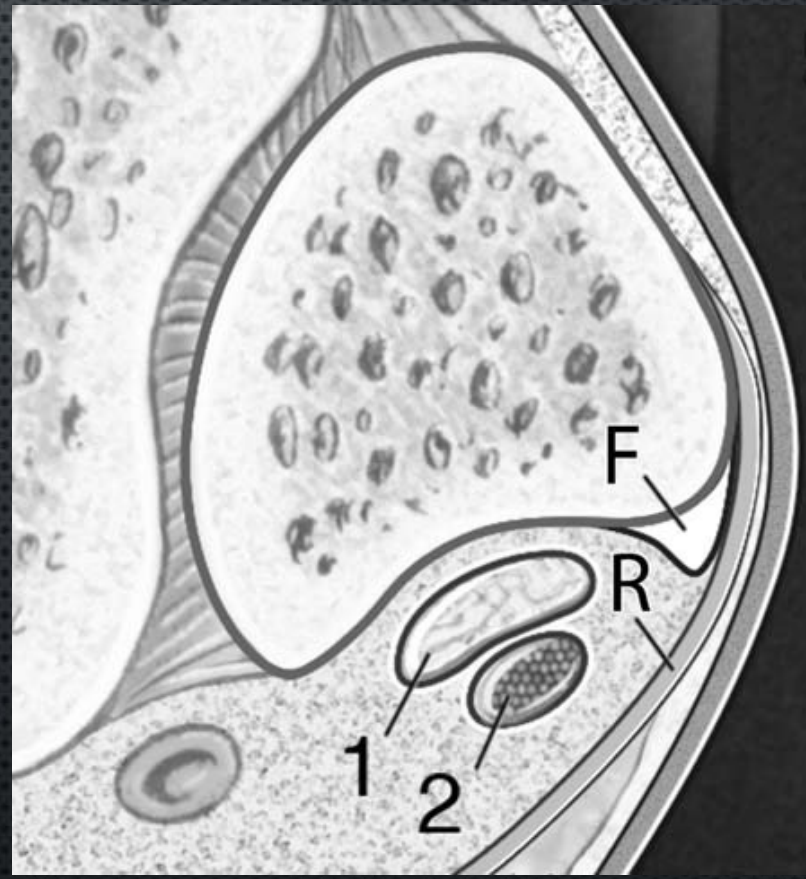
*Peroneal tendon dislocation*

Anatomical factors

Shape/Depth fibular

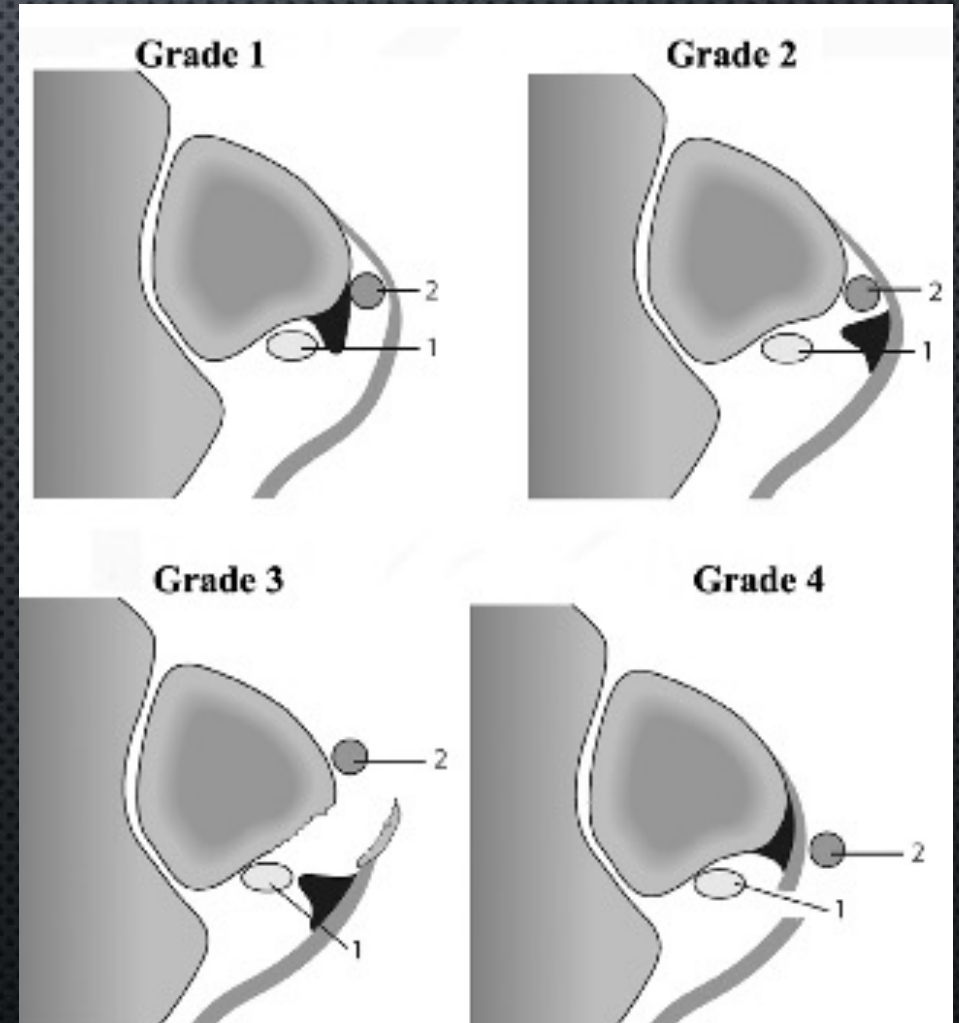
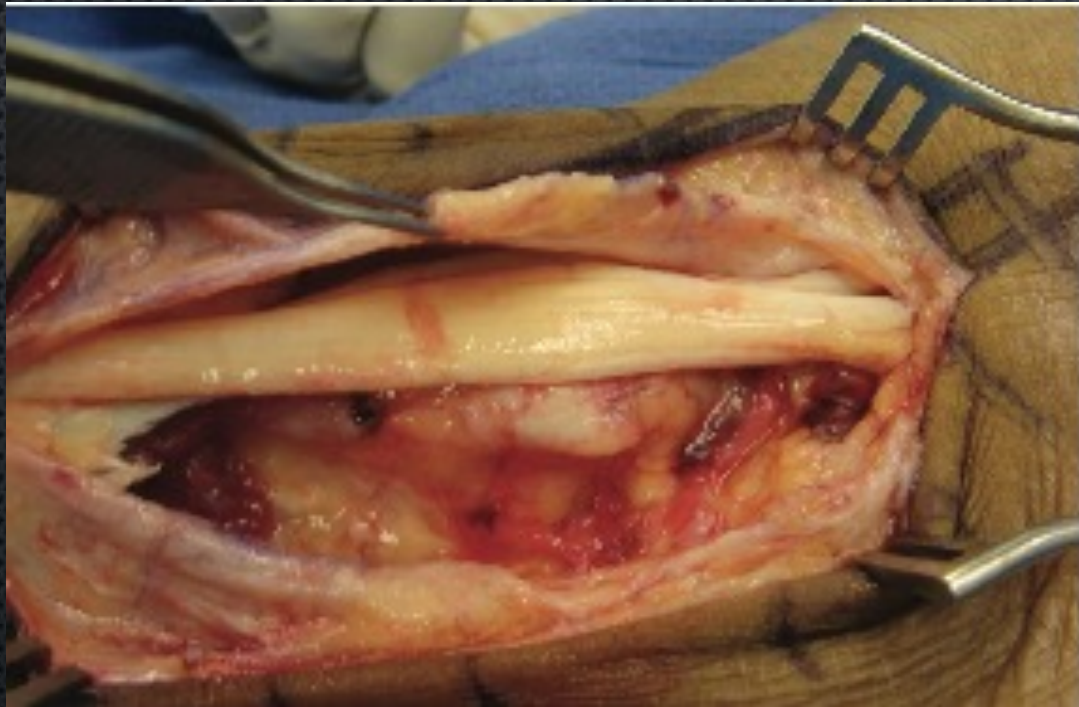Presence/absence fibrocartilage Groove

SRP instability

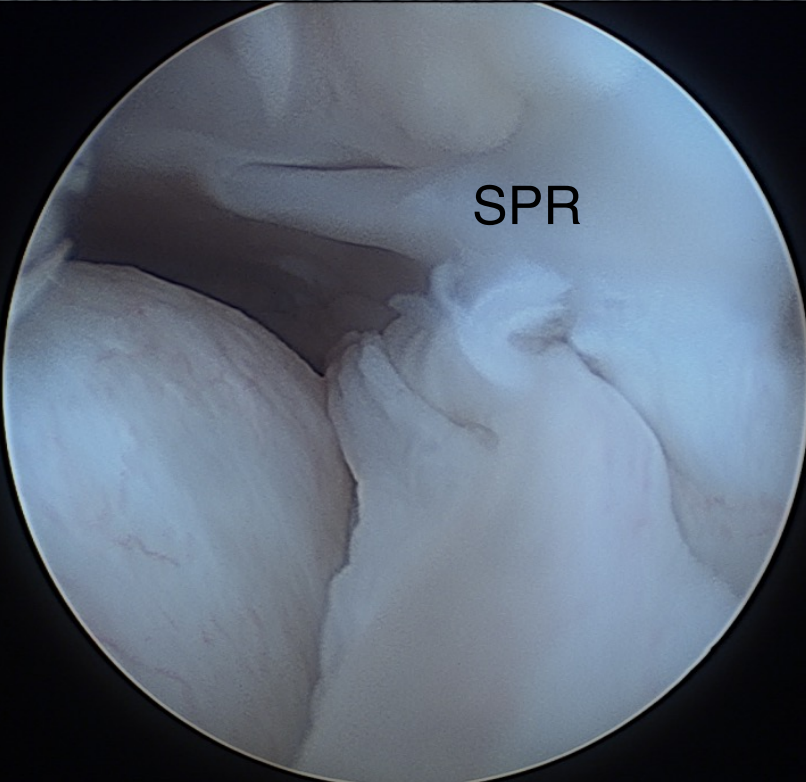
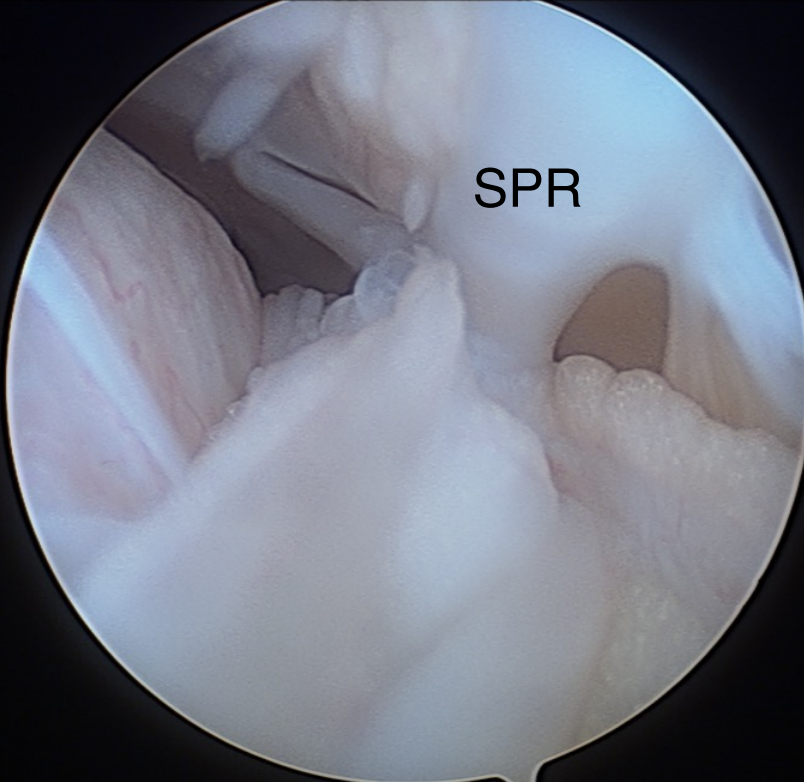
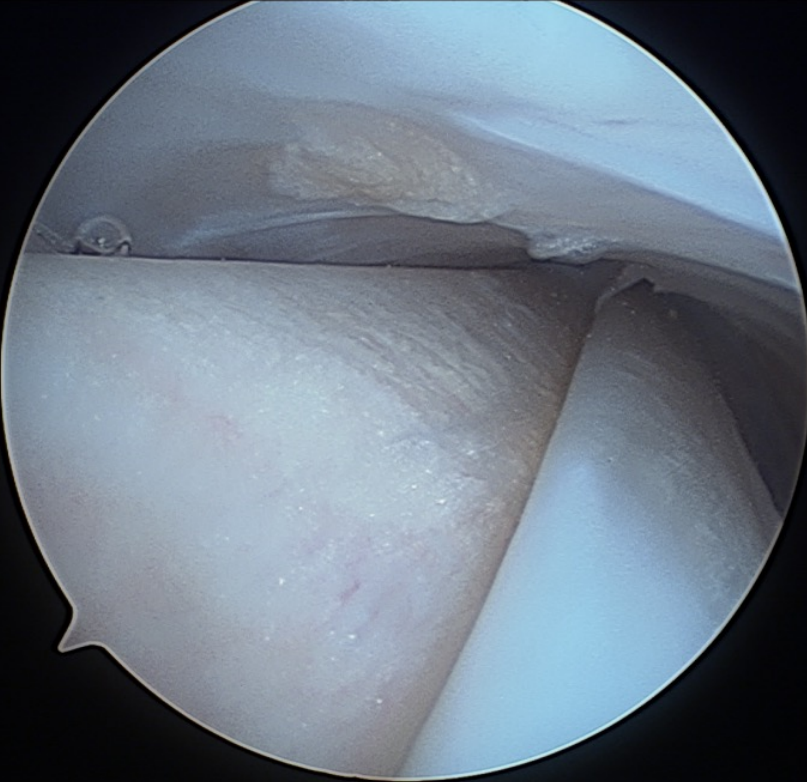




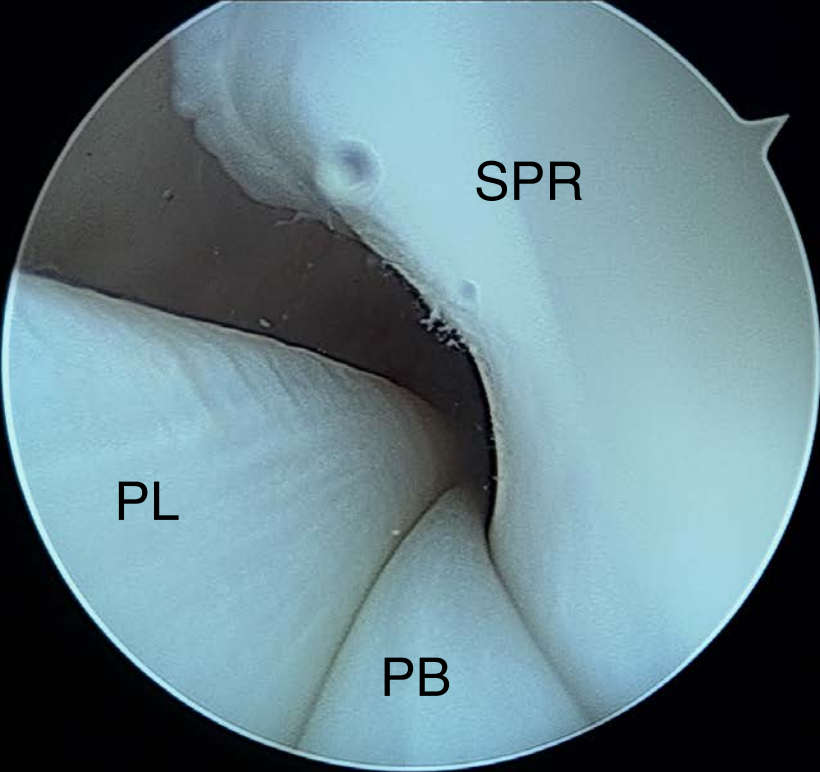
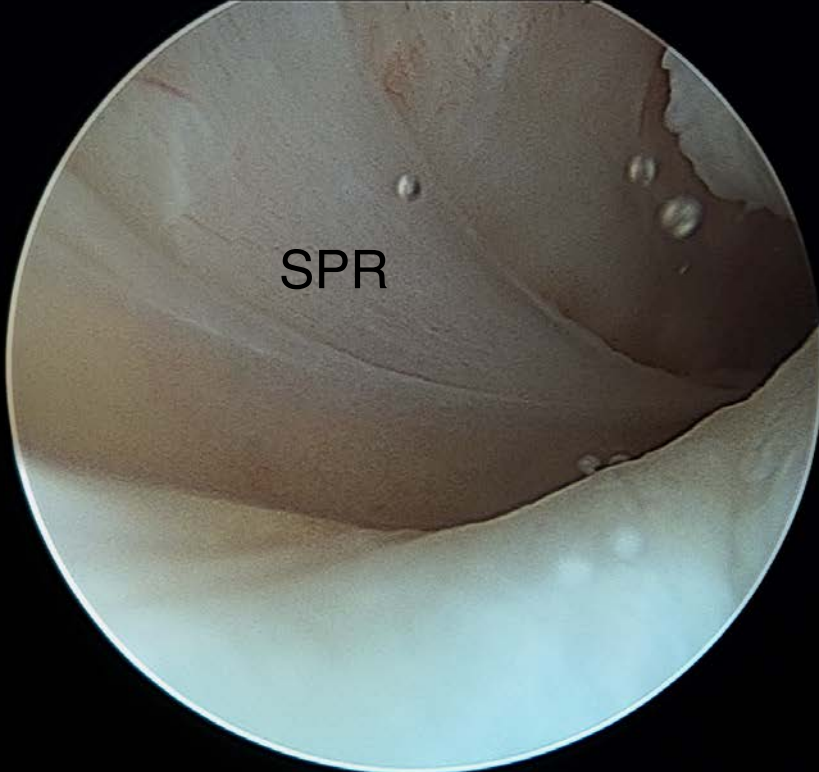
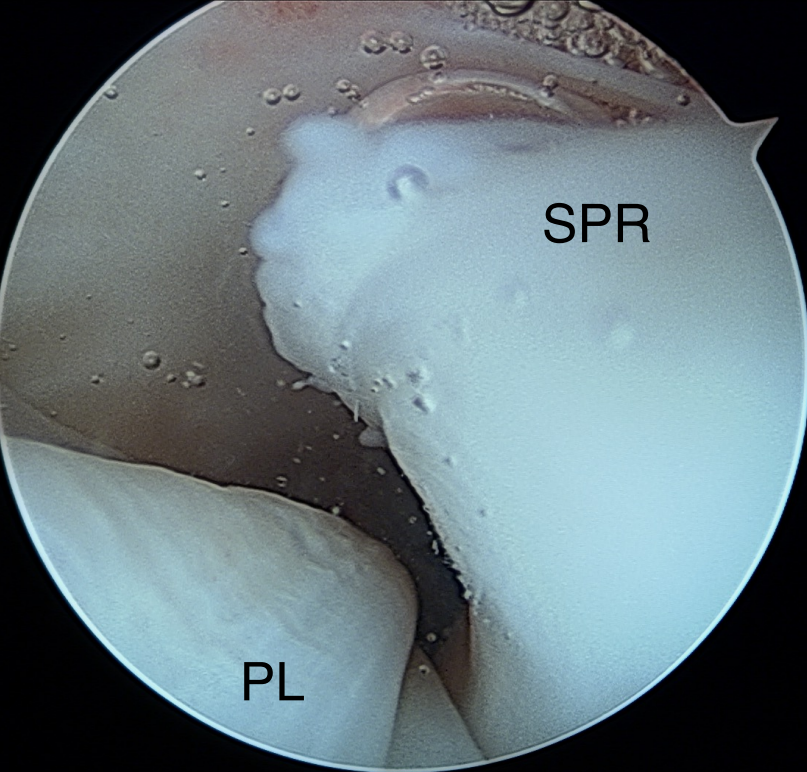
# *Peroneal tendon dislocation*



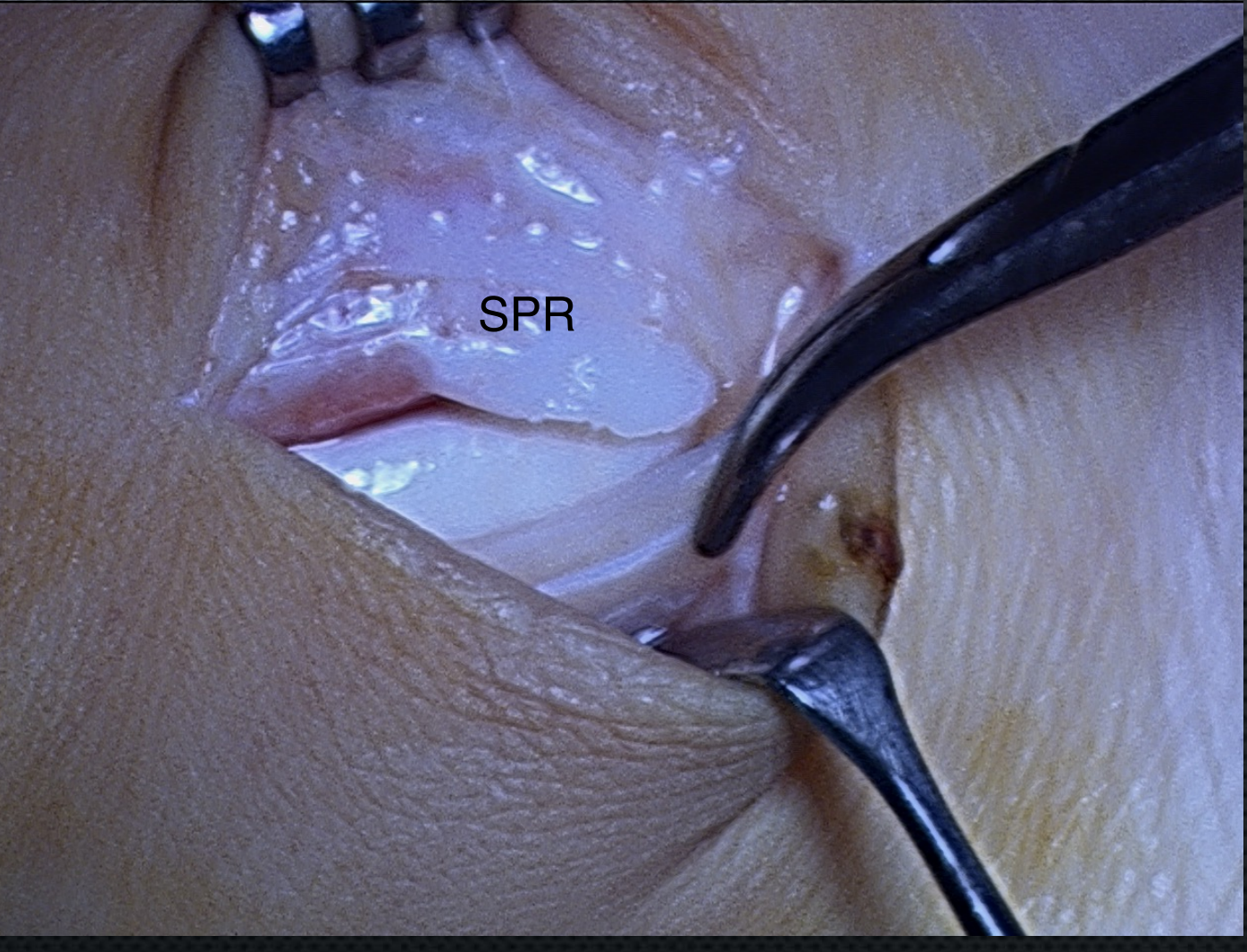
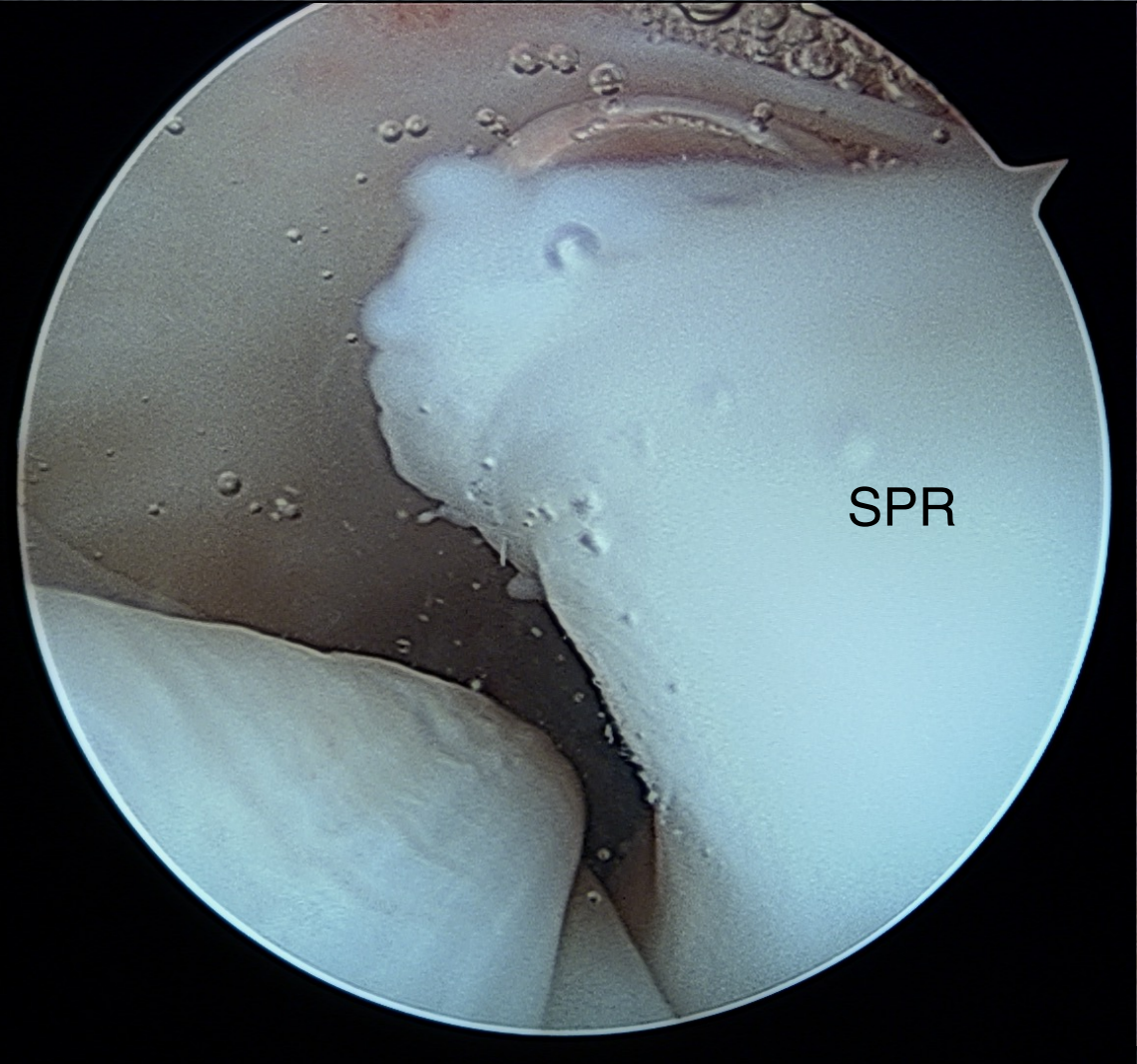
*Peroneal tendon dislocation*



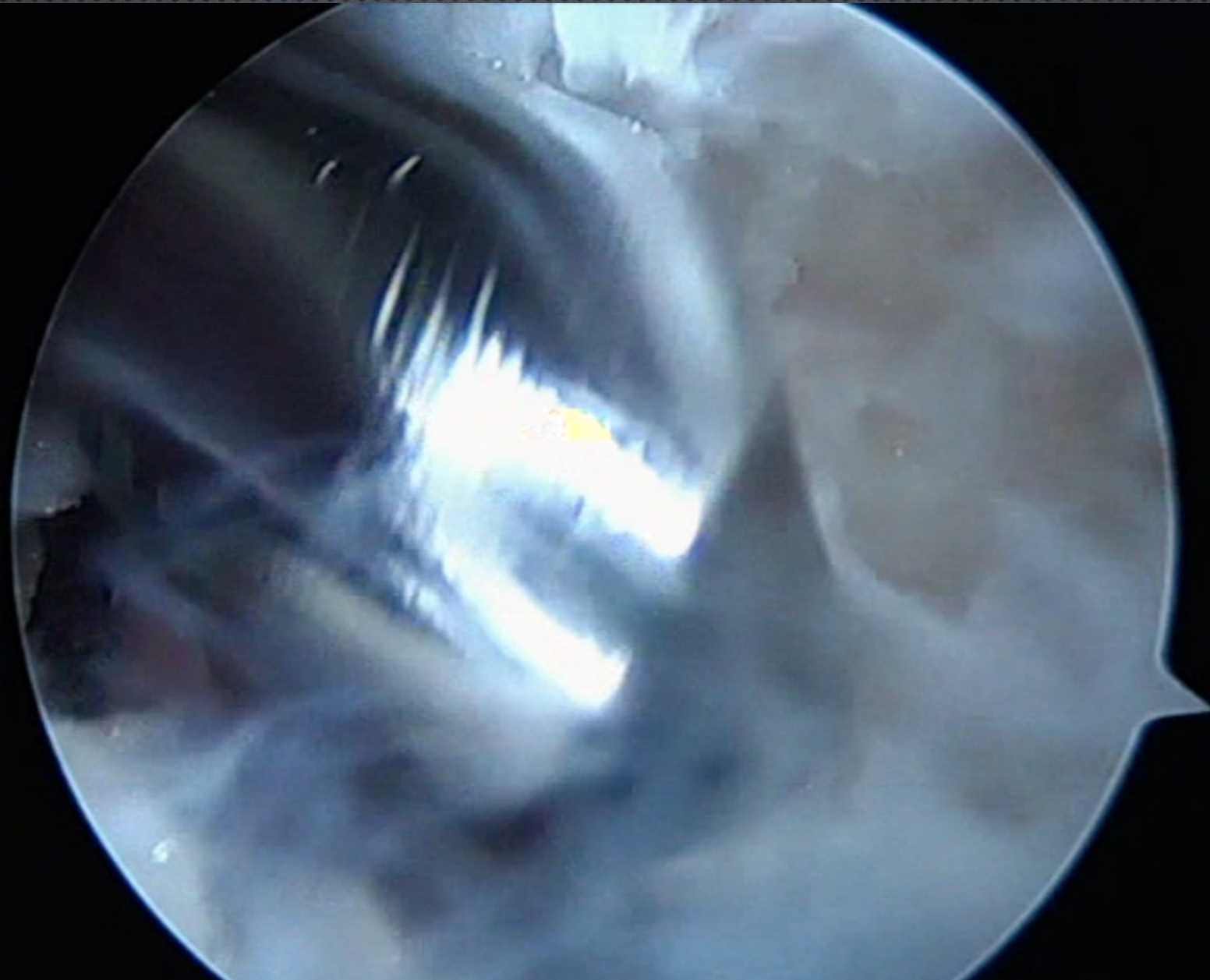
*Peroneal tendon dislocation*



*Peroneal tendon dislocation*

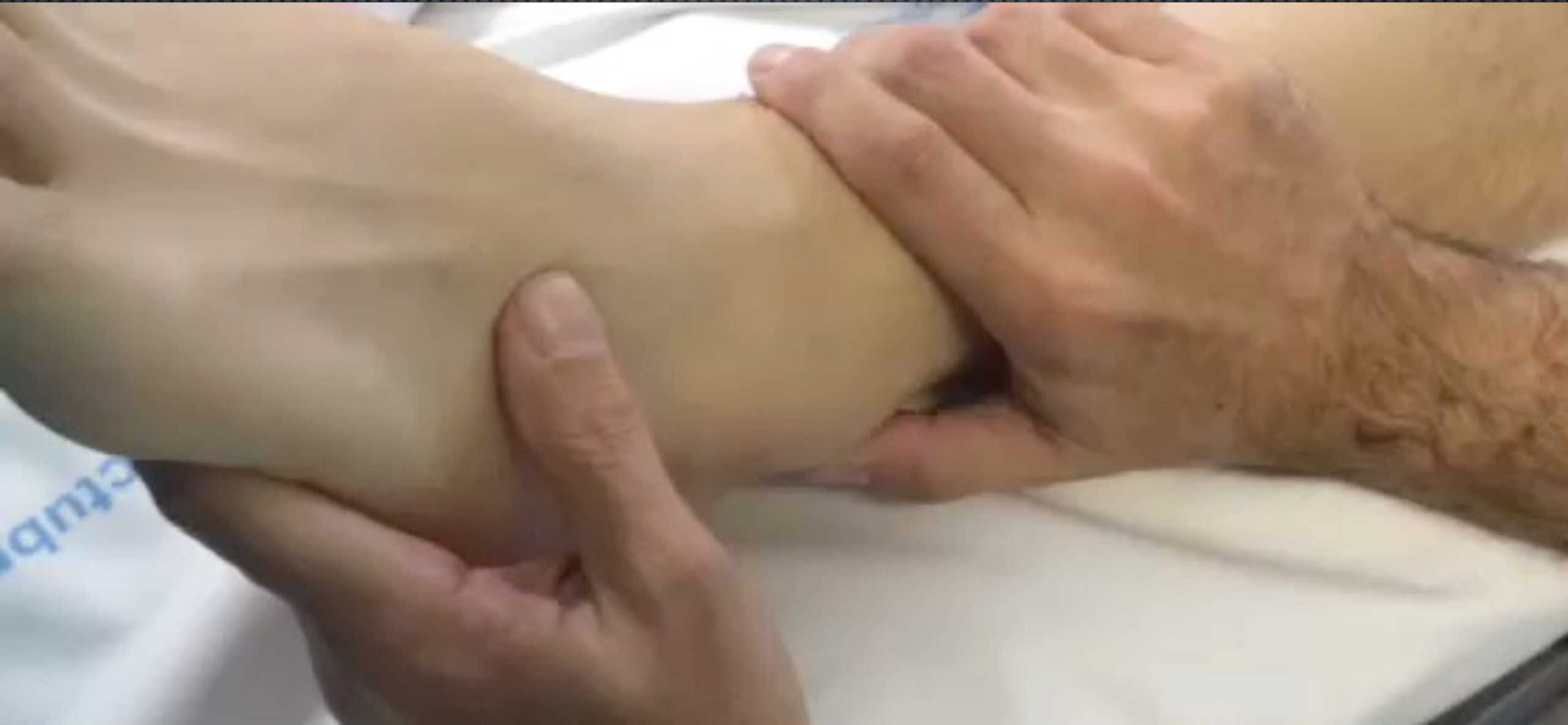

*Intrasheath subluxation type A*

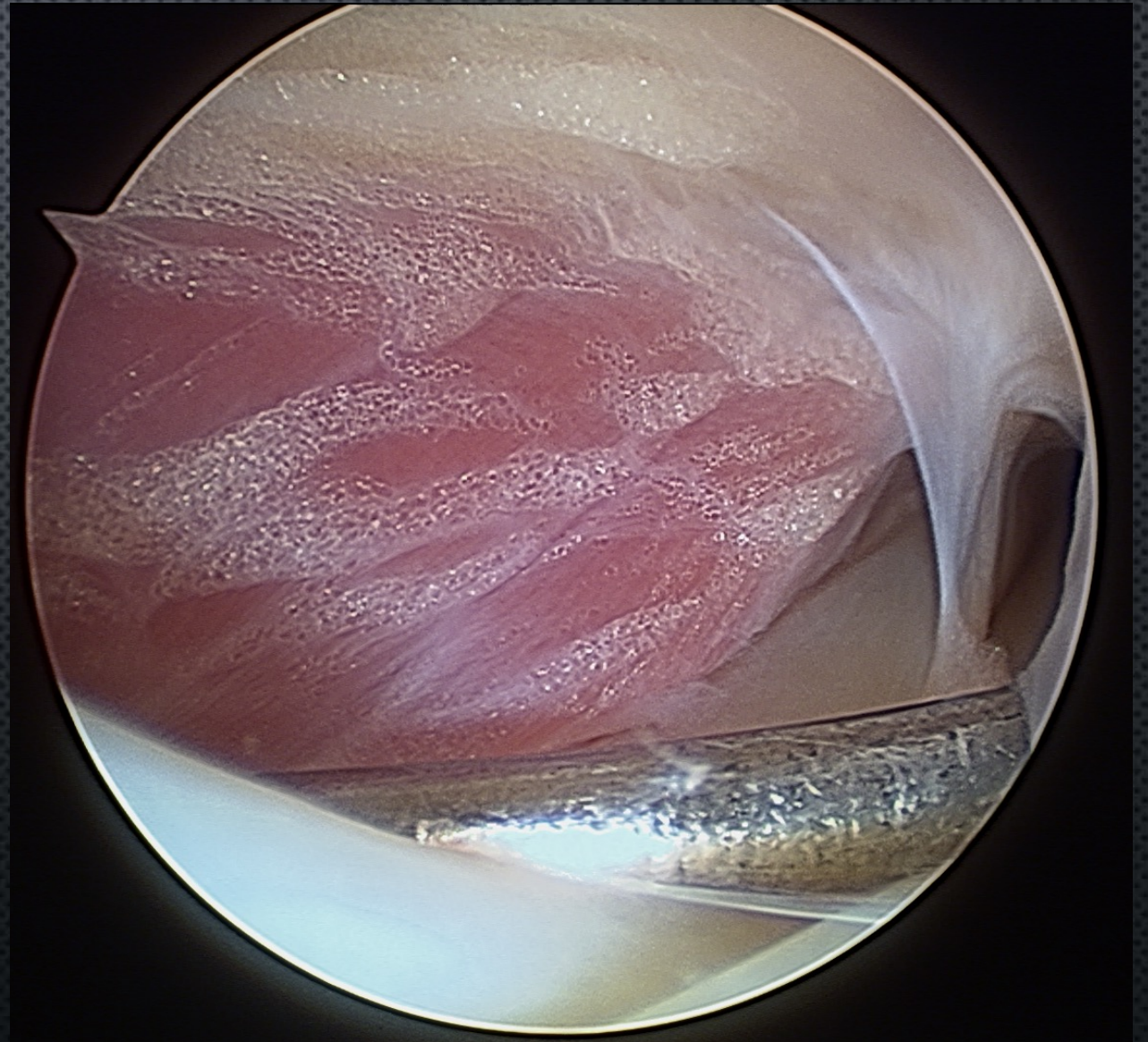
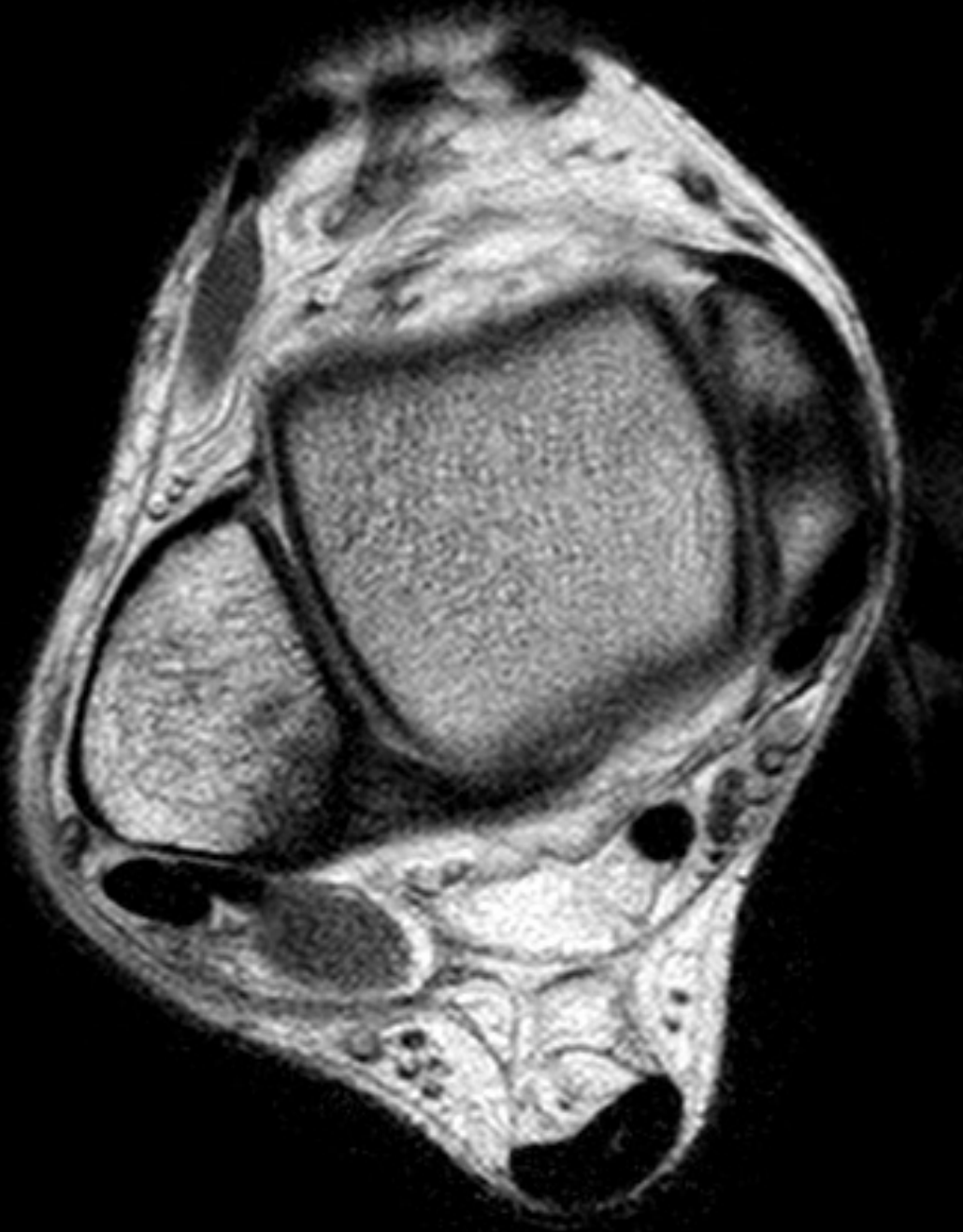

Steven M. Raikin, Ilan Elias and Levon N. Nazarian

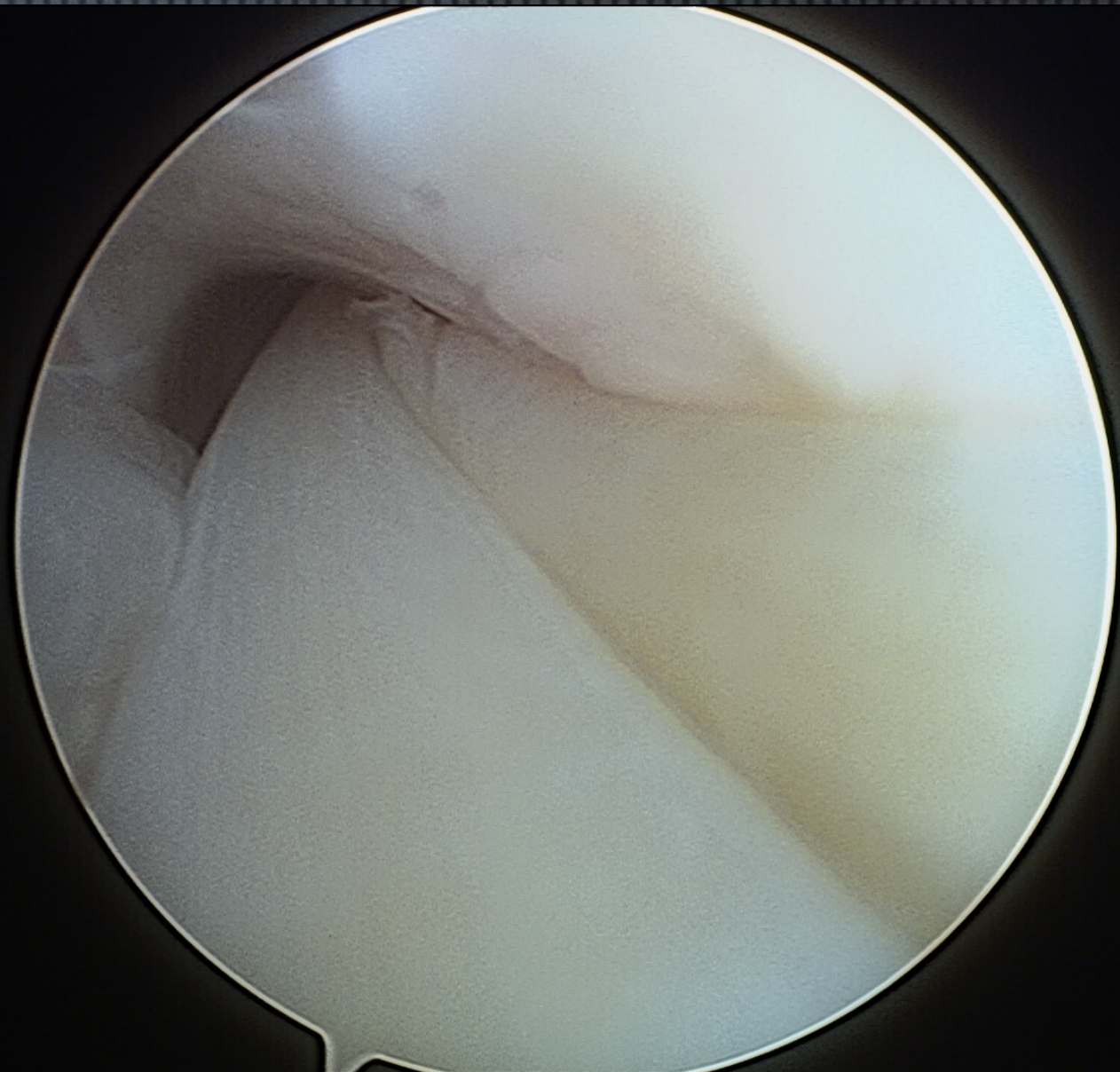
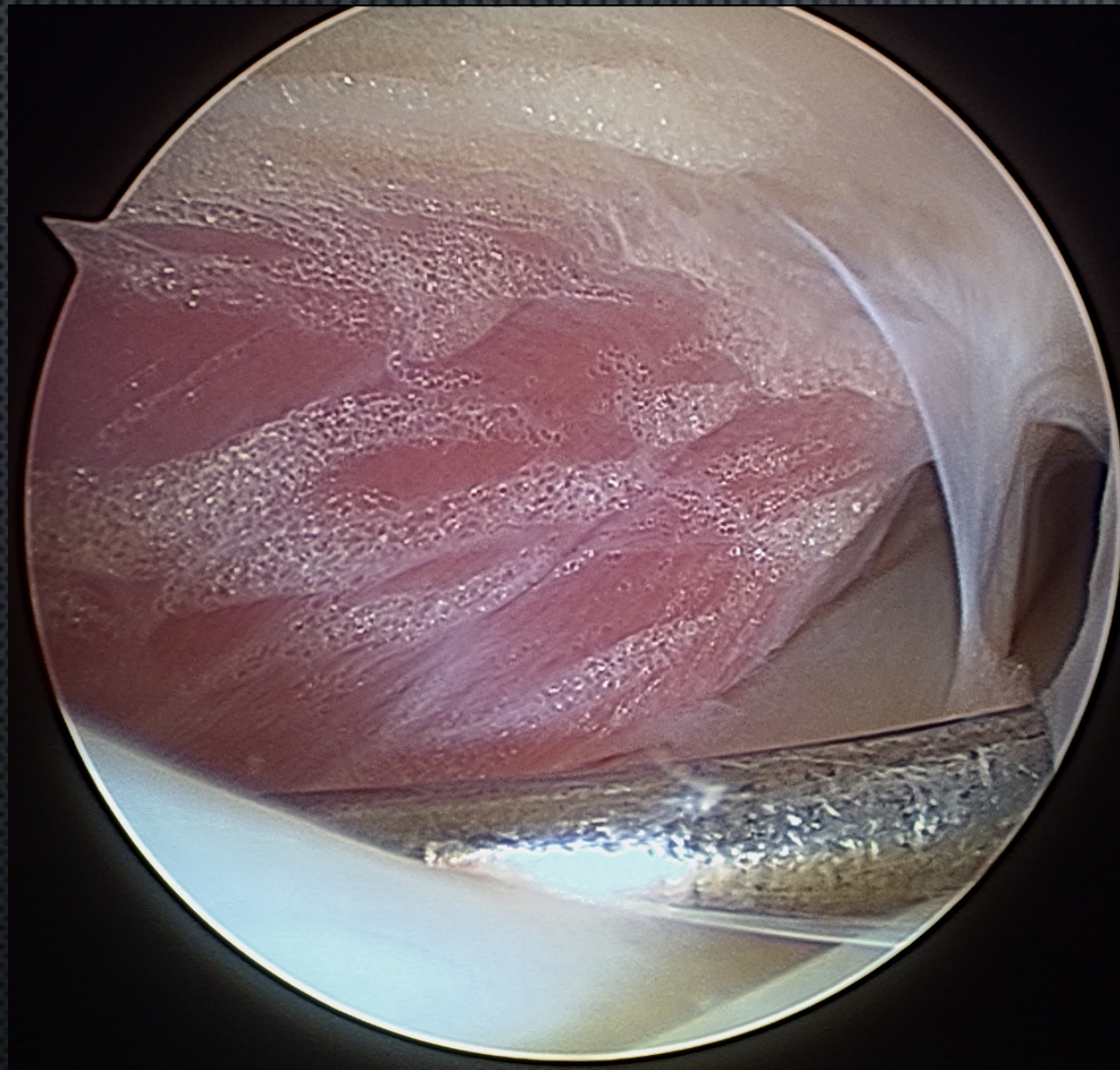
Intrasheath Siblucation of the Peroneal Tendons. J Bone Joint Surg Am 2008;90:992–999.



*Intrasheath subluxation type A*

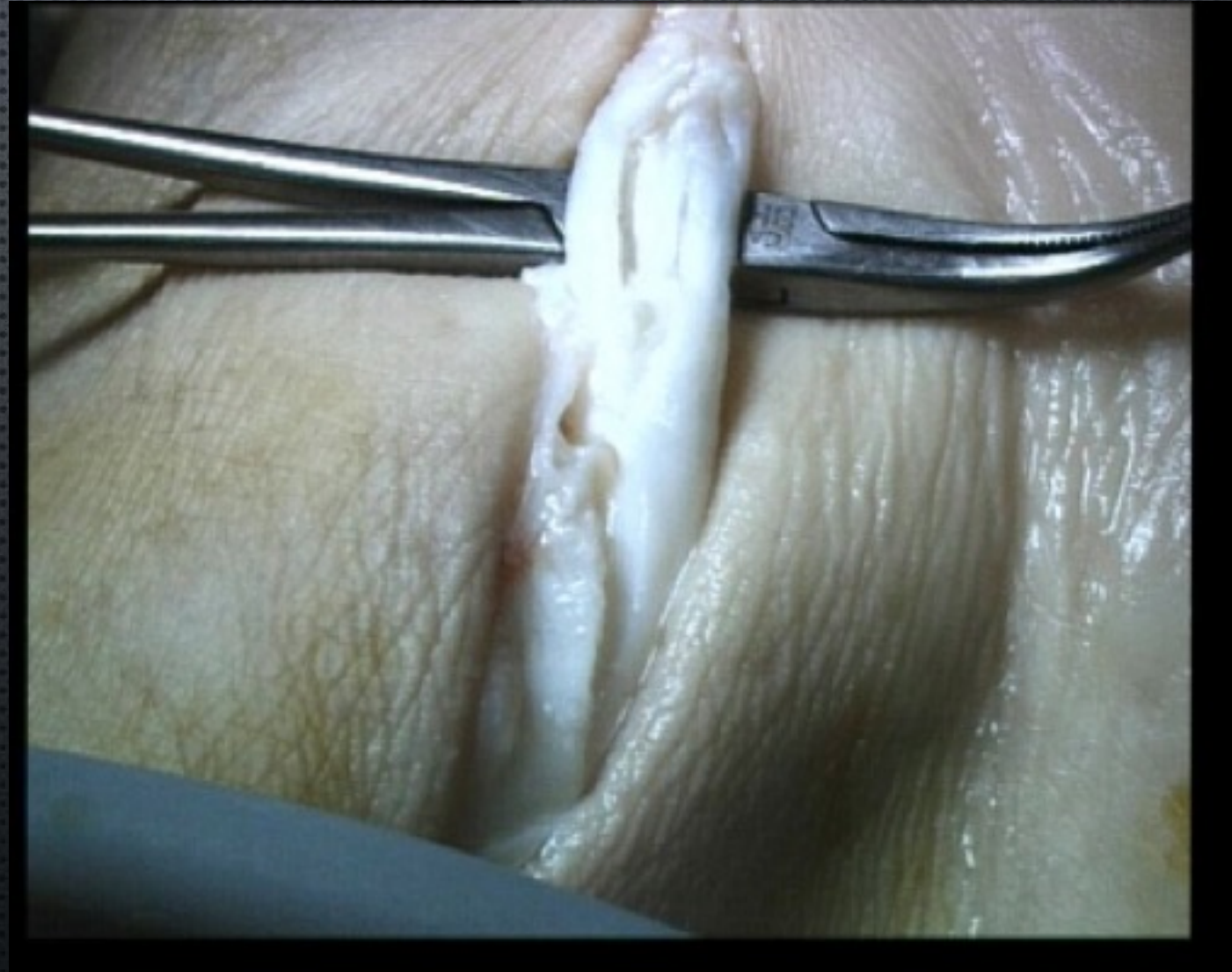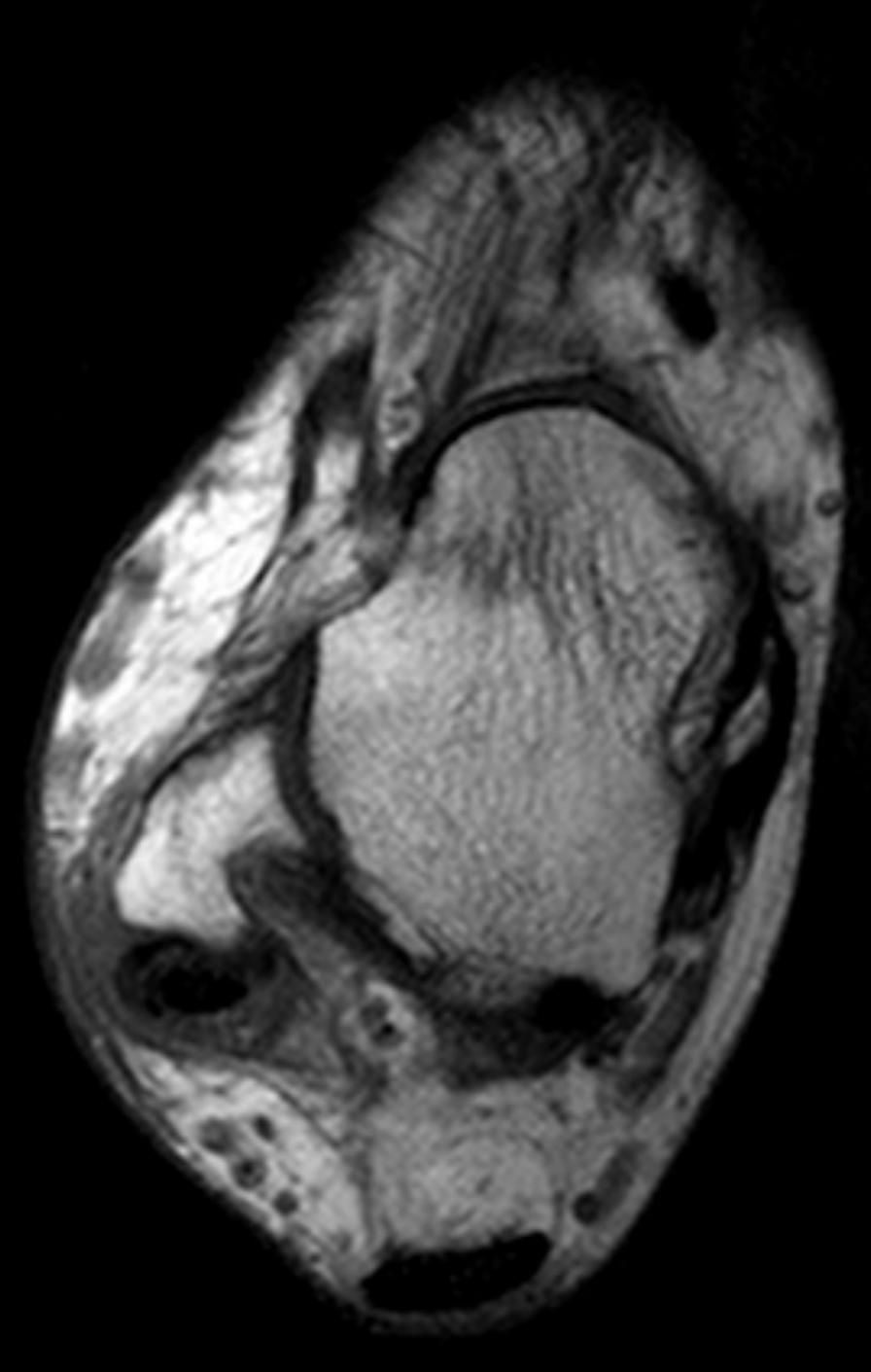


*Intrasheath subluxation type A*

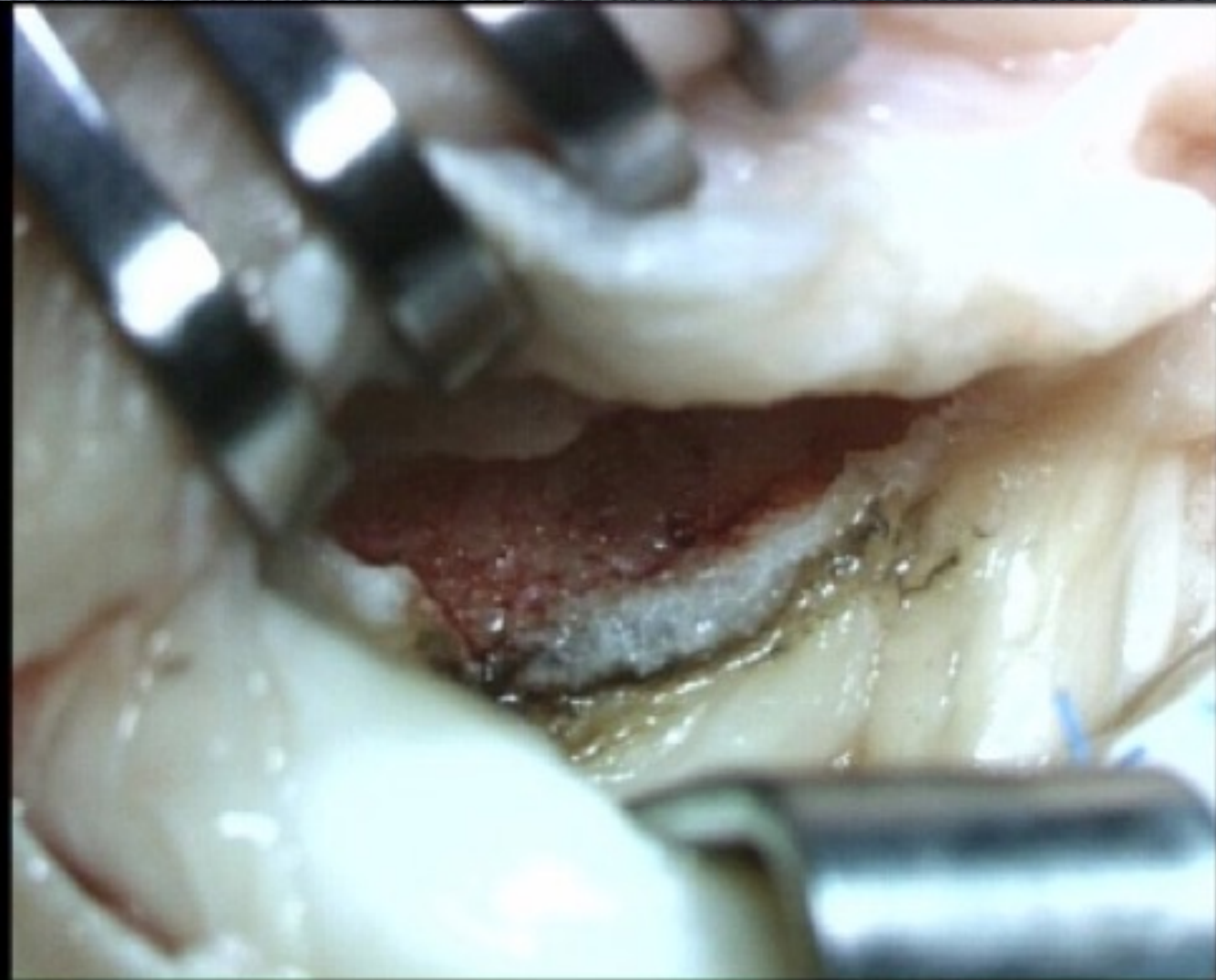
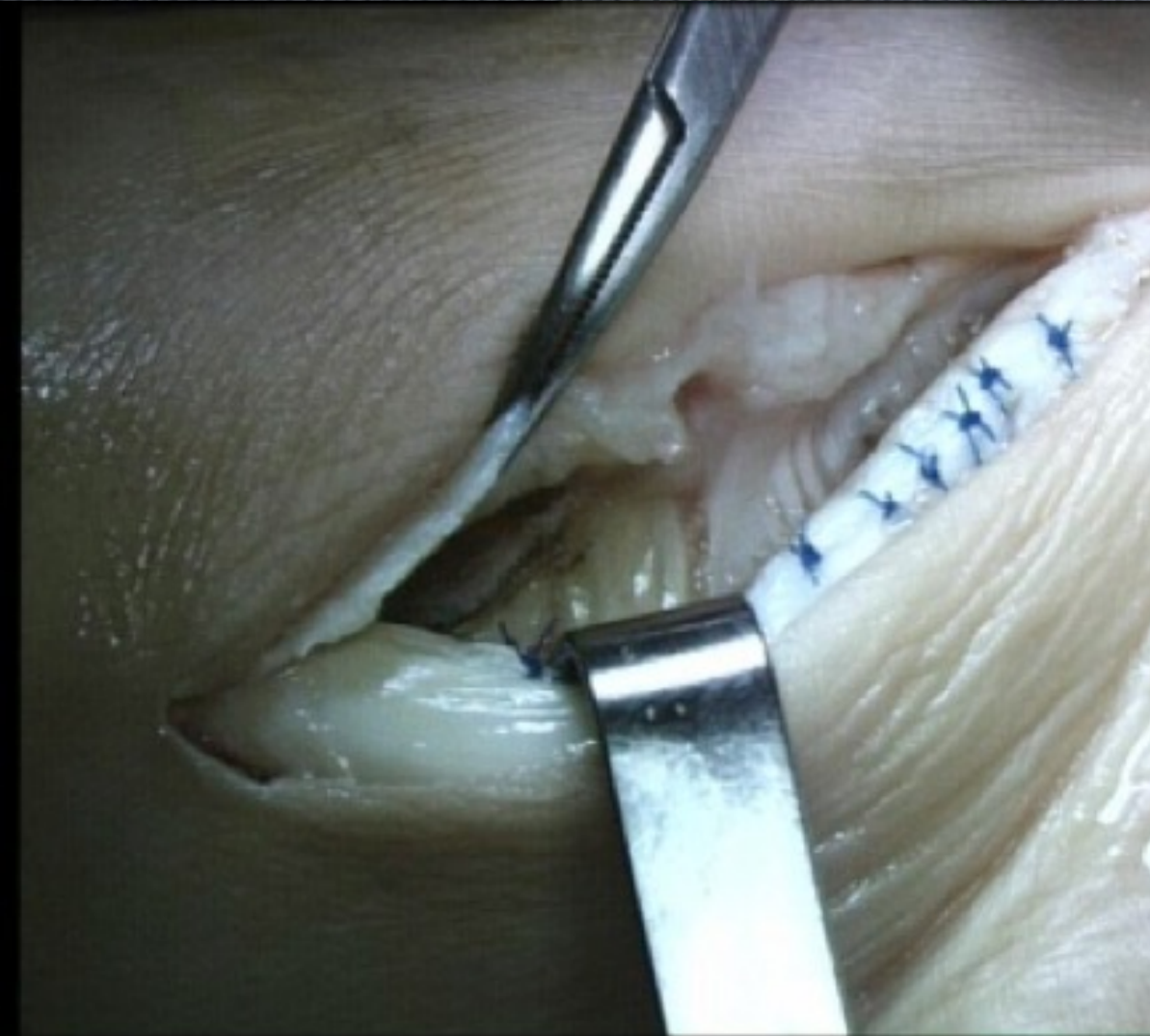




*Intrasheath subluxation type B*



*Intrasheath subluxation type B*



PATOLOGIA	TRATAMIENTO
Tenosinovitis	Tenosinovectomía
Tendinopatía	Desbridamiento y escisión del área de tendinosis
Roturas	
Roturas longitudinales parciales < 50%	Desbridamiento endoscópico y tubulización
Roturas longitudinales parciales > 50%	Sutura tendoscópica +/- profundización del surco retromaleolar
Luxación tendones:	
Extravaina grados 1 y 2	Profundización del surco retromaleolar
Extravaina grados 3	Reconstrucción tendoscópica del RPS
Intravaina tipo A	Profundización del surco retromaleolar
Intravaina tipo B	Profundización del surco retromaleolar+reparación PC
Impingement por peroneus tertius/quartus	Escisión
Hipertrofia muscular (vientre de inserción bajo del PC)	Resección de fibras musculares distales
Prominencias óseas del maleolo peroneo	Escisión
Impingement por tubérculo peroneo prominente	Escisión/fresado/aplanamiento
Estenosis canal retromaleolar	Resección/liberación del retináculo
Adhesión tendones por vincula gruesa	Liberación de la vincula
Adherencias postfractura/postquirúrgicas	Desbridamiento

*B.Bravo-Giménez, L. García-Lamas, L.F. Llanos-Alcázar, J. Vilá y Rico.*

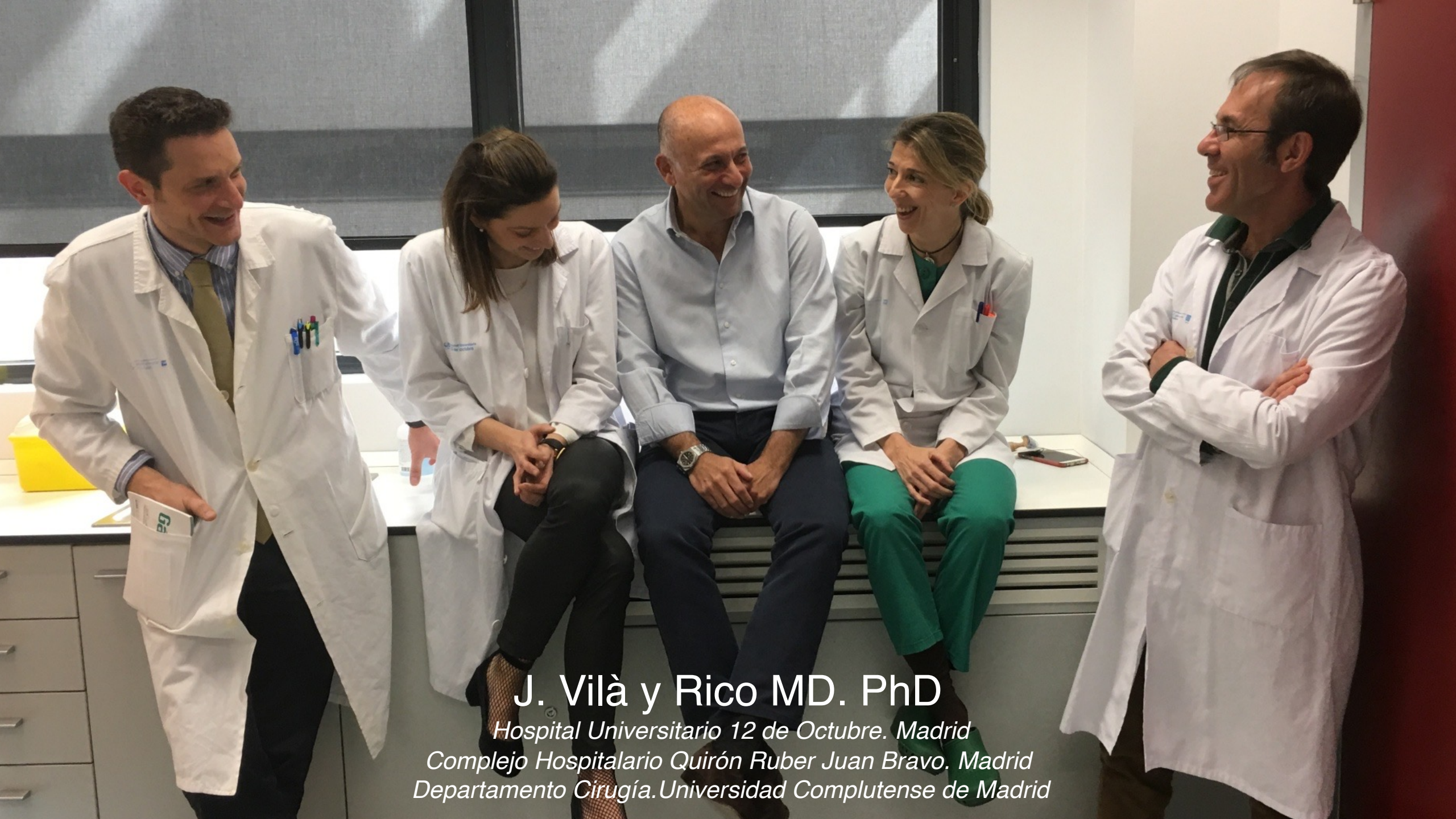*Tendoscopia de los peroneos: nuestra experiencias. Rev. Esp. Cir. Ortop. Traumatol. 2013;57 (4): 268-275.*

## TO TAKE HOME

*Deep anatomic knowledges and experience in arthroscopy/endoscopy is required.*

## TO TAKE HOME

Endoscopic surgeries are safe and reproducible with a low rate of complications. Several advantages (less morbidity, early range of motion & reduction in postoperative pain)



## J. Vilà y Rico MD. PhD

*Hospital Universitario 12 de Octubre. Madrid  
Complejo Hospitalario Quirón Ruber Juan Bravo. Madrid  
Departamento Cirugía. Universidad Complutense de Madrid*



**J. Vilà y Rico MD. PhD**

*Hospital Universitario 12 de Octubre. Madrid  
Complejo Hospitalario Quirón Ruber Juan Bravo. Madrid  
Departamento Cirugía. Universidad Complutense de Madrid*