

Hospital  
del Mar

Parc  
de Salut  
**MAR**  
Barcelona

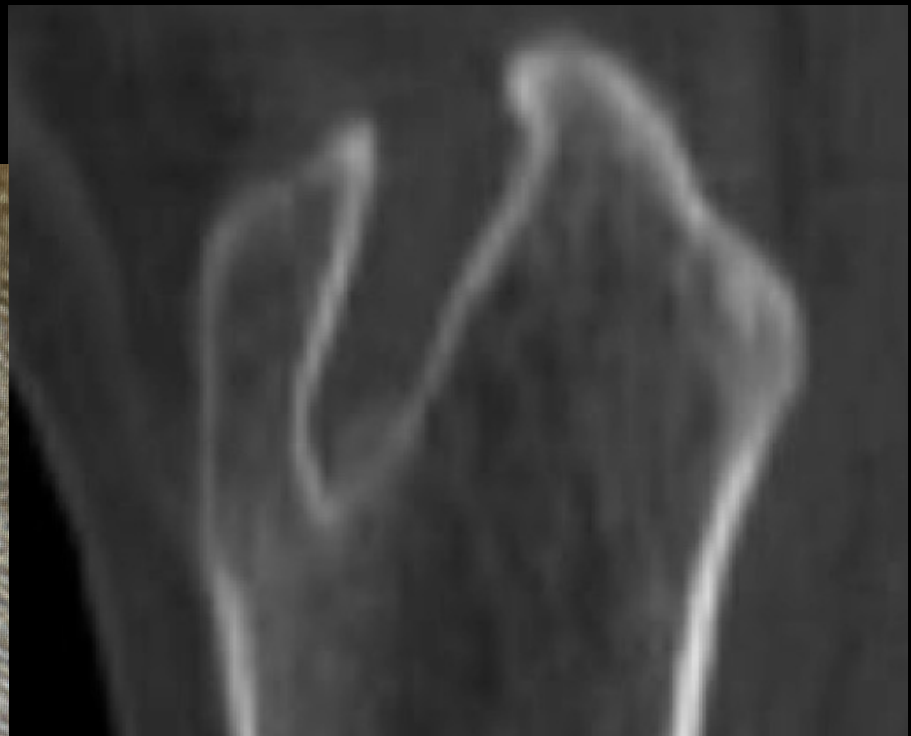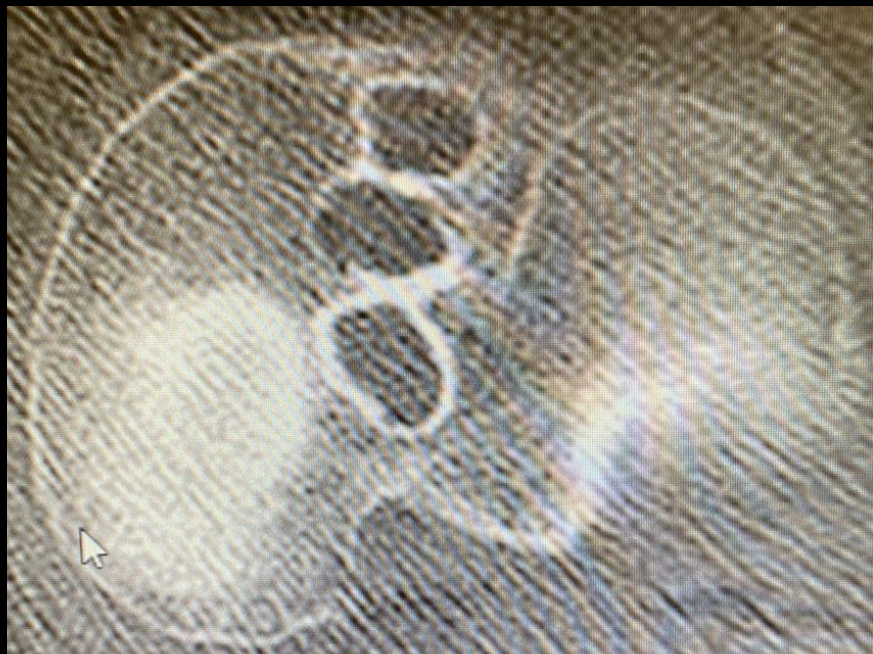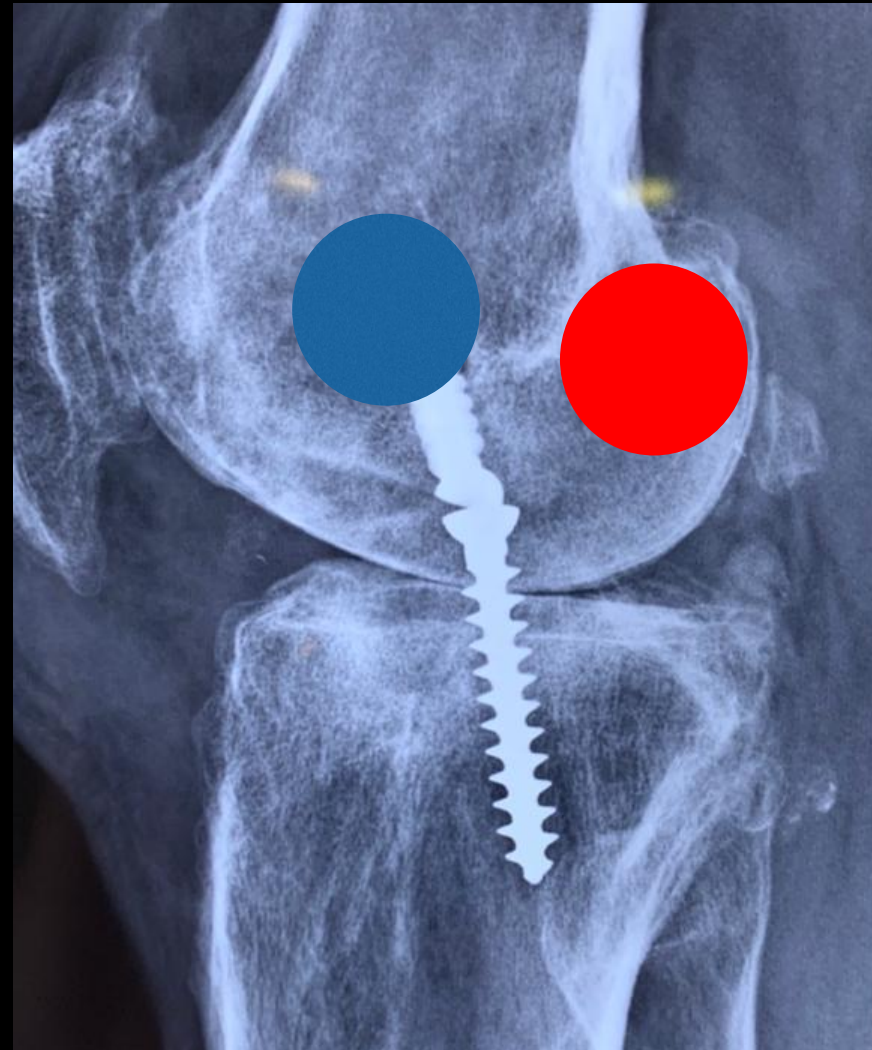
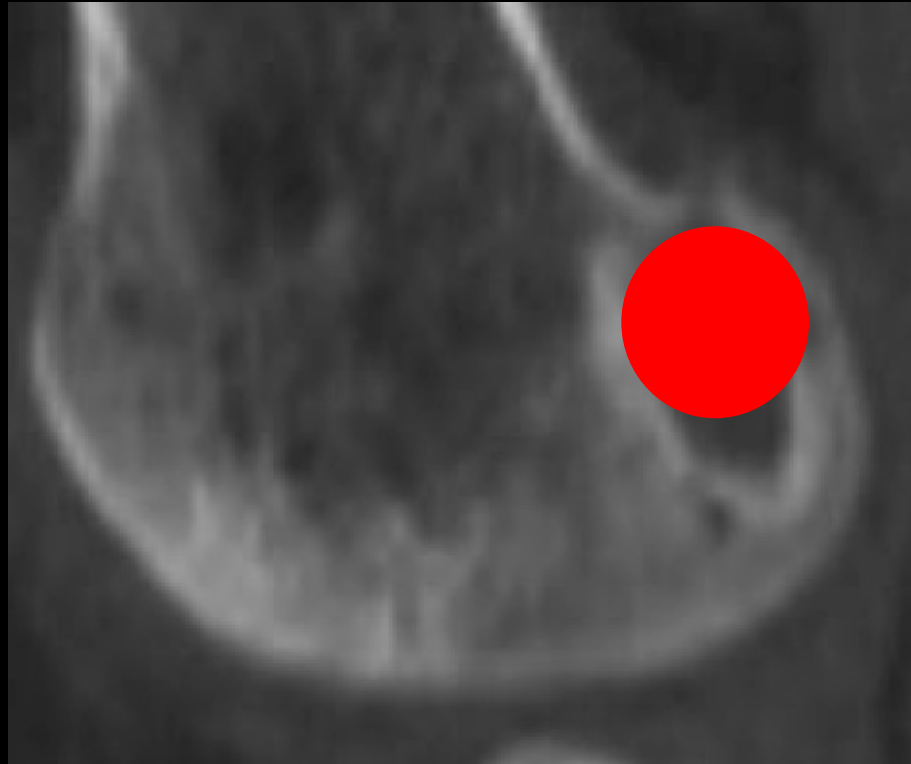
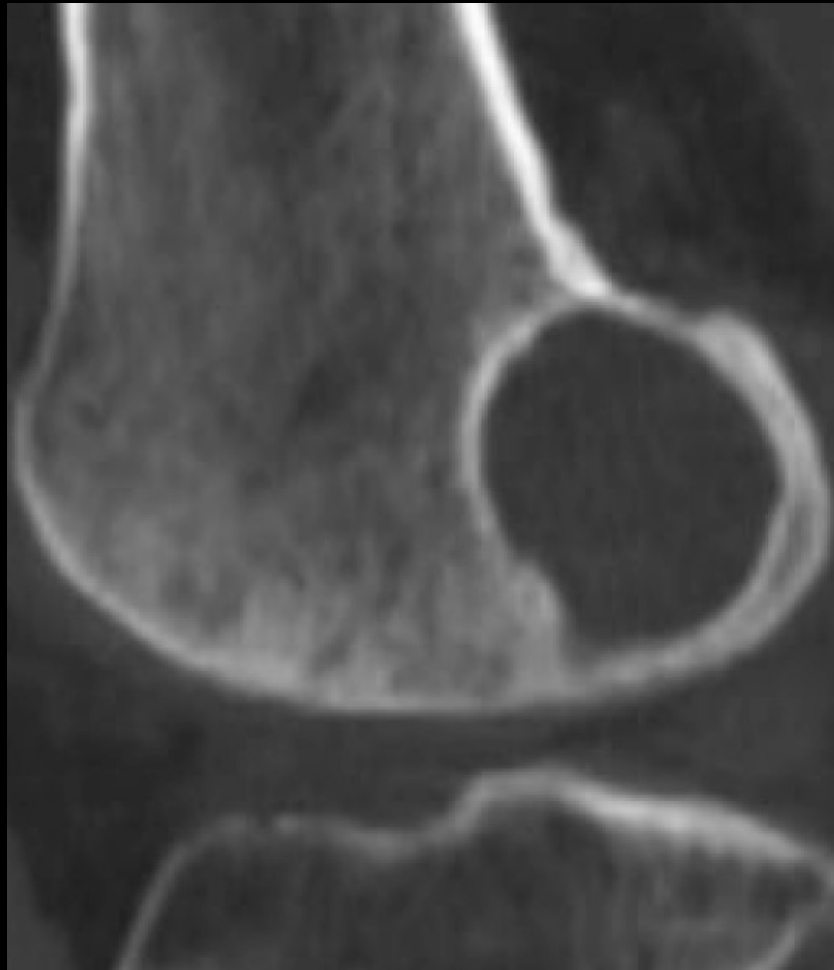
9 CONGRESO CONJUNTO  
**AEA - SEROD**  
9th JOINT AEA-SEROD CONGRESS  
**MURCIA**

  
**ICATME**  
Fundación

*¿De qué alternativas dispongo  
para rellenar los defectos  
óseos?*

***Simone Perelli***

*Hospital del Mar  
ICATME - ICATKNEE  
Barcelona*



# Fillers

## *Two stage*

### Hueso:

Autologo

Banco

Sintetico

Matriz ósea alogénica

### Matrices biomiméticas:

Calcio fosfato

Hidroxiapatita

## *One stage*

### Hueso:

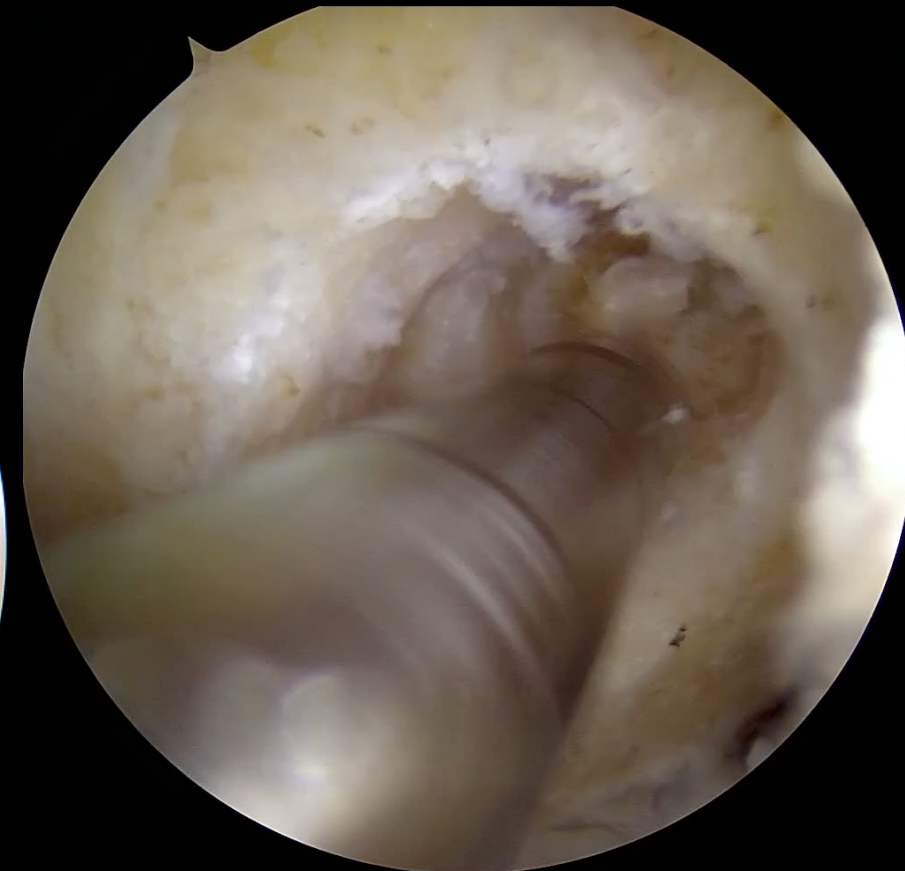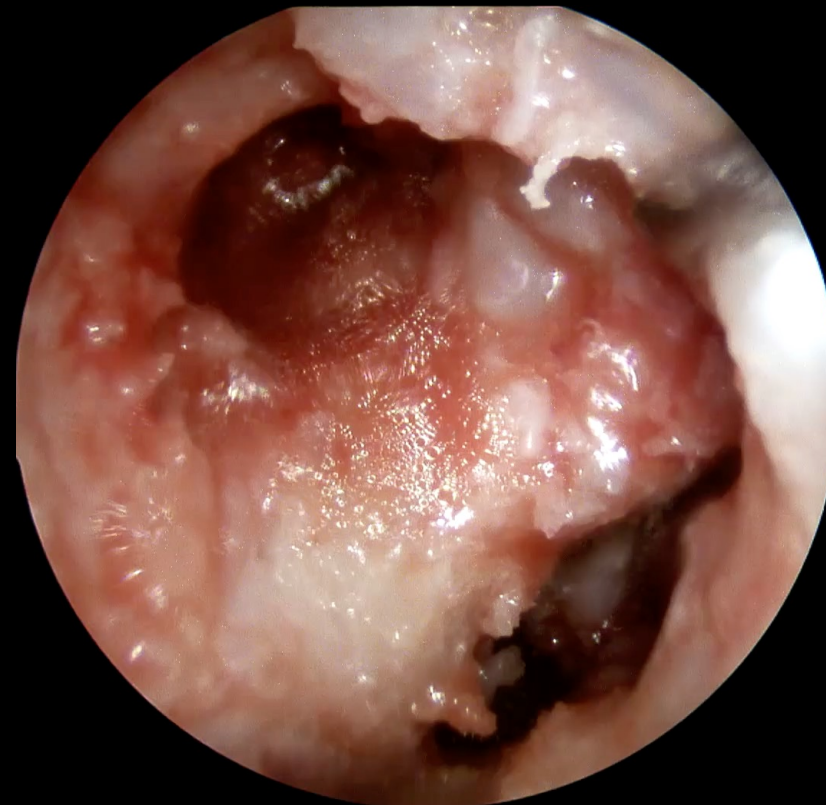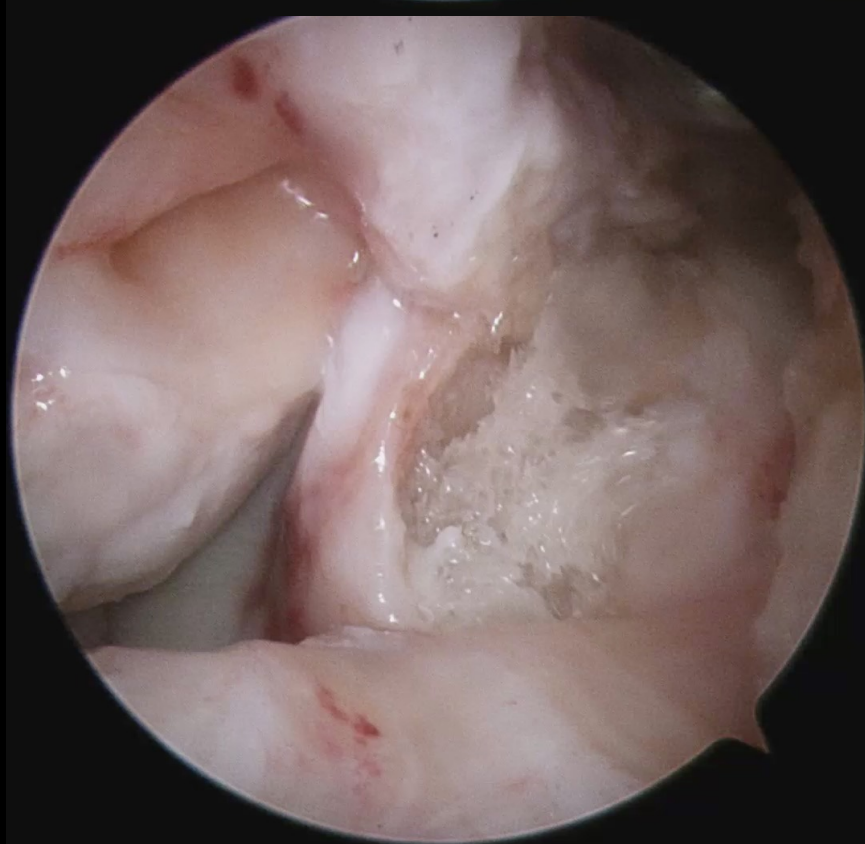
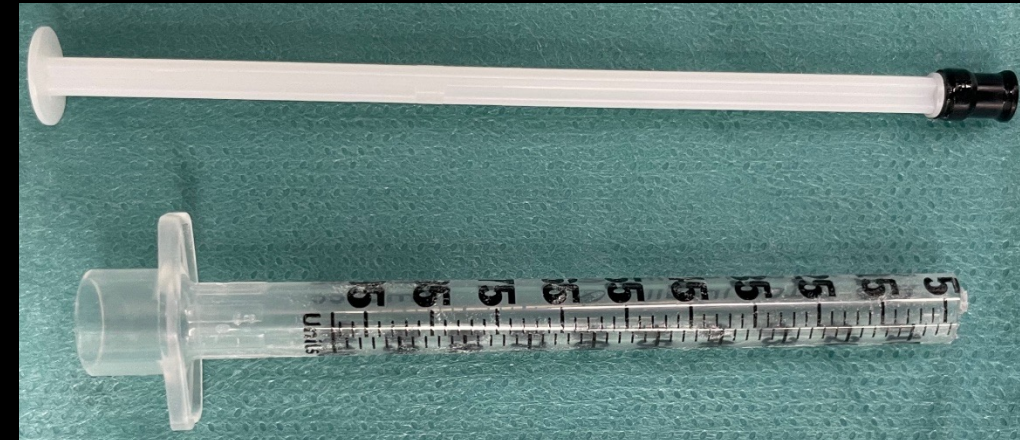
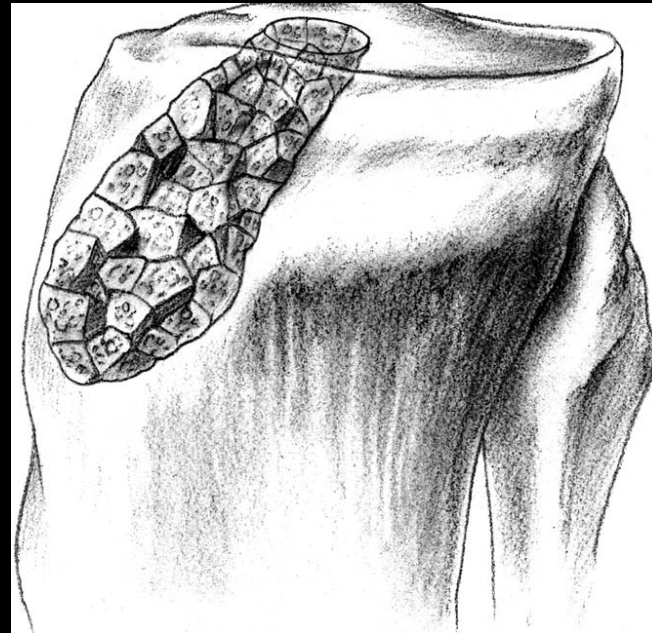
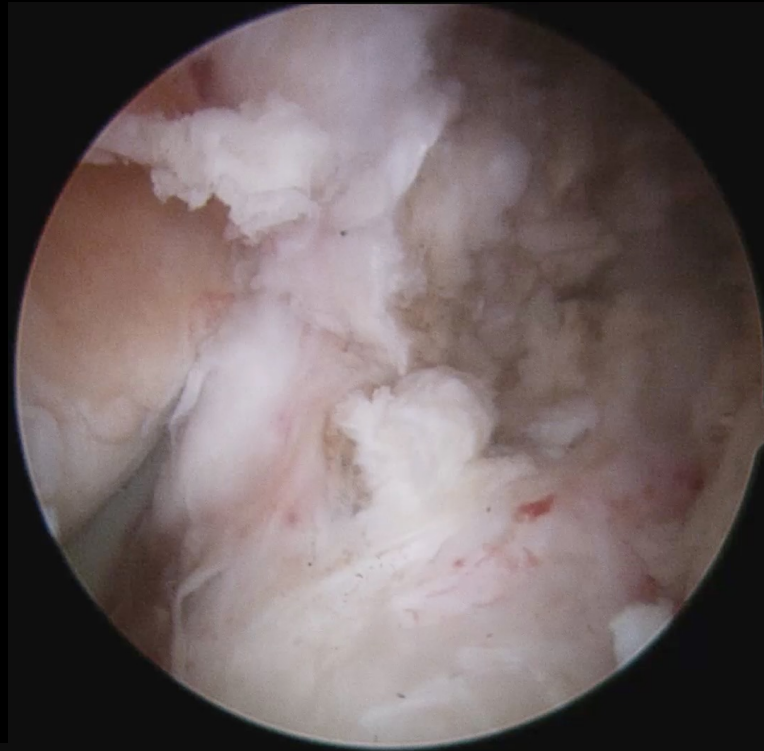Solo estructural

Tornillos interferenciales

Cemento-Hidroxiapatita

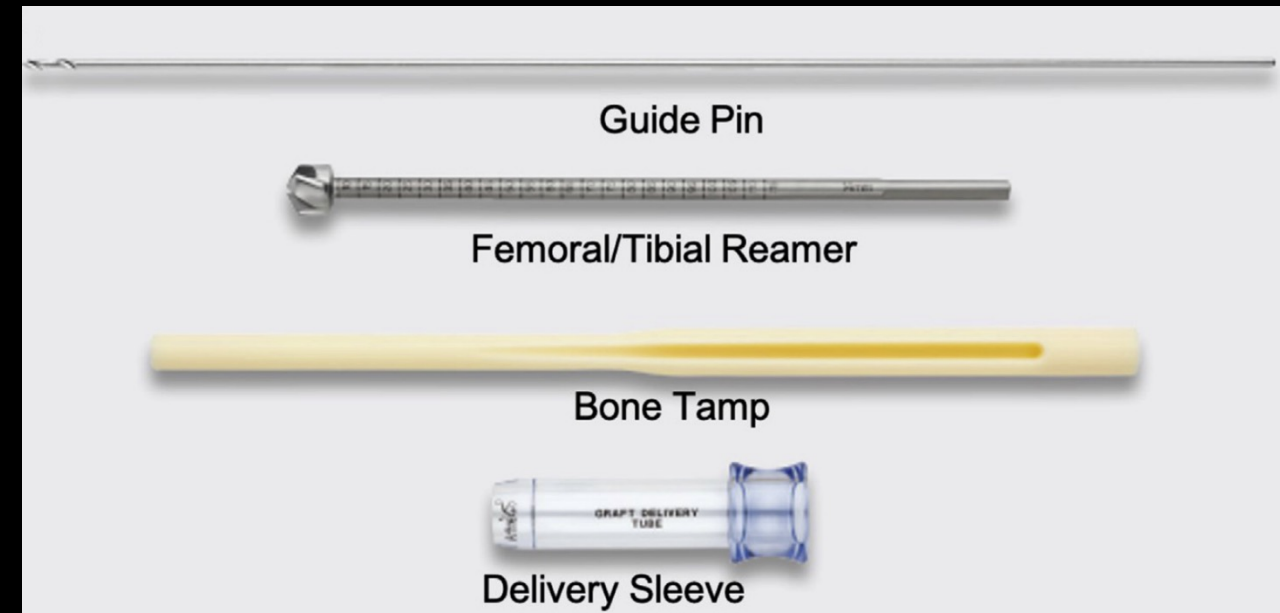
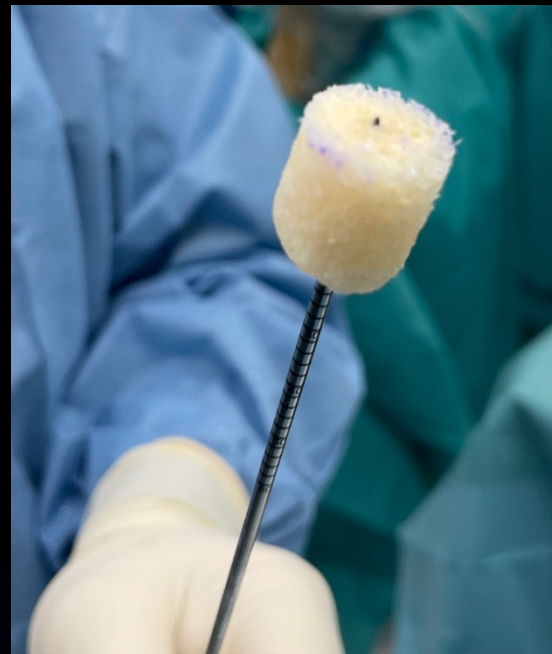
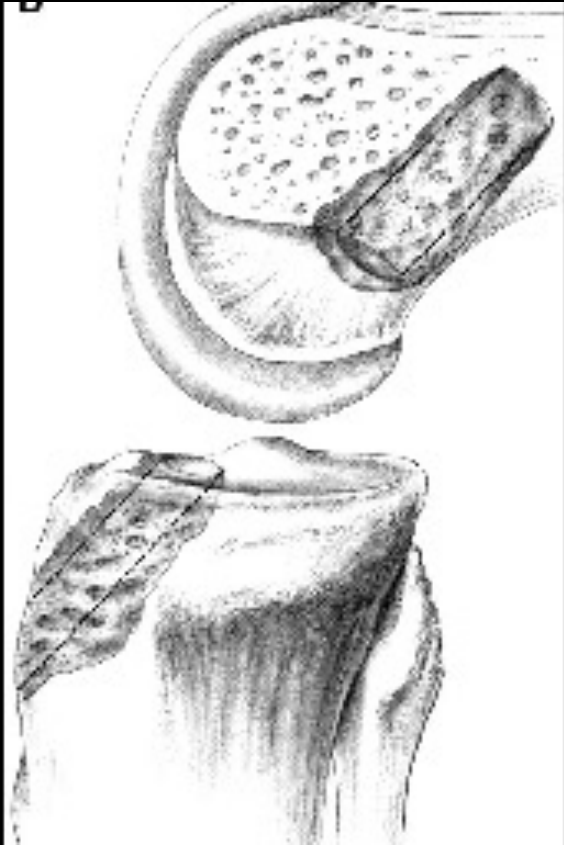


# Fillers: two stage





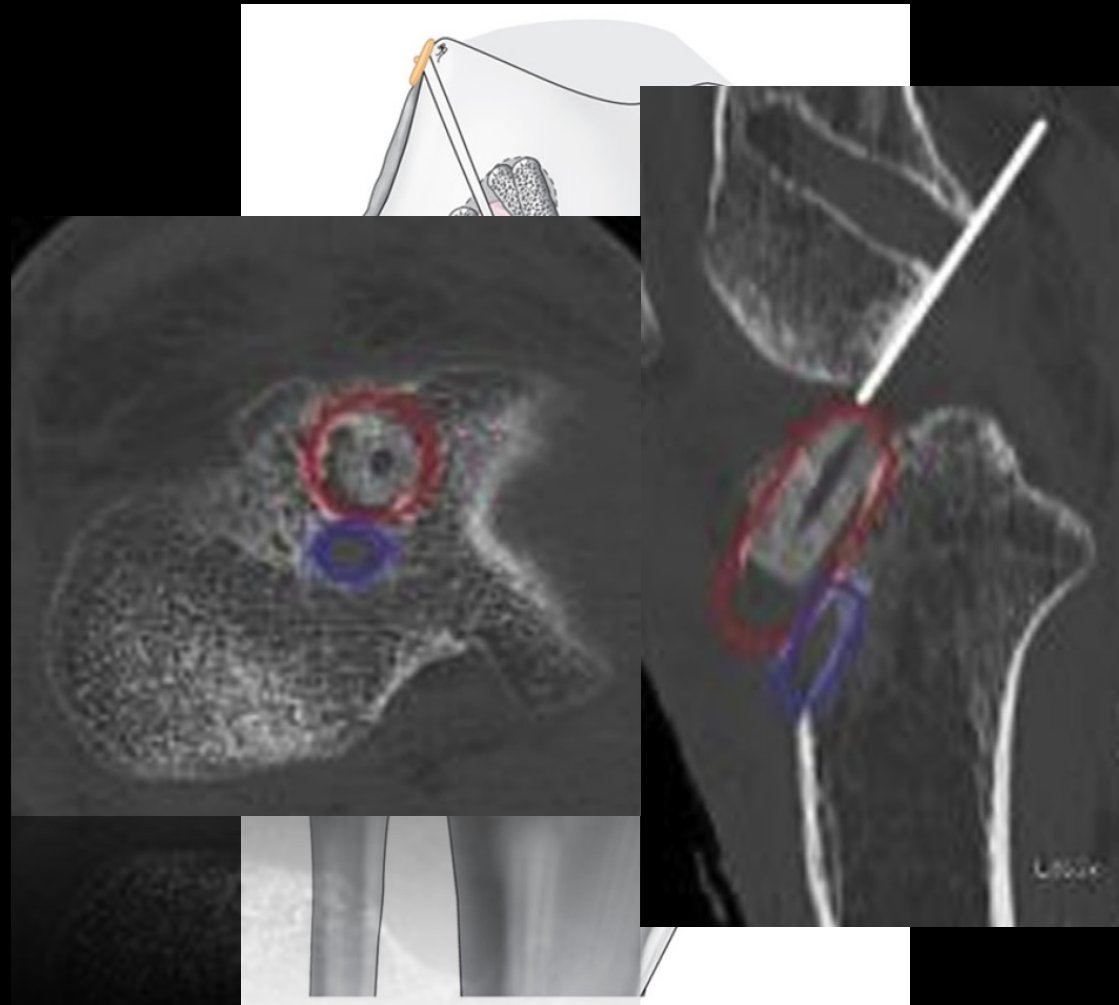
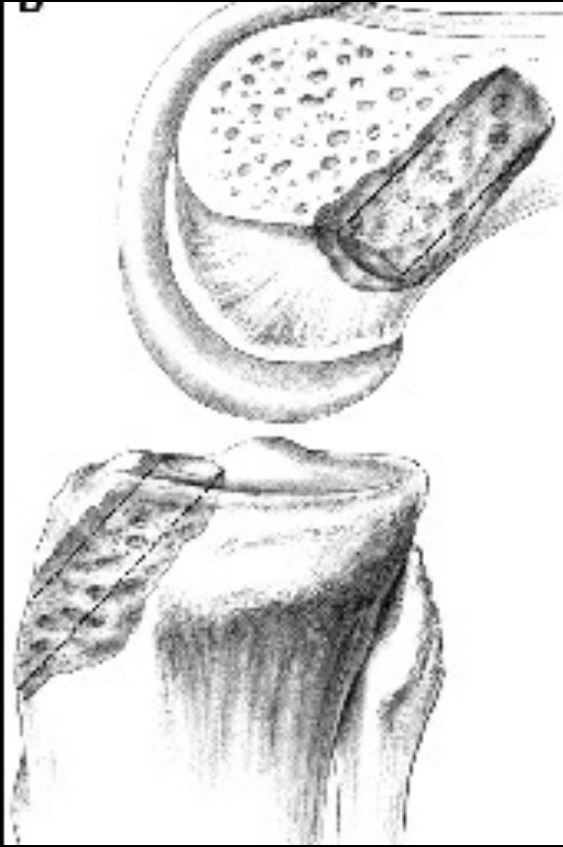
# Fillers: two stage



Two-Stage Revision Anterior Cruciate Ligament Reconstruction with Cannulated Allograft Bone Dowels Soaked in Bone Marrow Aspirate Concentrate

Luc M. Fortier, B.A., Safa Gursoy, M.D., Ph.D., Harsh Singh, BA, and Jorge Chahla, M.D., Ph.D.

# Fillers: one stage

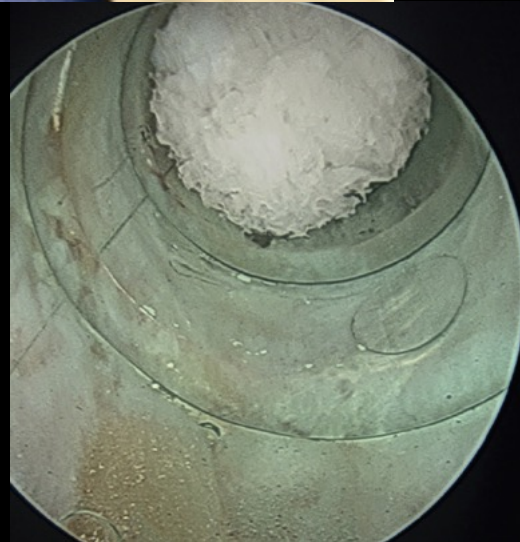
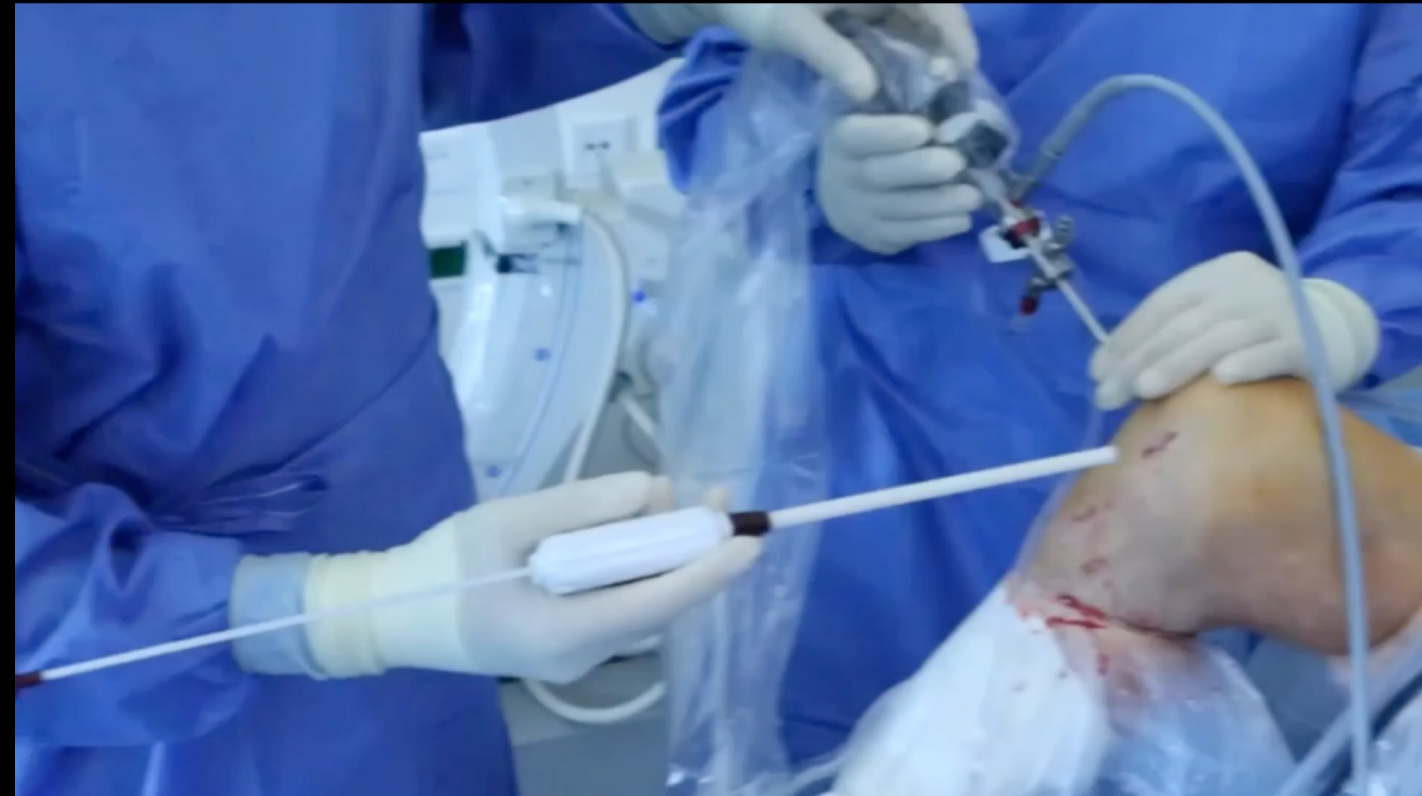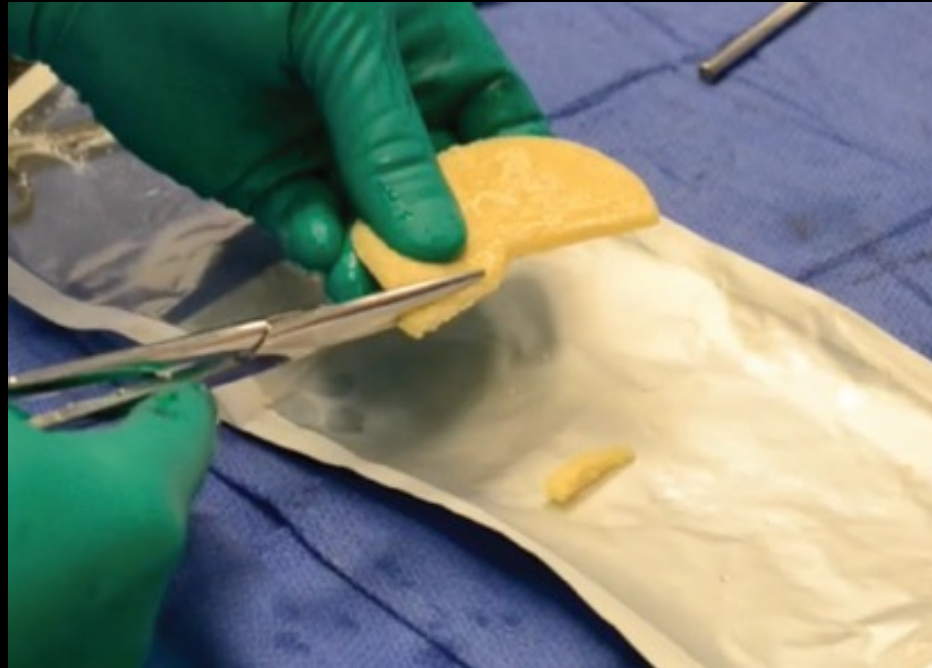


One-Stage ACL Revision Using a Bone Allograft Plug  
for a Semianatomic Tibial Tunnel That Is Too Anterior

Corentin Philippe, M.D., Vincent Marot, M.D., Louis Courtot, M.D.,  
Timothée Mesnier, M.D., Nicolas Reina, M.D., Ph.D., and Etienne Cavaignac, M.D. Ph.D.



# Fillers: two stage



## Two-Stage Revision Anterior Cruciate Ligament Reconstruction: Bone Grafting Technique Using an Allograft Bone Matrix

Jorge Chahla, M.D., Chase S. Dean, M.D., Tyler R. Cram, A.T.C., O.T.C., David Civitarese, B.A., Luke O'Brien, P.T., M.Phty.(Sports), S.C.S., Samuel G. Moulton, B.A., and Robert F. LaPrade, M.D., Ph.D.

## Two-Stage Revision Anterior Cruciate Ligament Reconstruction Using Silicate-Substituted Calcium Phosphate

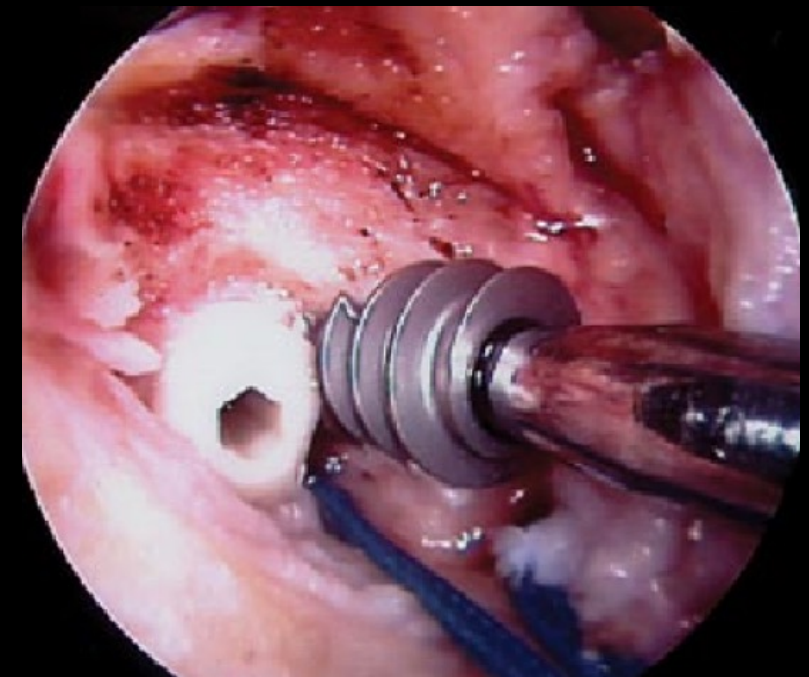
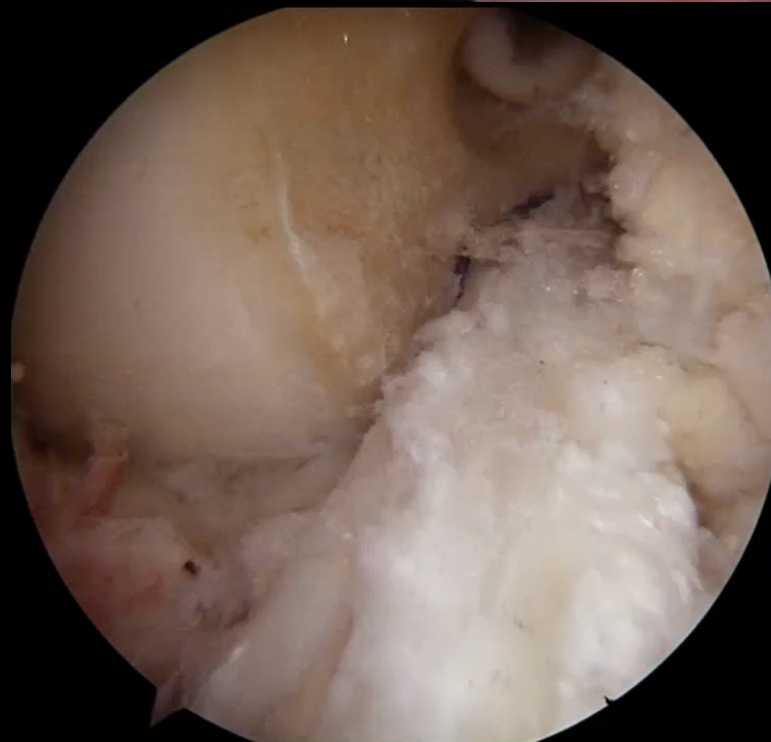
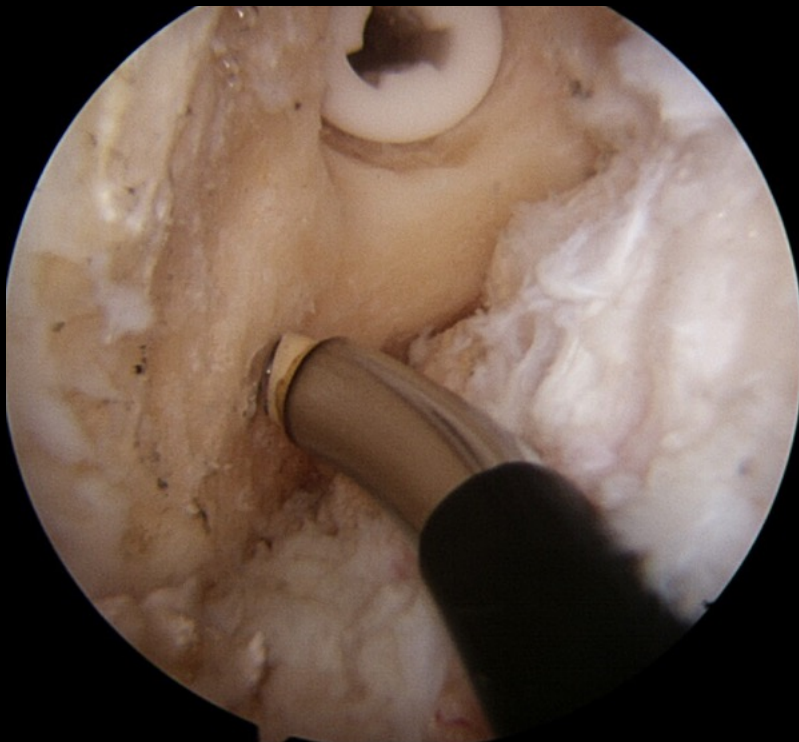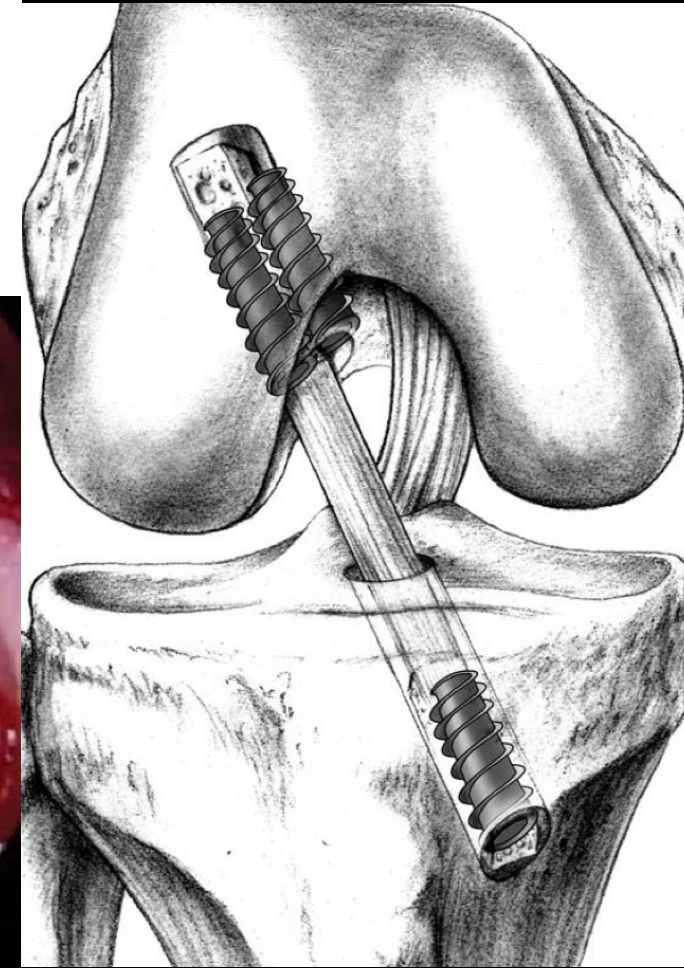
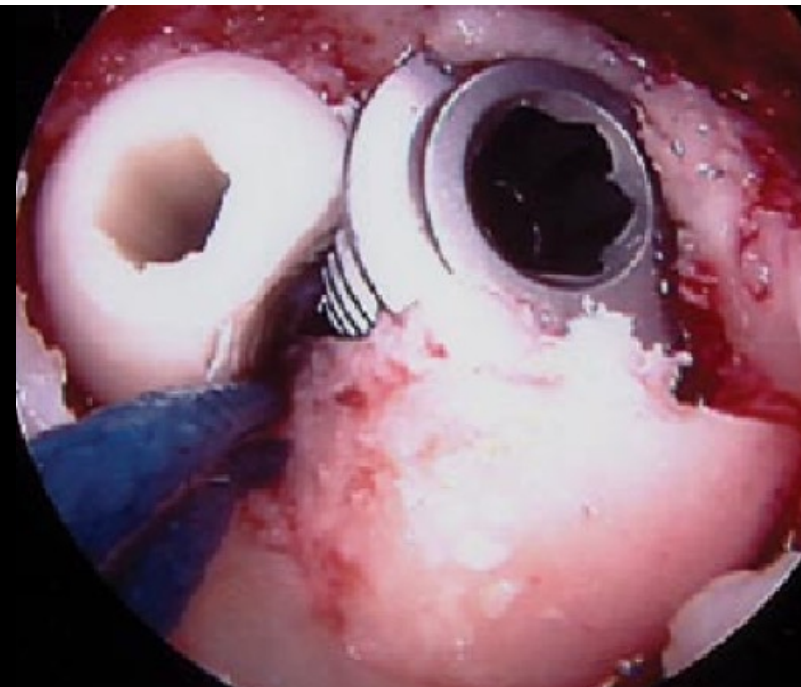
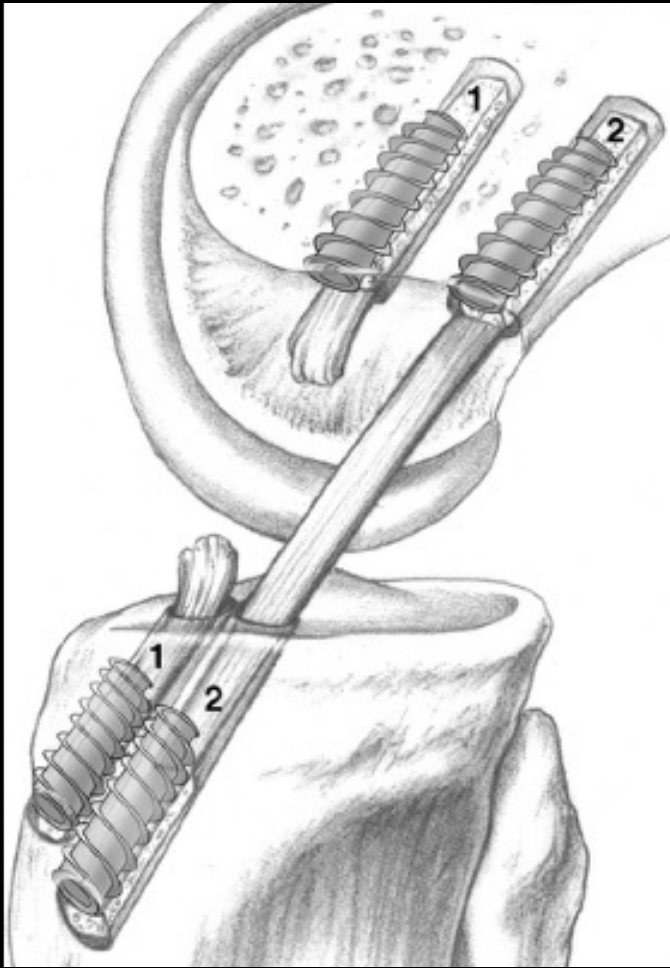
Marc Schnetzke, M.D., Sven Vetter, M.D., Philipp von der Linden, M.D., Paul-Alfred Grützner, M.D., and Jan von Recum, M.D.



# Fillers: one stage

## Revision Anterior Cruciate Ligament Reconstruction Using a Unique Bioabsorbable Interference Screw for Malpositioned Tunnels

Michael Herbenick, MD, and Ralph Gambardella, MD

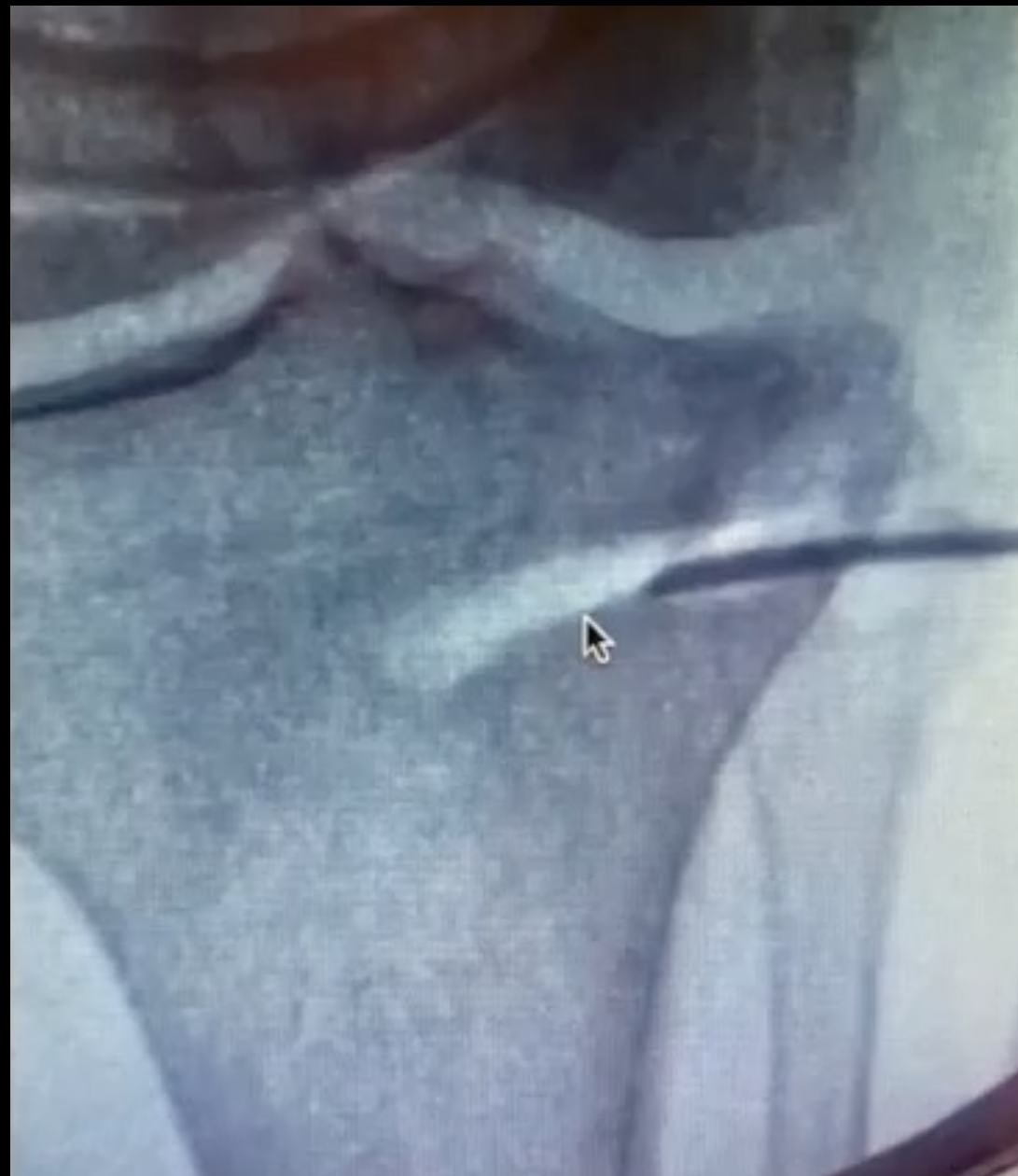

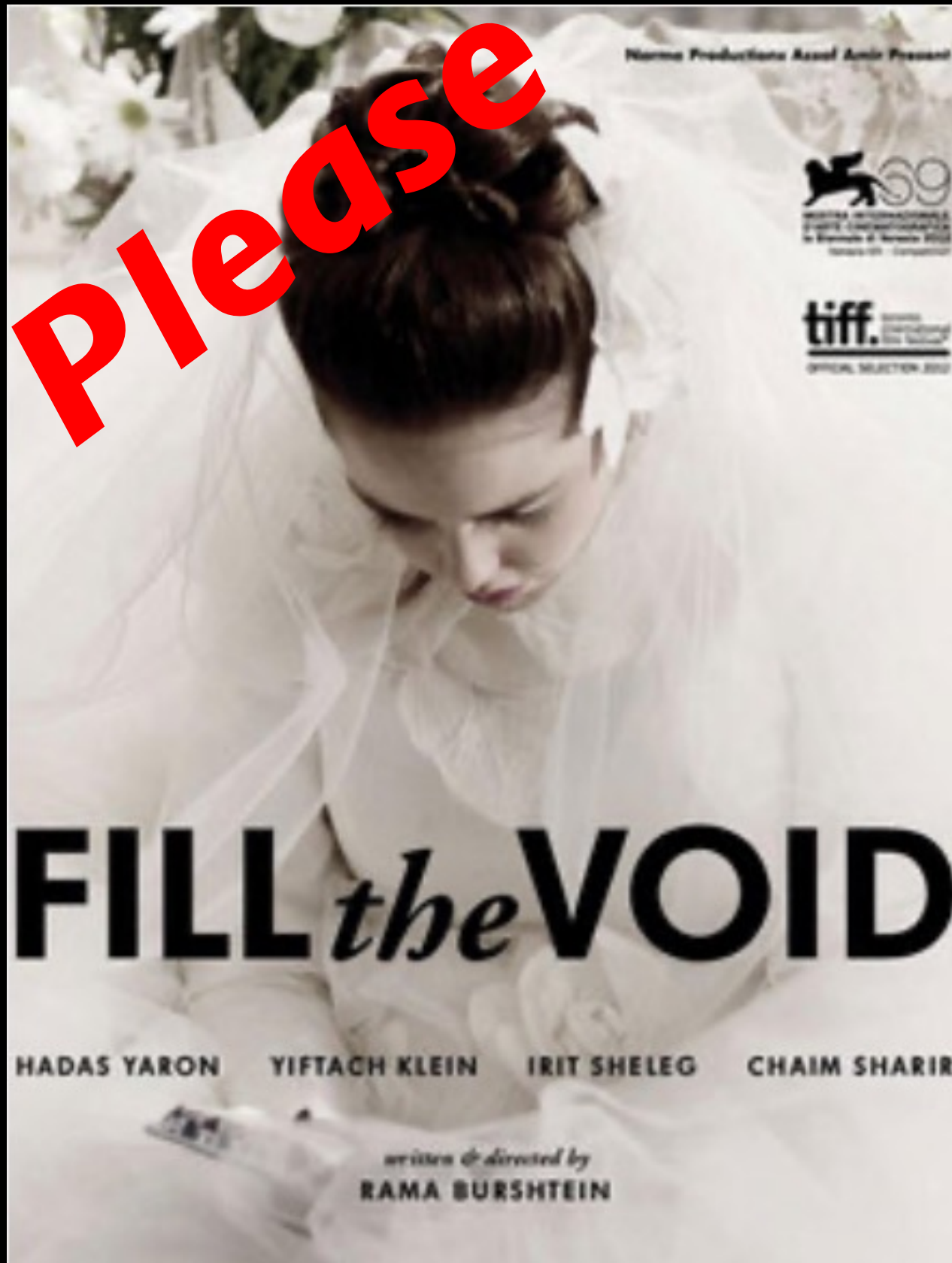


# Fillers: one stage

Evaluation of a one-stage ACL revision Technique using bone void filler after cyclic loading ☆

Brian K. Tse <sup>a</sup>, Zackary D. Vaughn <sup>a</sup>, Derek P. Lindsey <sup>b</sup>, Jason L. Dragoo <sup>a,\*</sup>





[perelli.simone@gmail.com](mailto:perelli.simone@gmail.com)