

One-time ACL revision with bony defect

JOÃO ESPREGUEIRA-MENDES, MD. PhD.

Chairman of Clínica Espregueira - FIFA Medical Centre of Excellence
Chairman and Professor of the Orthopaedic Department - Minho University
2nd Vice-President of the International Society of Arthroscopy, Knee Surgery and Orthopaedic Sports Medicine (ISAKOS)
Board Member of the Patellofemoral Foundation
FIFA Medical Advisory Board FMCE
FC Porto Consultant
President of the European Society of Knee Surgery, Sports Trauma and Arthroscopy (ESSKA) 2012-2014

PORTO, PORTUGAL



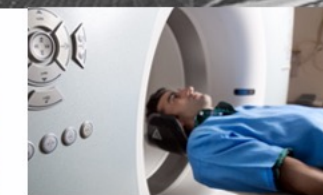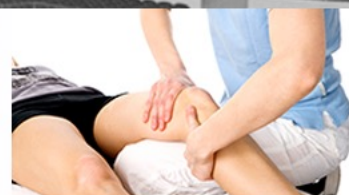ISAKOS
CONGRESS
2023



Boston
Massachusetts
June 18 - June 21

Clínica Espregueira - FIFA Medical Centre of Excellence

FC PORTO STADIUM - PORTO



OFFICIAL CENTER



CONGRESSO AEA - SEROD 2022



DISCLOSURE STATEMENT

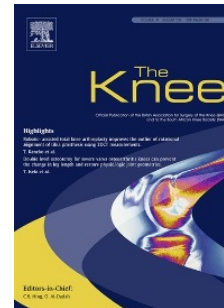
- Second Vice-President of the International Society of Arthroscopy, Knee Surgery and Orthopaedic Sports Medicine (ISAKOS)
- Board Member of the Patellofemoral Foundation
- Inventor of PKTD (no royalties and no fees)
- President of the European Society of Sports Traumatology, Knee Surgery and Arthroscopy (ESSKA and ESSKA Foundation) 2012-2014
- President of the Sociedade Portuguesa de Artroscopia e Traumatologia Desportiva - SPAT 2004-2008
- FIFA Medical Advisory Board FMCE
- Board Trustees of JEO
- Board Trustees of JISAKOS
- Associate Editor of Journal of Cartilage & Joint Preservation
- Porto Award Jury and Sponsor
- Consultant from Episurf Medical
- Consultant from Dawako Medtech SL

RISK FACTORS FOR ACLR REVISION

Scandinavian and American ACL registries

Younger age is the main risk factor for revision ACL reconstruction

- Concomitant MCL injury
- Early surgery (first 12 months)
- Bone morphology
- Smaller graft diameter (risk decreases for every 0.5mm diameter)
- AM portal drilling technique
- Hamstring autograft
- Allografts
- Suspensory fixation
- Male sex
- Lower BMI
- Lower KOOS



> [Knee](#). 2020 Mar;27(2):287-299. doi: 10.1016/j.knee.2019.12.003. Epub 2020 Jan 31.

Factors associated with revision following anterior cruciate ligament reconstruction: A systematic review of registry data

Richard Rahardja¹, Mark Zhu², Hamish Love³, Mark G Clatworthy⁴, Andrew Paul Monk², Simon W Young⁵

BONE MORPHOLOGY - PORTO RATIO

KSSTA
Knee Surgery
Sports Traumatology
Arthroscopy

Knee Surg Sports Traumatol Arthrosc
DOI 10.1007/s00167-016-4159-1

KNEE

Is the femoral lateral condyle's bone morphology the trochlea of the ACL?

Margarida Sá Fernandes^{1,2} · Rogério Pereira^{3,4,5} · Renato Andrade^{4,5,6} · Sebastiano Vasta⁷ · Hélder Pereira^{4,5,8,9,10} · João Páscoa Pinheiro¹¹ · João Espregueira-Mendes^{4,5,9,10,12}

2017

KSSTA
Knee Surgery
Sports Traumatology
Arthroscopy

Knee Surgery, Sports Traumatology, Arthroscopy (2018) 26:2817–2825
<https://doi.org/10.1007/s00167-017-4761-x>

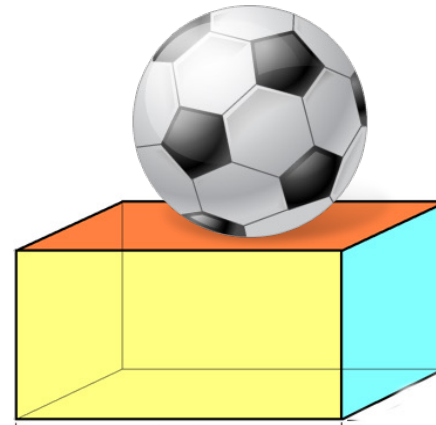
KNEE

Bone morphology and morphometry of the lateral femoral condyle is a risk factor for ACL injury

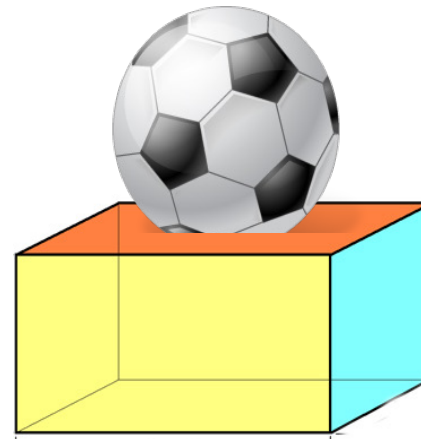
Sebastiano Vasta¹ · Renato Andrade^{2,3,4} · Rogério Pereira^{2,3,4,5} · Ricardo Bastos^{2,4,6} · Antonino Giulio Battaglia⁷ · Rocco Papalia⁸ · João Espregueira-Mendes^{2,4,8,9,10}

2018

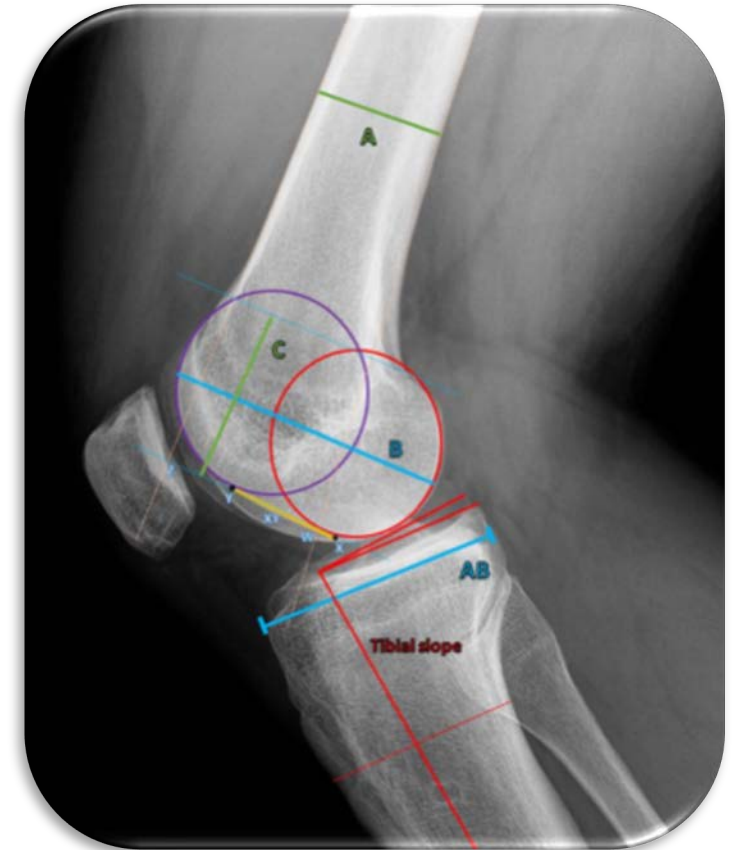
“Bone morphology of the external femoral & tibial condyles are the trochlea of the ACL”



MORE UNSTABLE



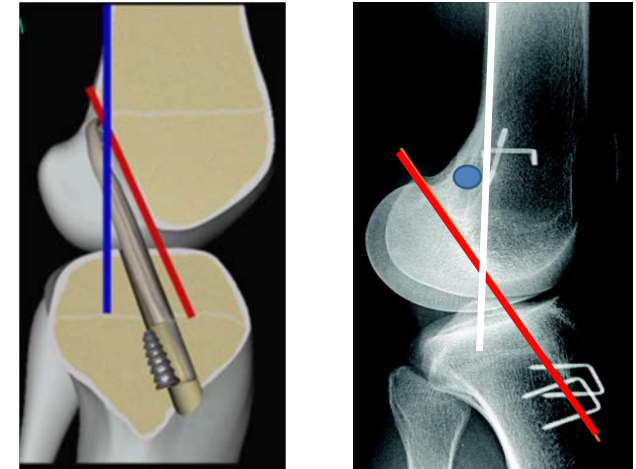
MORE STABLE



X-Ray

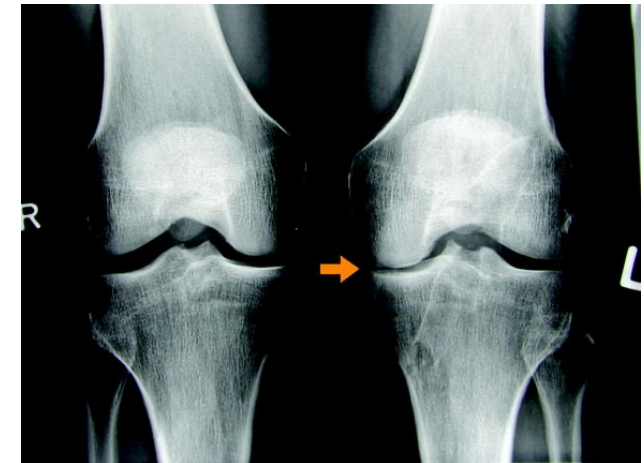
Lateral view in hiperextension

- Hardware
- Tunnels Placement (sagittal plane)



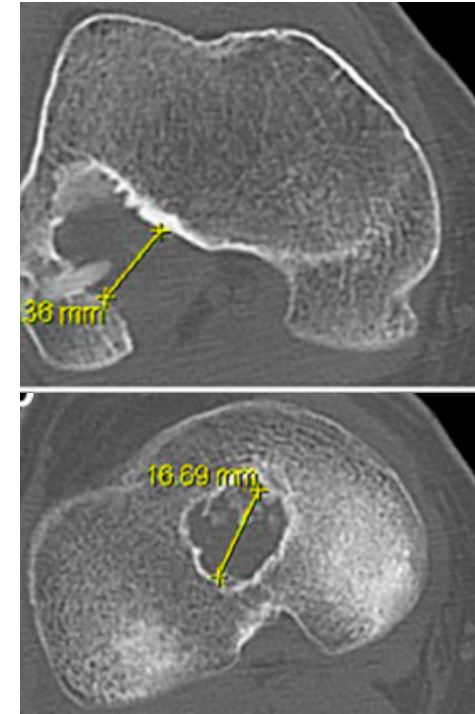
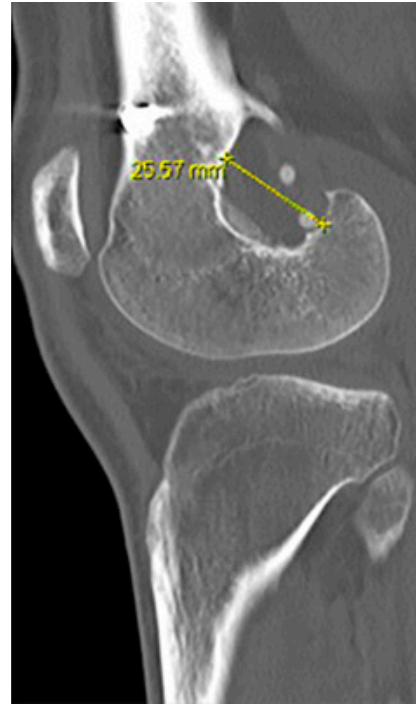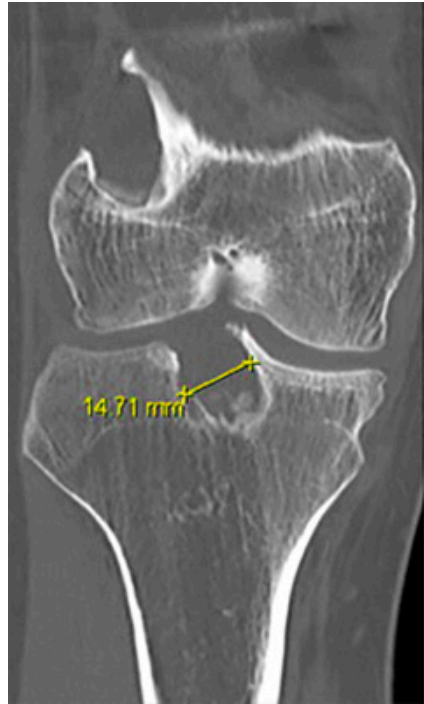
Rosemberg view

- Hardware
- Tibial Tunnel placement (coronal plane)
Posterior to Blumensat line
- Notch configuration
- Axis




CT SCAN

TUNNEL ENLARGEMENT AND BONE LOSS



MRI

GRAFT INTEGRITY, POSITION & TUNNELS REABSORPTION




[Anterior Cruciate Ligament Reconstruction](#) pp 367-386 | [Cite as](#)

Systematic Approach from Porto School

Authors [Authors and affiliations](#)

Hélder Pereira [✉](#), Nuno Seivas, Rogério Pereira, Alberto Monteiro, Ricardo Sampaio, Joaquim Miguel Oliveira, Rui Luís Reis, João Espregueira-Mendes

First Online: 20 March 2014



[Anterior Cruciate Ligament Reconstruction](#) pp 407-417 | [Cite as](#)

ACL Two-Stage Revision Surgery: Practical Guide

Authors [Authors and affiliations](#)


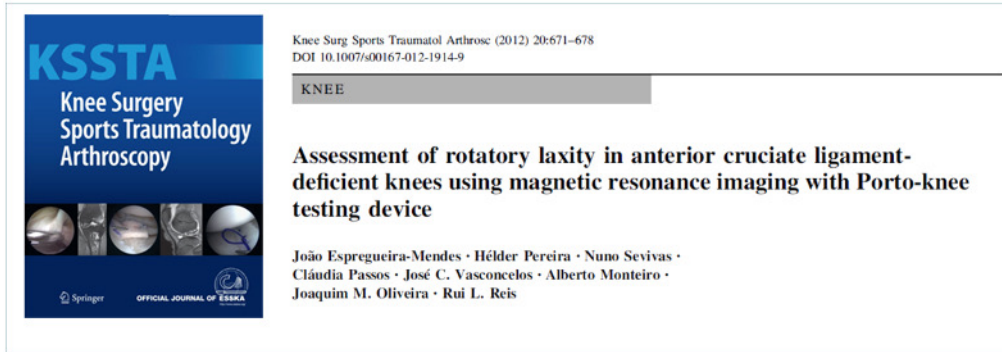
João Espregueira-Mendes, Hélder Pereira [✉](#), Alberto Monteiro, Joaquim Miguel Oliveira, Rui Luís Reis, Pedro Luís Ripóll, Neil Thomas

First Online: 20 March 2014

Evaluate:

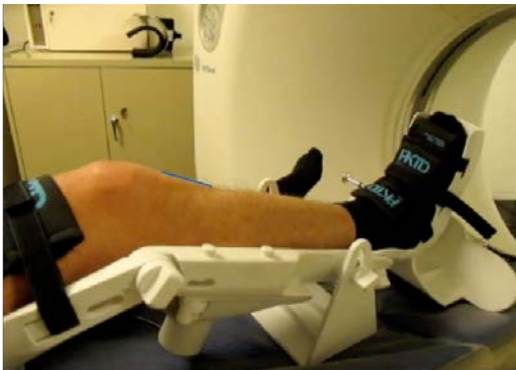
- Cyclops
- Meniscus
- Cartilage
- Bone bruise
- Other ligaments
- Partial ruptures
- Objective evaluation of instability

RESIDUAL LAXITY - PKTD

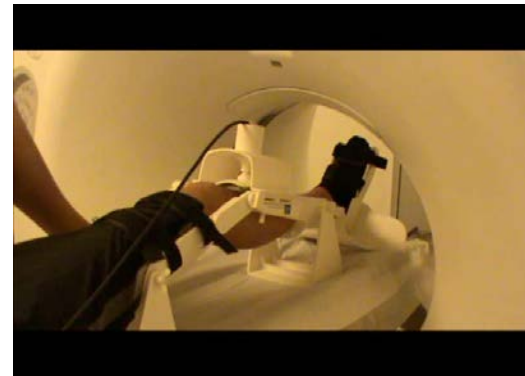

360° evaluation

- PCL
- PLC
- ALC
- PMC
- AMC



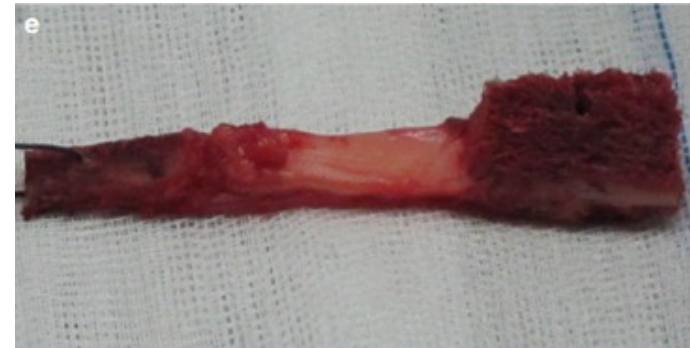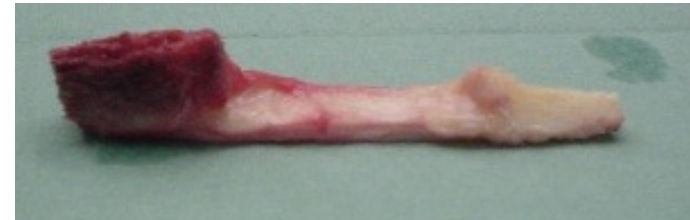PKTD with rotation - ACL




PKTD with rotation - PCL,
PLC & PMC

GRAFT CHOICE DEPENDS:

- Tunnels size increase & bone loss
- Patella bone loss (donor site)
- Previous graft:
 - BPTB ipsi (prev. HS)
 - BPTB contra-lateral (prev. BPTB)
 - QTendon
 - Allograft




LARGE TIBIAL BONE LOSSES



[Anterior Cruciate Ligament Reconstruction](#) pp 367-386 | [Cite as](#)

Systematic Approach from Porto School

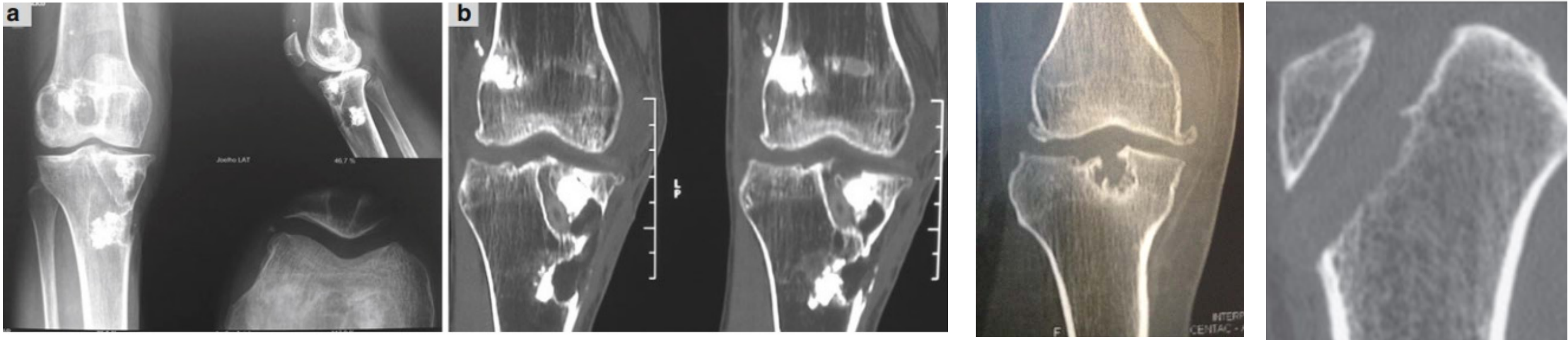
Authors Authors and affiliations

Hélder Pereira , Nuno Seivas, Rogério Pereira, Alberto Monteiro, Ricardo Sampaio, Joaquim Miguel Oliveira,


Rui Luís Reis, João Espregueira-Mendes

First Online: 20 March 2014

Needs large graft bone block?



LARGE TIBIAL BONE LOSS



[Anterior Cruciate Ligament Reconstruction](#) pp 367-386 | [Cite as](#)

Systematic Approach from Porto School

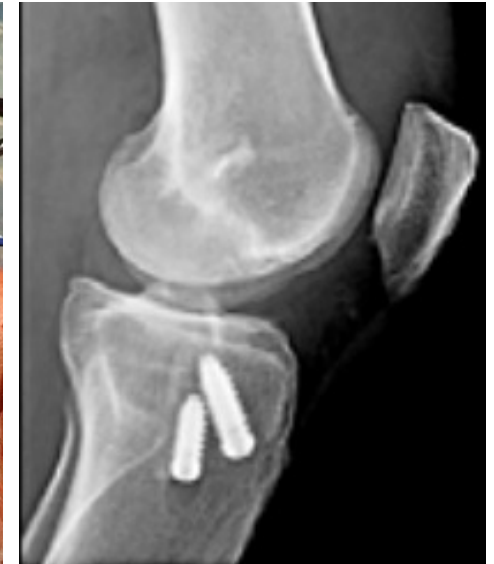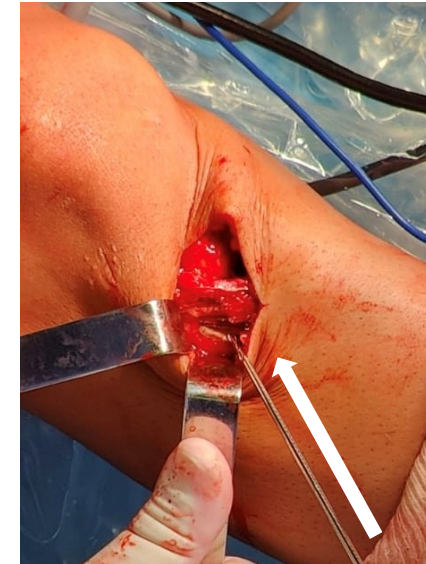Authors [Authors and affiliations](#)

Hélder Pereira [✉](#), Nuno Sevivas, Rogério Pereira, Alberto Monteiro, Ricardo Sampaio, Joaquim Miguel Oliveira, Rui Luís Reis, João Espregueira-Mendes

First Online: 20 March 2014

1. Large graft bone block from the tibial side
2. Larger tibial screw (or 2 screws)
3. Lateral approach for the tibial tunnel (divergent tunnels)

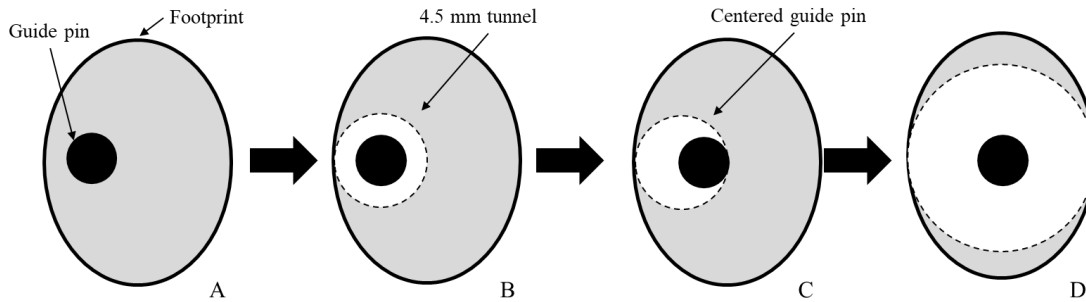
Do not remove hardware, except if it is on the way!



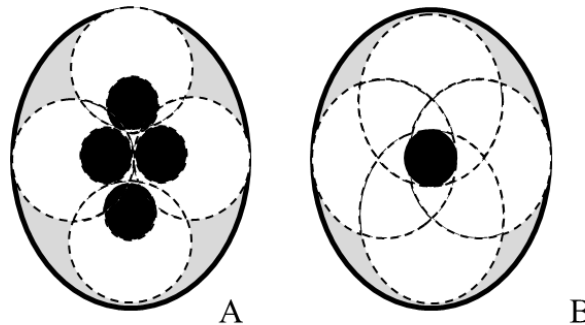
OVERDRILL TO CENTRALIZE NEW GRAFT

- Overdrill to place the graft isometrically and then fill with large screws

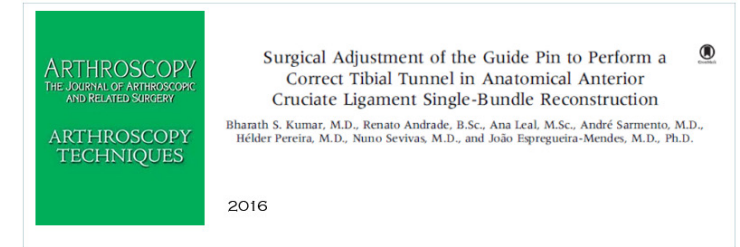

Overdrill around the desired graft placement



You can overdrill for any graft placement (360°)



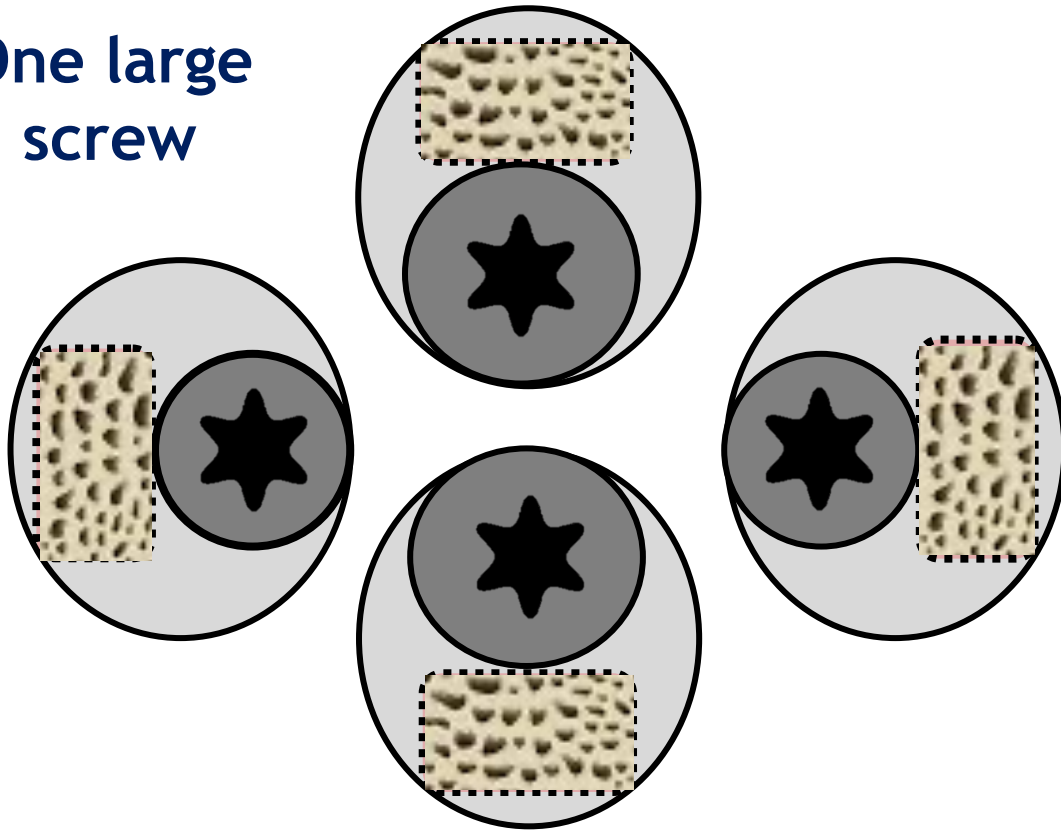
Insert large graft with large screw



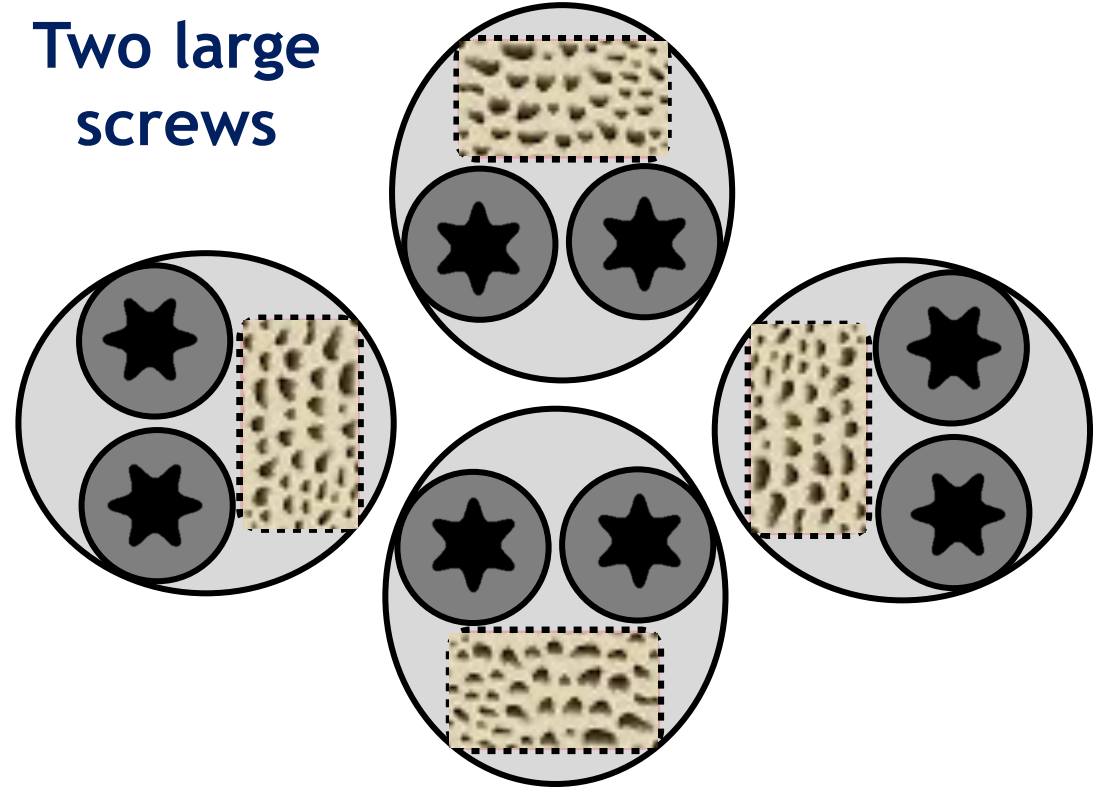
LARGE TIBIAL TUNNEL

- Cover (306°) with large bone-tendon graft + large screw(s)


One large screw



Two large screws



LARGE FEMUR BONE LOSS



[Anterior Cruciate Ligament Reconstruction](#) pp 367-386 | [Cite as](#)

Systematic Approach from Porto School

Authors Authors and affiliations

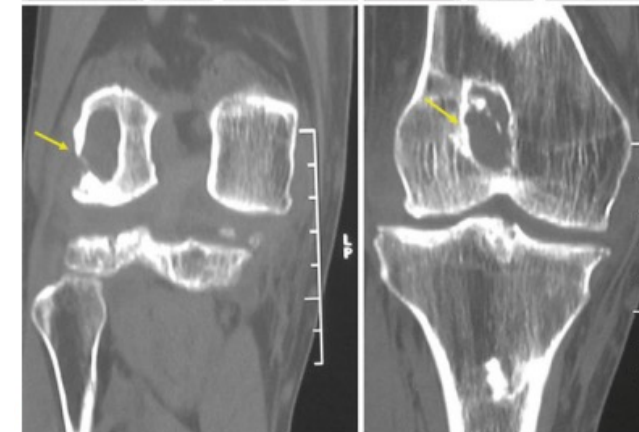
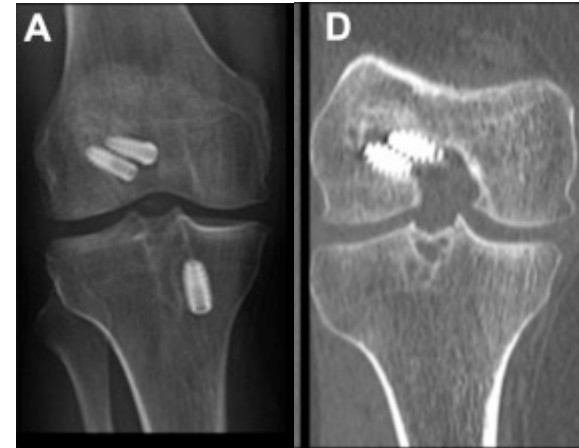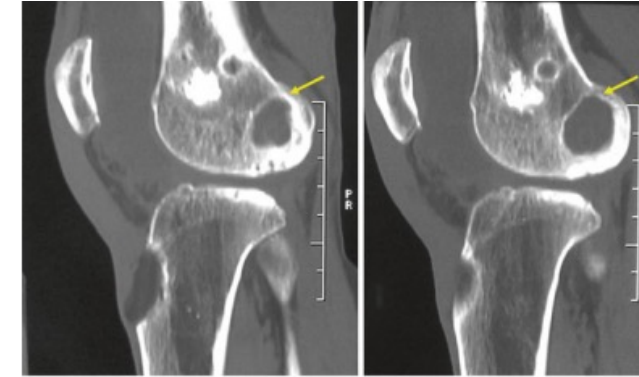
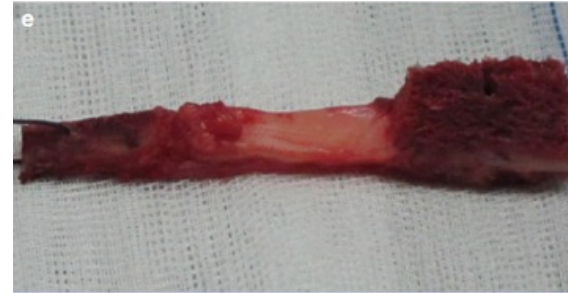Hélder Pereira ✉, Nuno Seivas, Rogério Pereira, Alberto Monteiro, Ricardo Sampaio, Joaquim Miguel Oliveira,

Rui Luís Reis, João Espregueira-Mendes

First Online: 20 March 2014

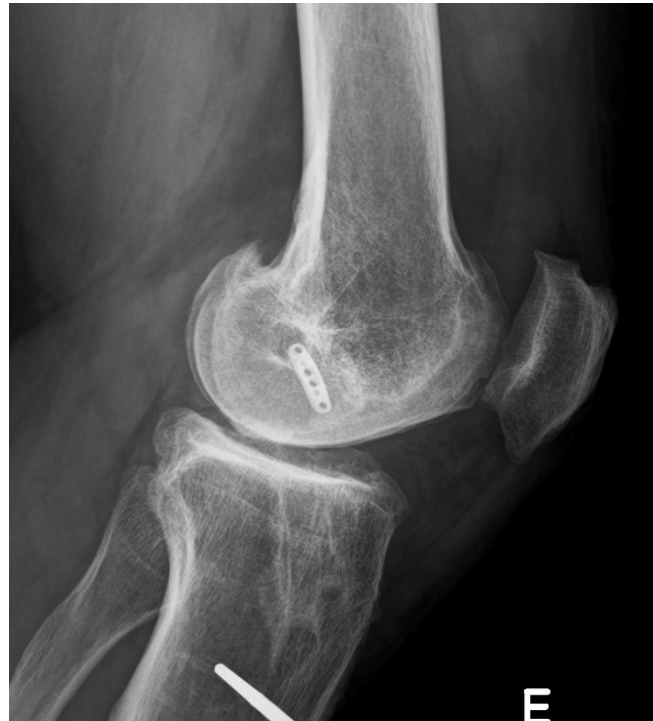
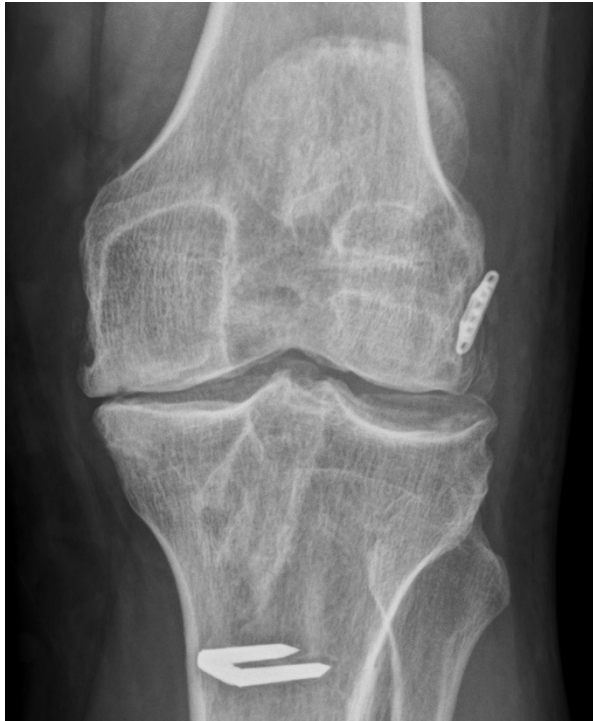1. Large graft bone block from the tibial side
2. Larger femoral screw
3. Outside-in (or vice-versa) - divergent tunnels
4. Over-the-top

Do not remove hardware except if it is on the way!



LARGE FEMORAL TUNNEL

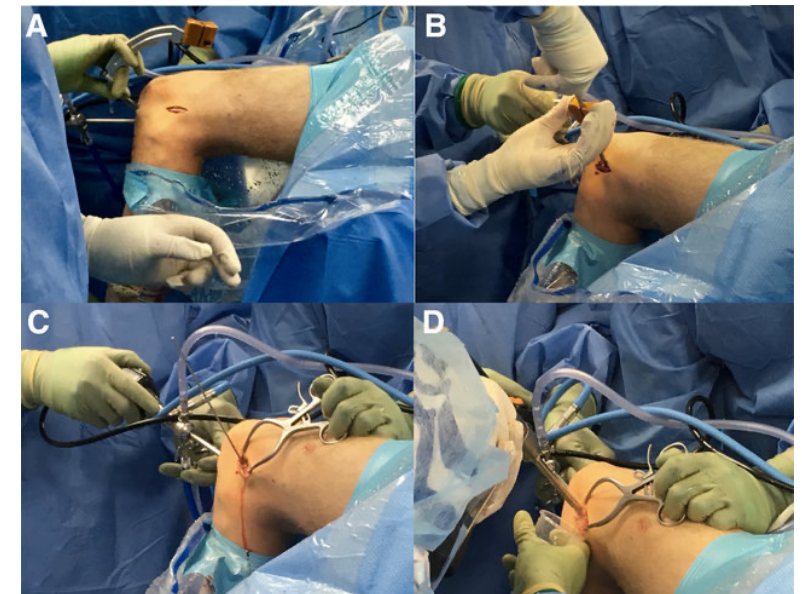
- Outside-in technique



Anatomic Femoral and Tibial Tunnel Placement During Anterior Cruciate Ligament Reconstruction: Anteromedial Portal All-Inside and Outside-In Techniques

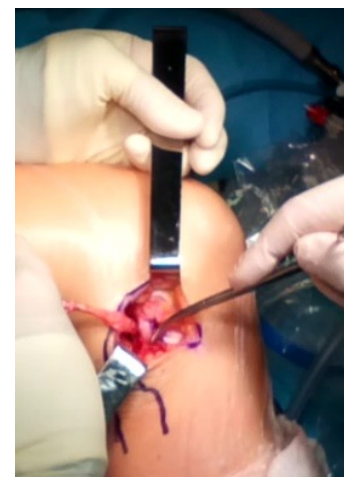
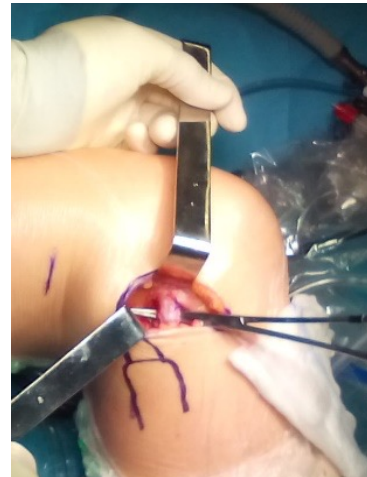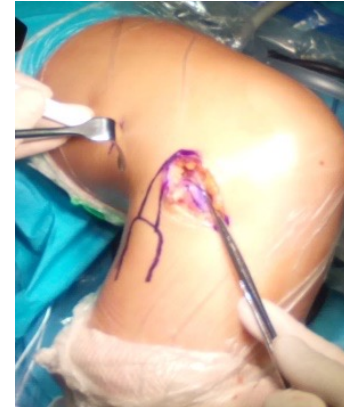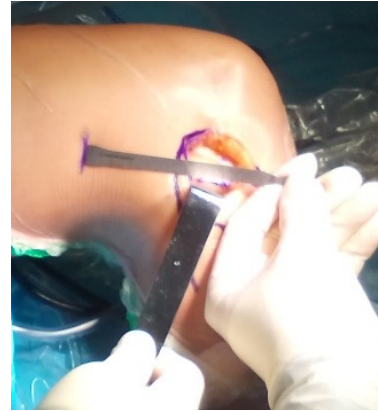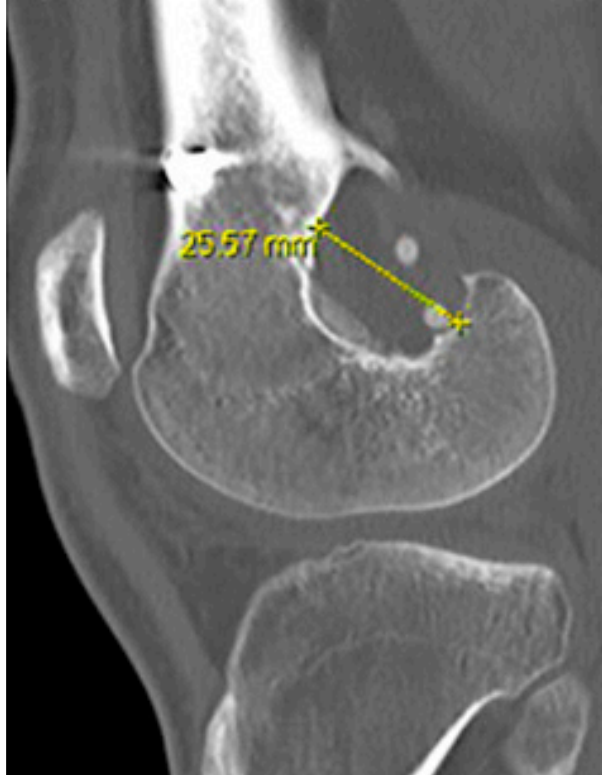Jeremy M. Burnham, M.D., Chaitu S. Malempati, D.O., Aaron Carpioux, M.D., Mary Lloyd Ireland, M.D., and Darren L. Johnson, M.D.

2017



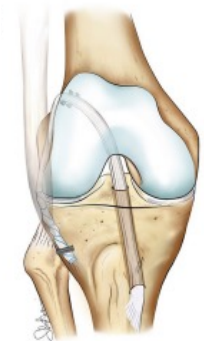
VERY LARGE FEMORAL TUNNEL

- Over-the-top technique + LEAT (mini-Lemaire)

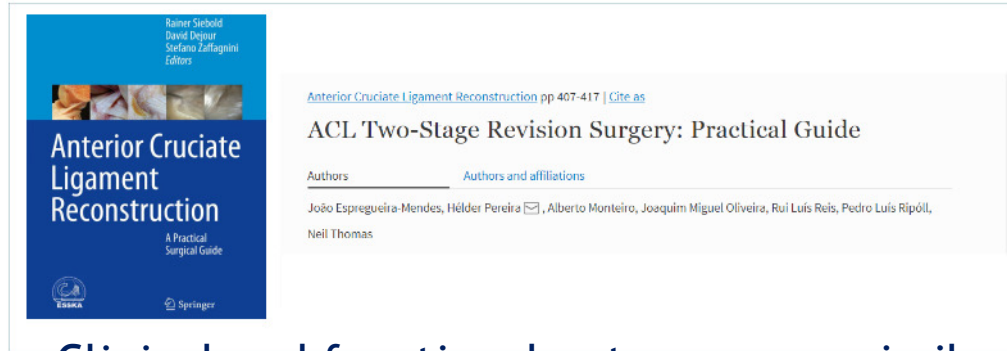

Over-the-top ACL
Reconstruction Plus Extra-
articular Lateral Tenodesis With
Hamstring Tendon Grafts:
Prospective Evaluation With
20-Year Minimum Follow-up

Stefano Zaffagnini et al. Am J Sports Med.
2017 Dec.



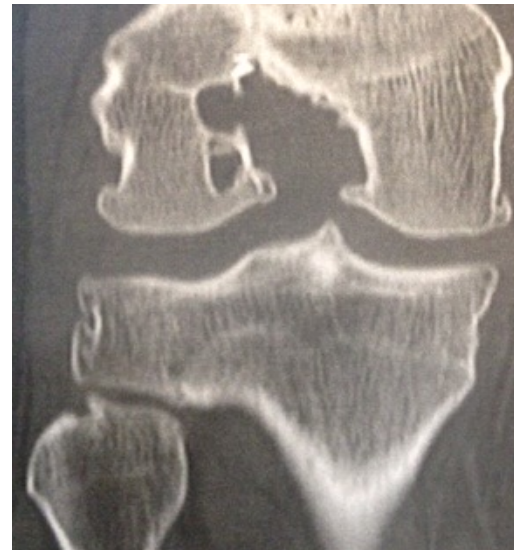TWO-STEPS REVISION



- Clinical and functional outcomes are similar between one-step and two-step ACL revision, without notable differences in failure rates.

EXCEPTIONAL for us! (8/9% Mars group)

- VERY LARGE BONE DEFECTS
- SEVERE LOSS OF MOTION
- BORDERLINE INDICATIONS FOR REVISION
- INFECTION?



Mitchell et al. (2017) AJSM 45(8):1790-1798

Mathew et al. (2018) JISAKOS 3(6):345-351

!



ISAKOS
REGIONAL
MEETING

VIÑA DEL MAR
CHILE
October 20-21
2022



ISAKOS KNEE ARTHROPLASTY FORUM

SAVE THE DATE
OCTOBER 20 - 21, 2022

**Sheraton Miramar Hotel
& Convention Center**
Viña del Mar, CHILE

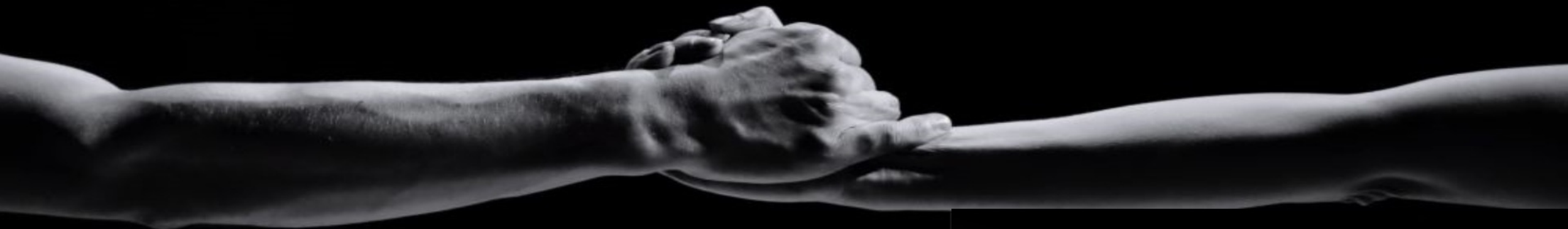
 **clínica
espregueira**

FIFA | MEDICAL CENTRE
OF EXCELLENCE



Official Teaching Centre

ICRS
International Cartilage Regeneration
& Joint Preservation Society



**ACADEMIA
CLÍNICA
DO DRAGÃO**

**FOOTBALL MEDICINE
ADVANCED COURSE**

9-11 March 2023
At FC Porto Stadium

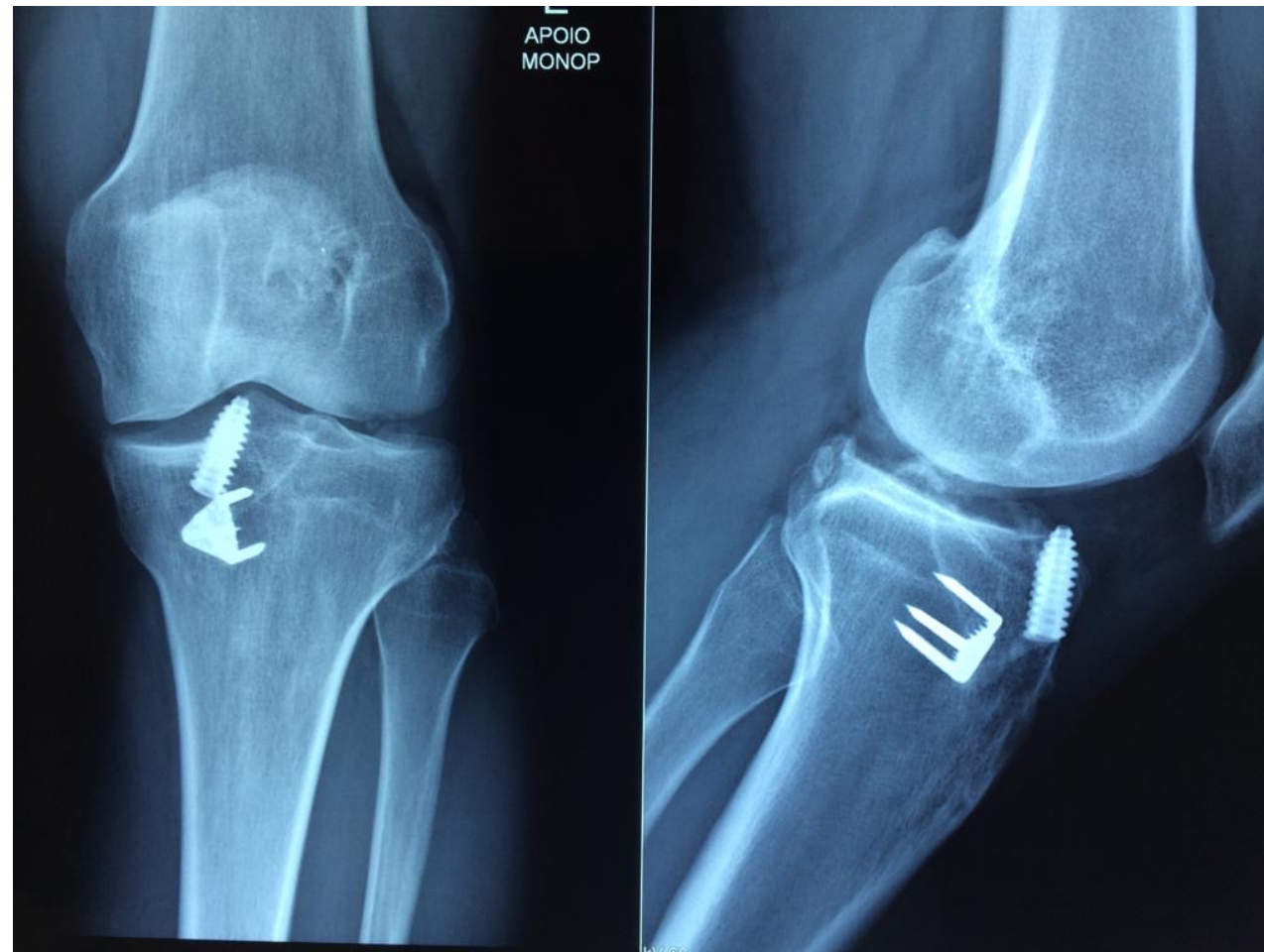


**ISAKOS
CONGRESS
2023**

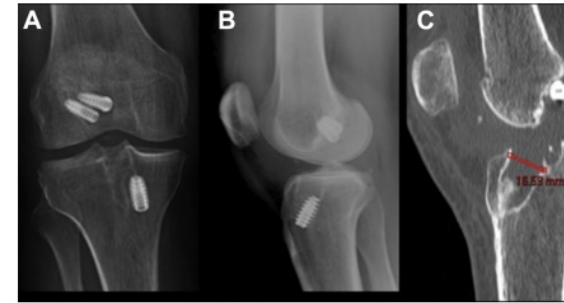


Boston
Massachusetts
June 18-June 21

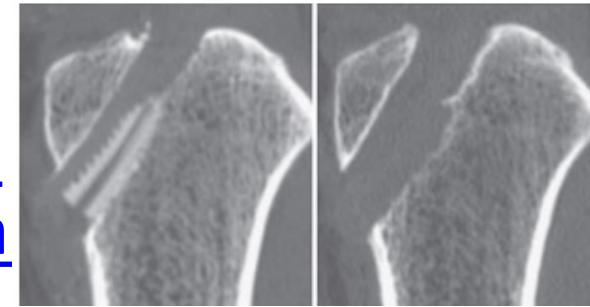
- Esta imagem que o Professor me enviou é para usar?



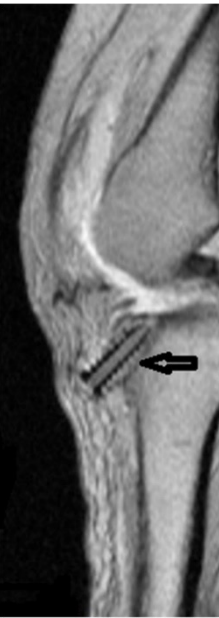- [https://www.arthroscopytechniques.org/article/S2212-6287\(17\)30131-7/pdf](https://www.arthroscopytechniques.org/article/S2212-6287(17)30131-7/pdf)



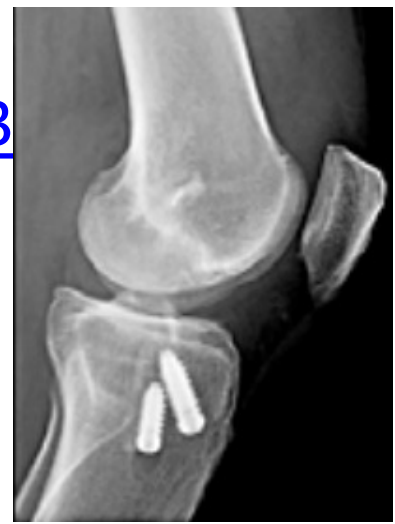- <https://www.leopinczewski.com.au/wp-content/uploads/2018/08/Randomized-Controlled-Trial-of-Osteoconductive-Fixation-Screws-for-Anterior-Cruciate-Liga-Reconstruction.pdf>



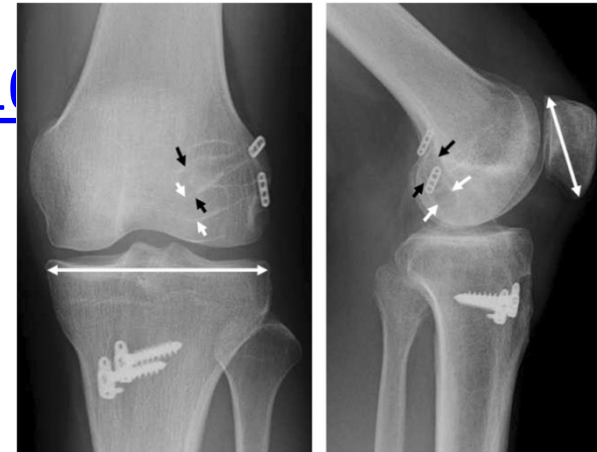
- <https://bmcmusculoskeletdisord.biomedcentral.com/articles/10.1186/s12891-021-04387-2>



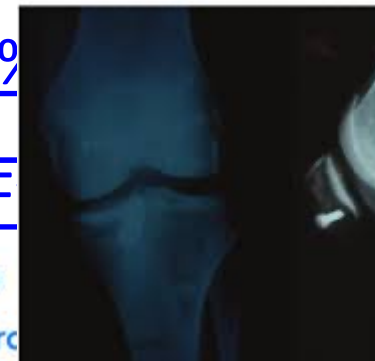- [https://www.arthroscopytechniques.org/article/S2212-6287\(17\)30137/pdf](https://www.arthroscopytechniques.org/article/S2212-6287(17)30137/pdf)



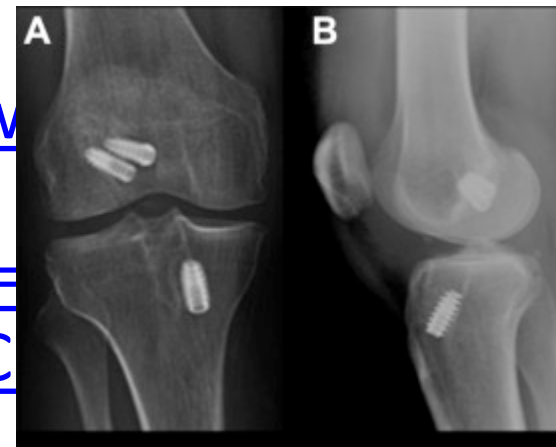
- <https://bmc-musculoskeletal-disorders.biomedcentral.com/articles/10.1186/s12948-019-2653-6>



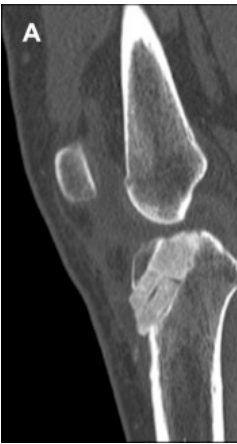- https://www.google.com/url?sa=i&url=http%3A%2F%2Fwww.jrpms.eu%2Farticles%2Fjrpms_v02i04_136.pdf&psig=AOvVaw3kt5R7kBKTZOeT2k16H&ust=1652883051829000&source=images&cd=vfe&ved=0CAwQjRxqFhTCNiWgq3c5vcCFQAAAAAdAAAAABBF



• [https://www.google.com/url?sa=i&url=https%3A%2F%2Fwww.scopytechniques.org%2Farticle%2FS2212-6287\(17\)30131-7%2Ffulltext&psig=AOvVaw3kt5R7kBKTZOeT2k16 k6H&ust=051829000&source=images&cd=vfe&ved=0CA0QjhxqFwoTC5vcCFQAAAAAdAAAAABBq](https://www.google.com/url?sa=i&url=https%3A%2F%2Fwww.scopytechniques.org%2Farticle%2FS2212-6287(17)30131-7%2Ffulltext&psig=AOvVaw3kt5R7kBKTZOeT2k16 k6H&ust=051829000&source=images&cd=vfe&ved=0CA0QjhxqFwoTC5vcCFQAAAAAdAAAAABBq)



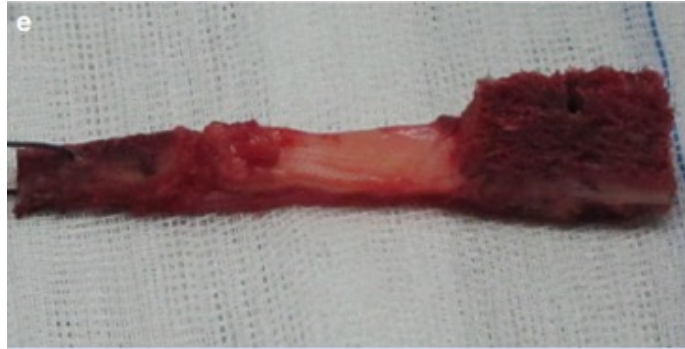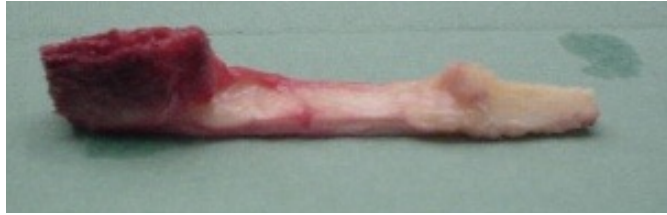• [https://www.google.com/url?sa=i&url=https%3A%2F%2Fwww.arthroscopytechniques.org%2Farticle%2FS2212-6287\(17\)30131-7%2Ffulltext&psig=AOvVaw3kt5R7kBKTZOeT2k16 k6H&ust=1652883051829000&source=images&cd=vfe&ved=0CA0QjhxqFwoTCNiWgq3c5vcCFQAAAAAdAAAAABBq](https://www.google.com/url?sa=i&url=https%3A%2F%2Fwww.arthroscopytechniques.org%2Farticle%2FS2212-6287(17)30131-7%2Ffulltext&psig=AOvVaw3kt5R7kBKTZOeT2k16 k6H&ust=1652883051829000&source=images&cd=vfe&ved=0CA0QjhxqFwoTCNiWgq3c5vcCFQAAAAAdAAAAABBq)



• [https://www.google.com/url?sa=i&url=https%3A%2F%2Fwww.arthroscopytechniques.org%2Farticle%2FS2212-6287\(17\)30131-7%2Ffulltext&psig=AOvVaw3kt5R7kBKTZOeT2k16 k6H&ust=1652883051829000&source=images&cd=vfe&ved=0CA0QjhxqFwoTCNiWgq3c5vcCFQAAAAAdAAAAABBq](https://www.google.com/url?sa=i&url=https%3A%2F%2Fwww.arthroscopytechniques.org%2Farticle%2FS2212-6287(17)30131-7%2Ffulltext&psig=AOvVaw3kt5R7kBKTZOeT2k16 k6H&ust=1652883051829000&source=images&cd=vfe&ved=0CA0QjhxqFwoTCNiWgq3c5vcCFQAAAAAdAAAAABBq)



- <https://www.google.com/url?sa=i&url=https%3A%2F%2Fwww.caringmedical.com%2Fprolotherapy-news%2Facl-reconstruction-complications%2F&psig=AOvVaw0gi2nbNP3IWGjb9WgMLzp9&ust=1652884638689000&source=images&cd=vfe&ved=0CAwQjRxqFwoTCMD8pKHi5vcCFQAAAAAdAAAAABAI>
- [https://www.arthroscopyjournal.org/article/S0749-8063\(00\)70009-0/fulltext](https://www.arthroscopyjournal.org/article/S0749-8063(00)70009-0/fulltext)




COMPLICATIONS ACL RECONSTRUCTION

INSTABILITY & STIFFNESS & PAIN

- Non-anatomic graft placement
- Inadequate graft fixation
- Incorrect graft tension
- Cyclops/Notch impingement
- Capsulitis/arthrofibrosis
- Immobilization/exce. protection
- Overcorrection (DB)
- DVT & PE
- Reflex sympathetic dystrophy
- Infection
- Anterior knee pain
- Patellar fracture (Acu/Late)
- Small/thin bone plug/graft
- Patella baja
- Late patella tendon rupture
- MCL injury
- Saphenous nerve injury
- Sciatic nerve/ popliteal arterial injury
- Quadriceps weakness
- Hamstring weakness
(internal rotation deficit)

Sabat D, et al, 2013 KSSTA


CUT-OFF ON INJURED KNEES (STRESS VS NS) N=61



“Global Laxity”

MP + LP - global translation - better specificity

LP_{IR} + LP_{ER} - global rotation (lateral plateau) - better sensitivity



Parameter	Cut-off (mm)	Sensitivity (%)	Specificity (%)
MPpa	<3.5	72.1	87.5
LPpa	<4.3	73.8	81.3
LPpa+MPpa	<11.1	86.9	93.8
LP _{IR} +LP _{ER}	<15.1	92.9	80.0