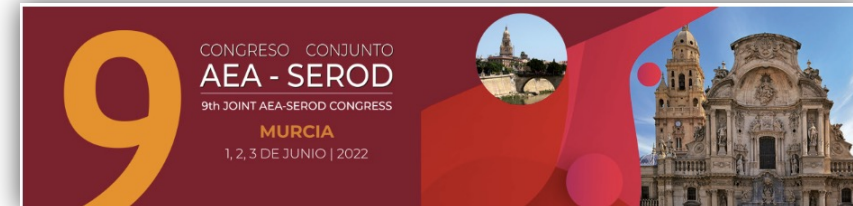

# Manejo del defecto óseo posterior ¿Cuándo y cómo?

**Dr. Xavier Rius**

**Servicio Cirugía Ortopédica i Traumatología**

**Hospital Universitari de Bellvitge**

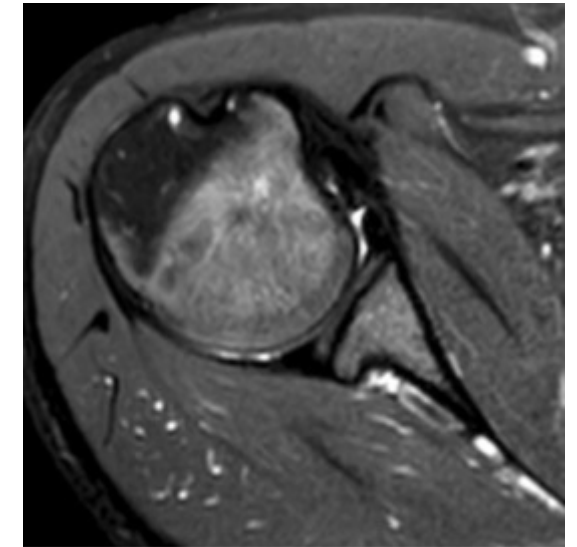
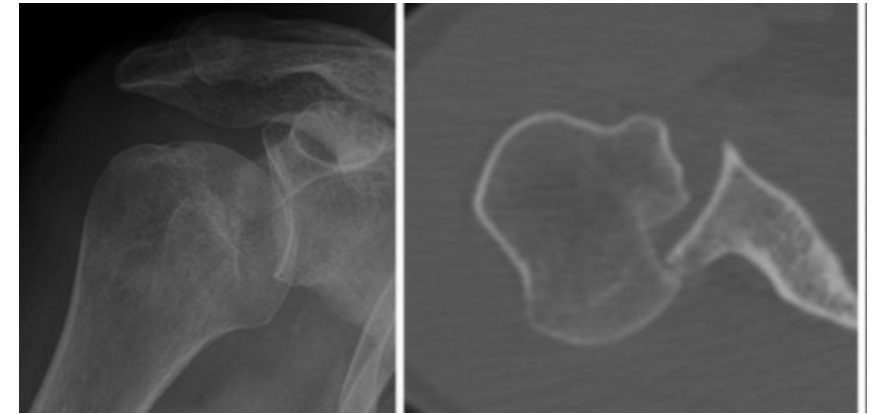
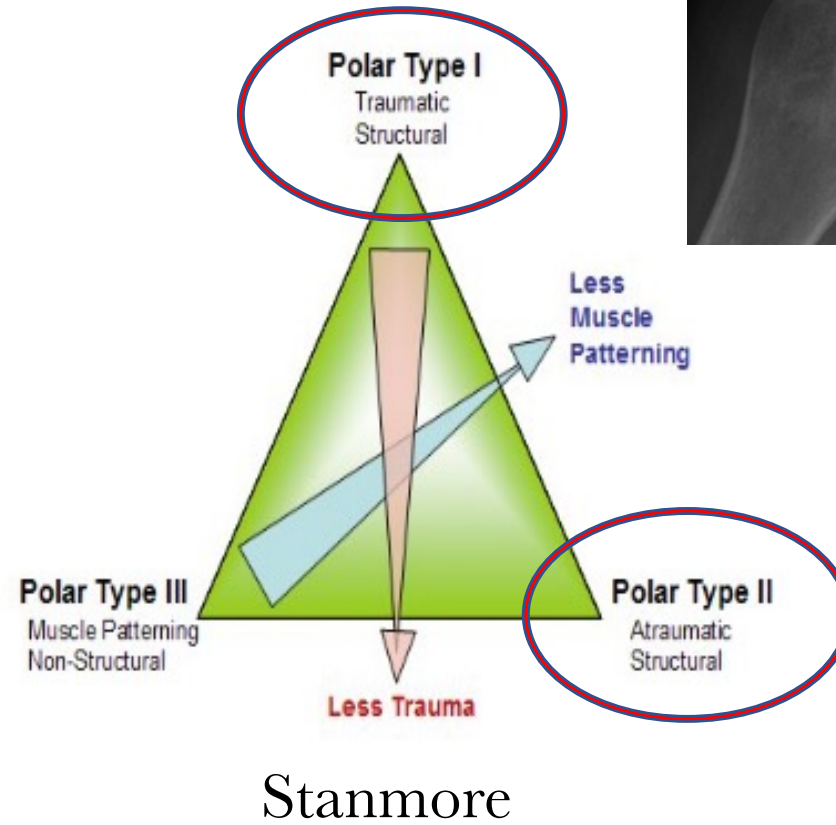
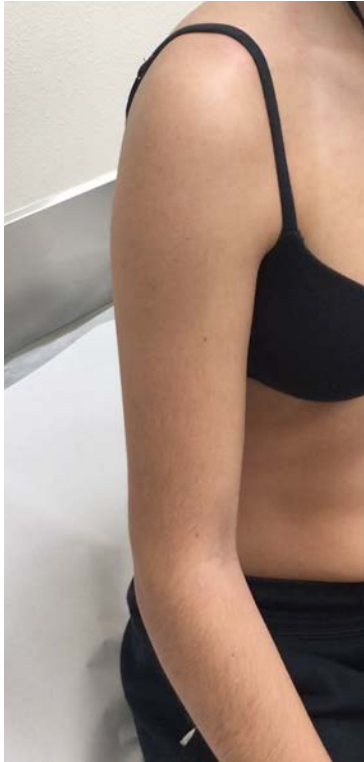

... ¿ Cuándo ?



# Definición del paciente...

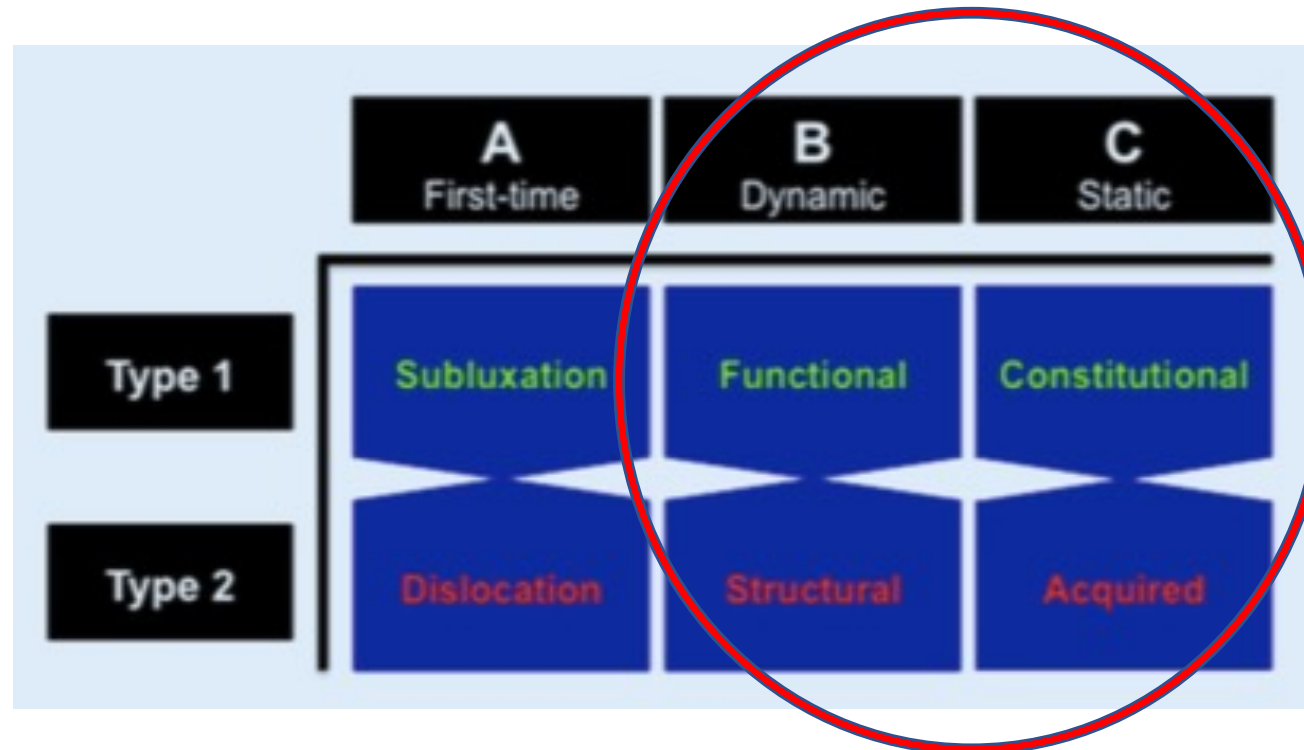
## Biomecánica



# Definición del paciente...

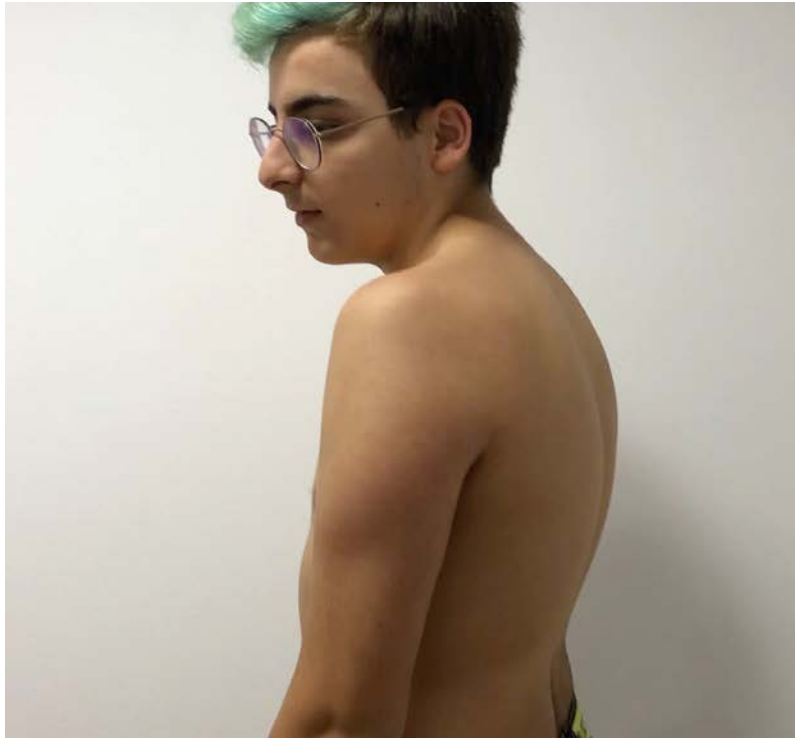## Biomecánica

The ABC classification.

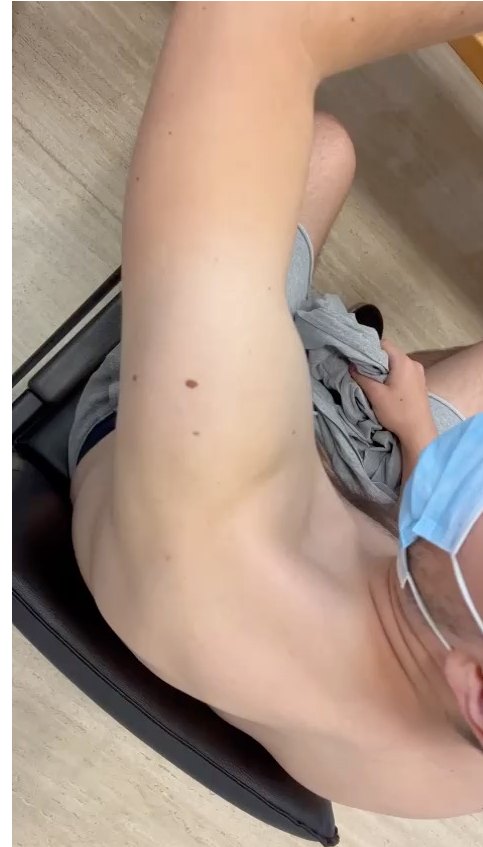

Moroder et al. Obere Extremitat. 2017

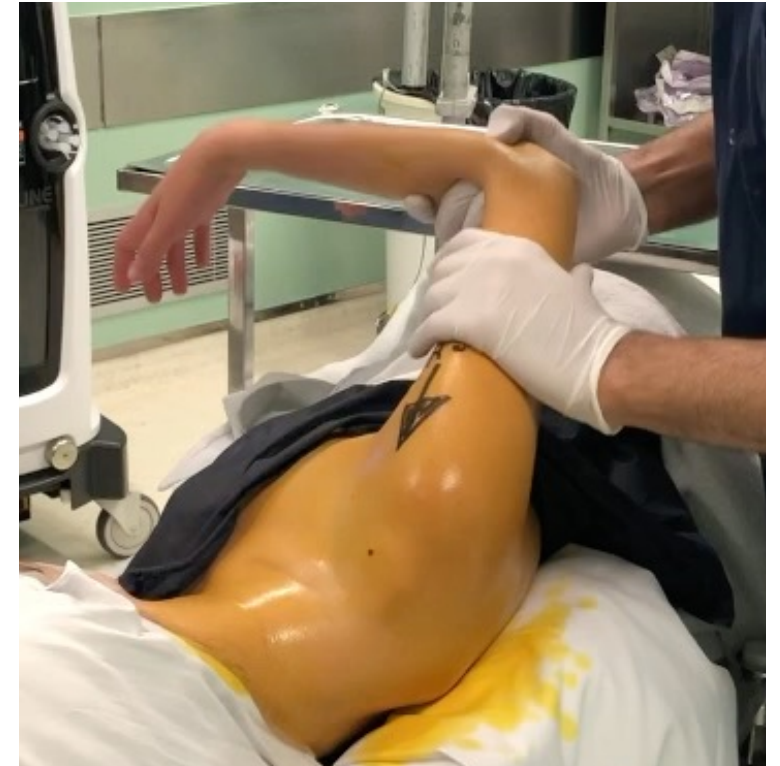# Funcionales ...



B1

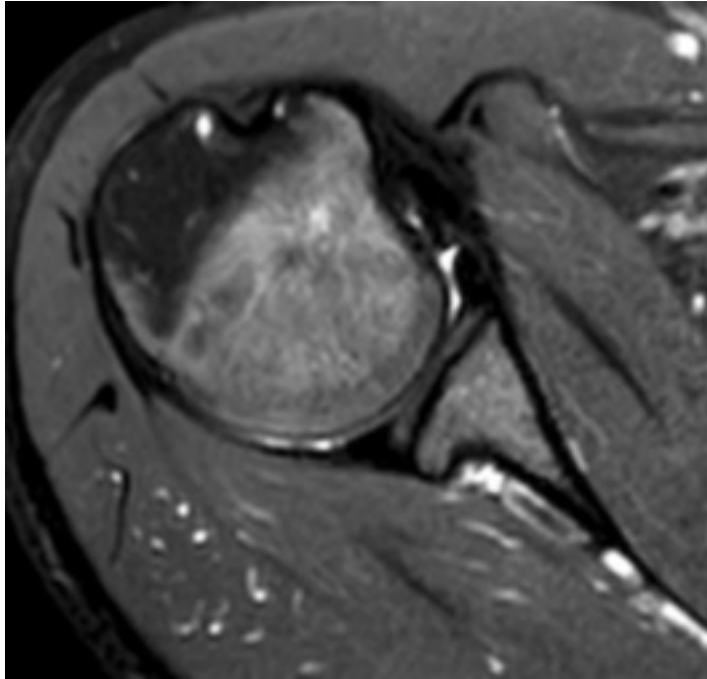


B1

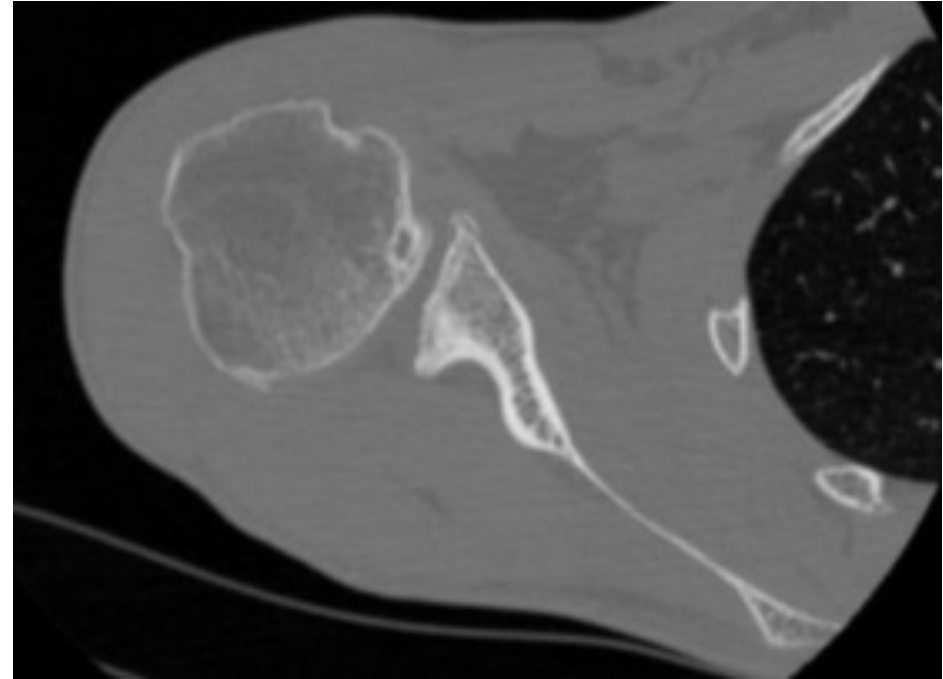


B2

# Estáticos ...



C1



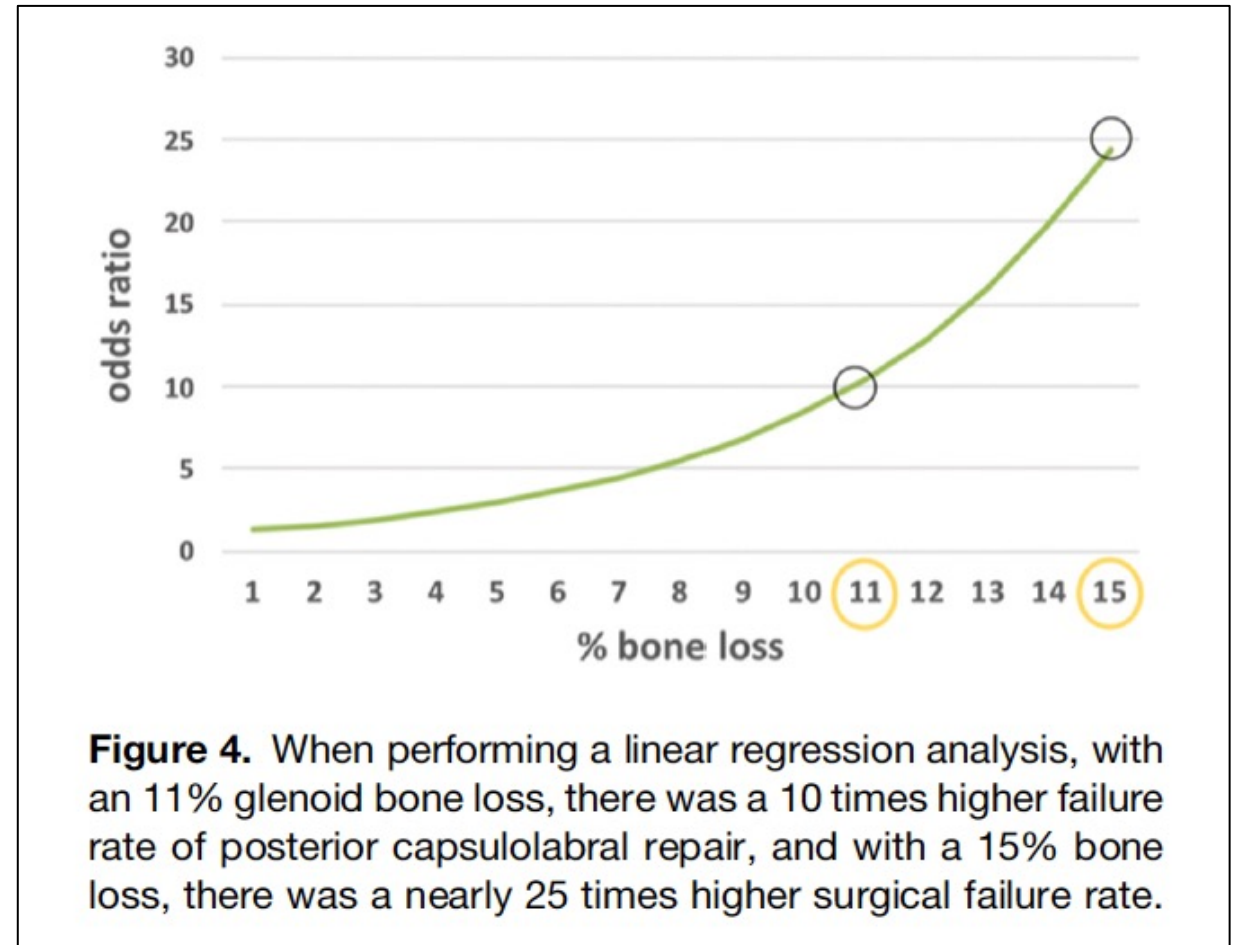
C2

# Definición del paciente...

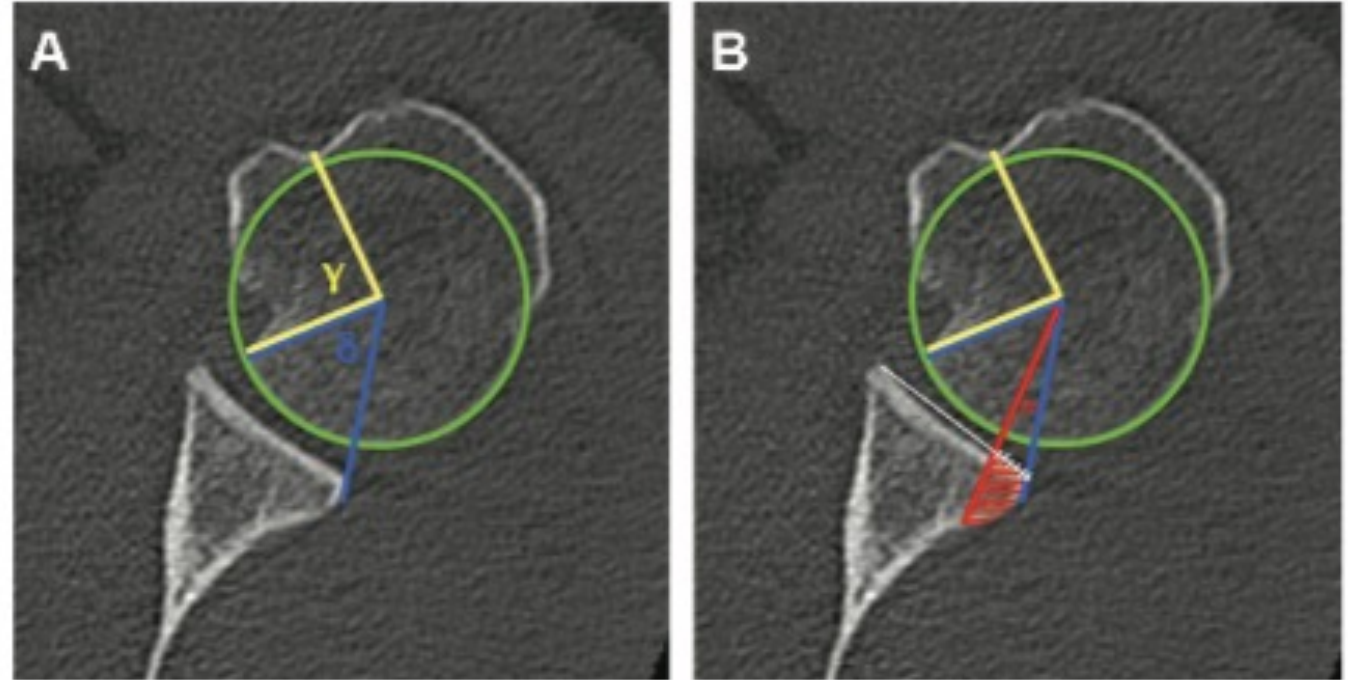
## Defecto glenoideo

### Defining Critical Glenoid Bone Loss in Posterior Shoulder Capsulolabral Repair

Justin W. Arner,\* MD, Joseph J. Ruzbarsky,† MD, Kaare Midtgaard,† MD, Liam Peebles,‡ BS, James P. Bradley,\* MD, and Matthew T. Provencher,†§ MD, CAPT, MC, USNR (Ret.)  
Investigation performed at the Steadman Clinic and Steadman Philippon Research Institute, Vail, Colorado, USA



# Definición del paciente... Defecto bipolar

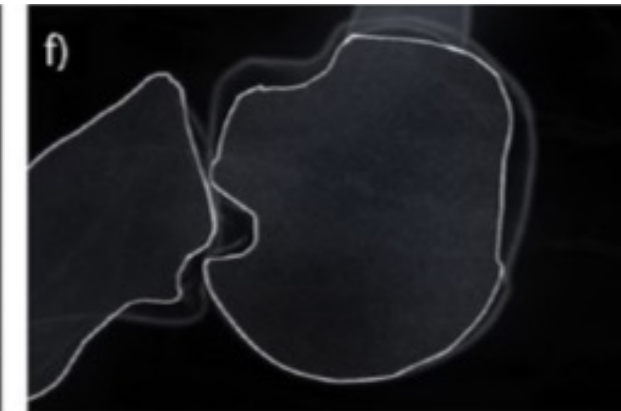
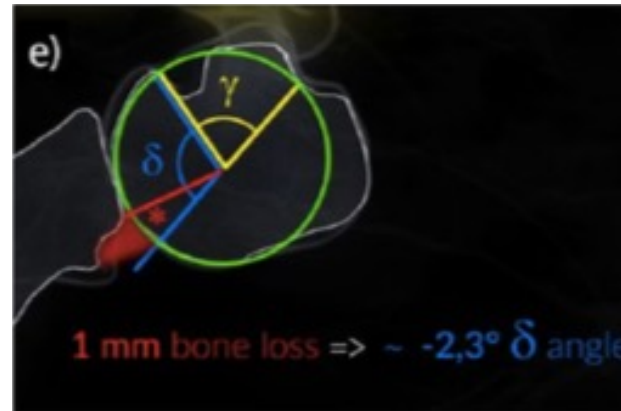
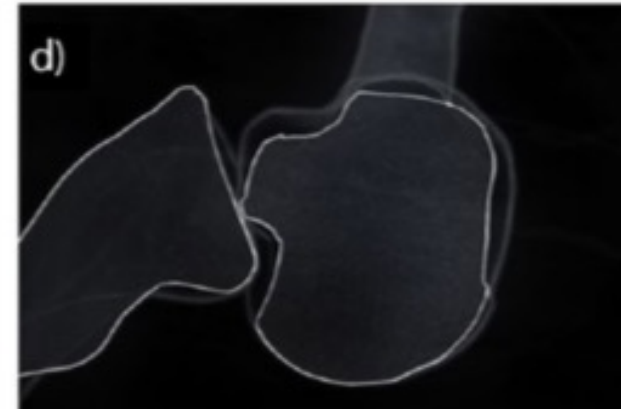
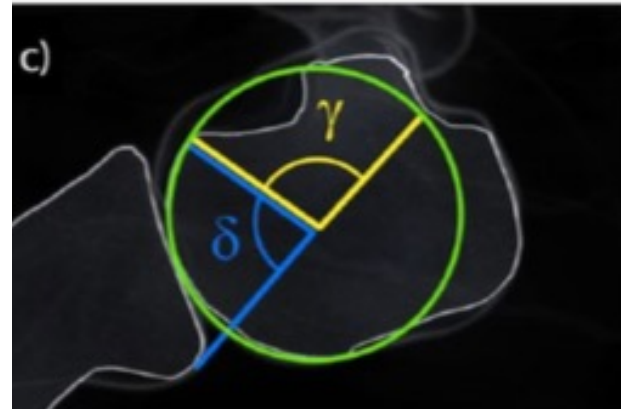
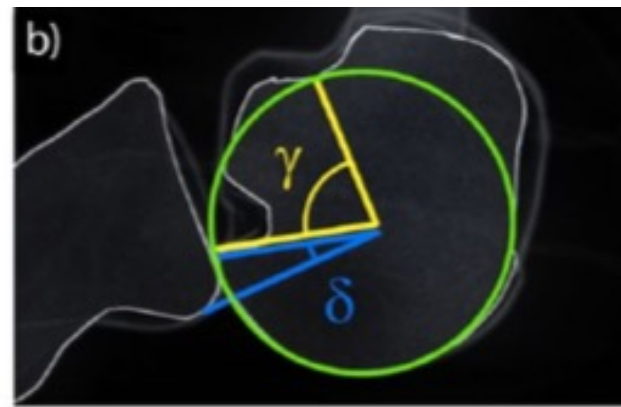
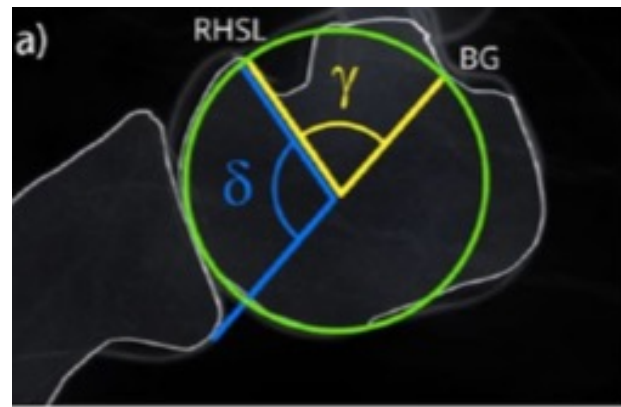


## Risk of Engagement of Bipolar Bone Defects in Posterior Shoulder Instability

Philipp Moroder,<sup>\*†</sup> MD, Fabian Plachel,<sup>††</sup> MD, Mark Tauber,<sup>§</sup> MD, Peter Habermeyer,<sup>§</sup> MD, Andreas Imhoff,<sup>||</sup> MD, Dennis Liem,<sup>¶</sup> MD, Helmut Lill,<sup>#</sup> MD, Herbert Resch,<sup>‡</sup> MD, Christian Gerhardt,<sup>†</sup> MD, and Markus Scheibel,<sup>†</sup> MD

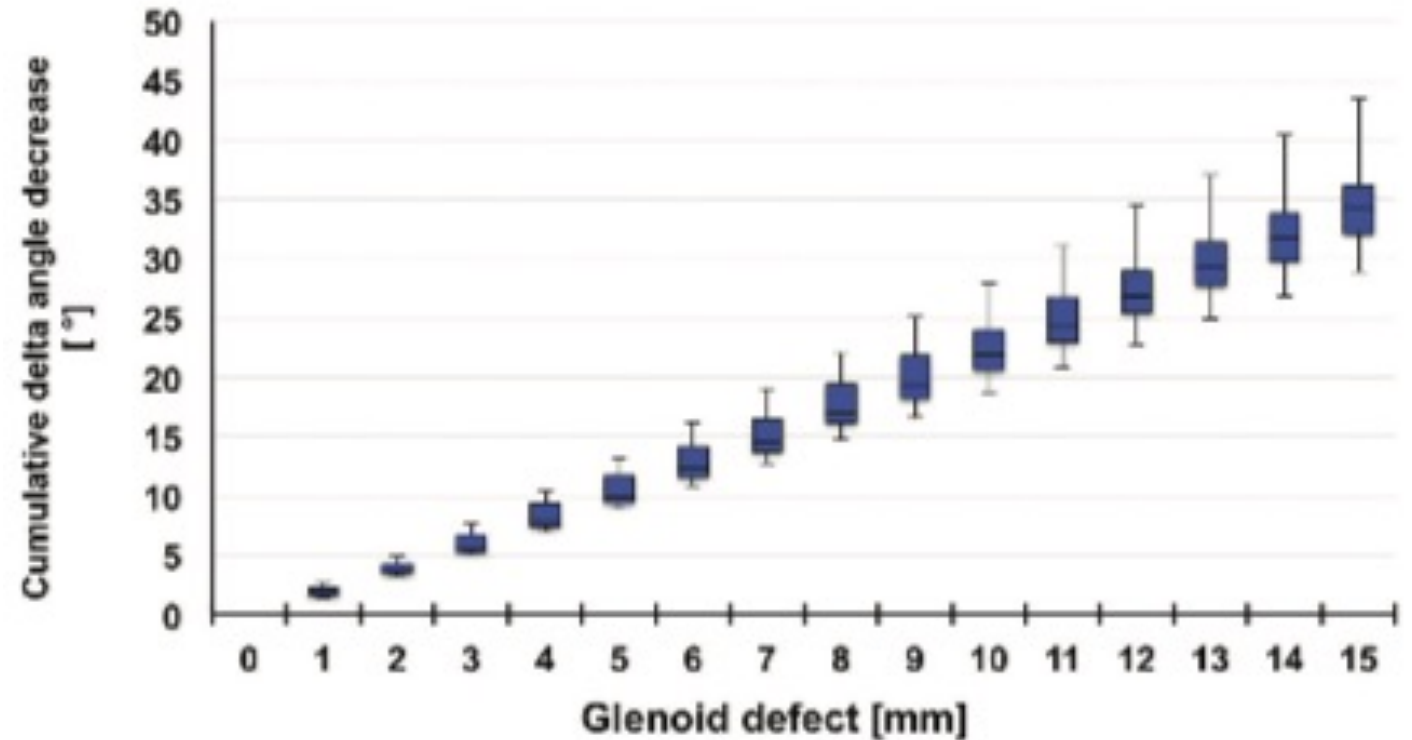
*Investigation performed by the German Society for Shoulder and Elbow Surgery (DVSE)*





# Definición del paciente...

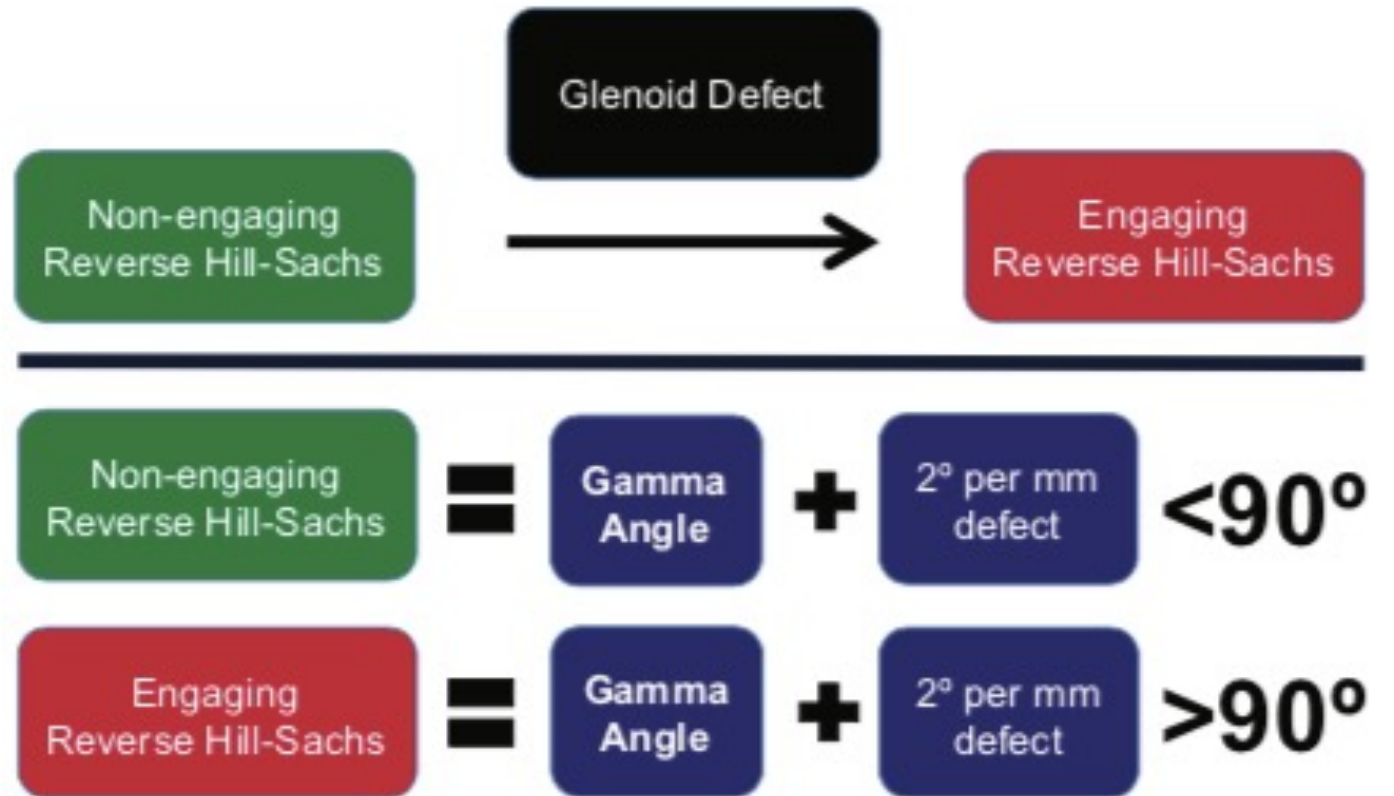
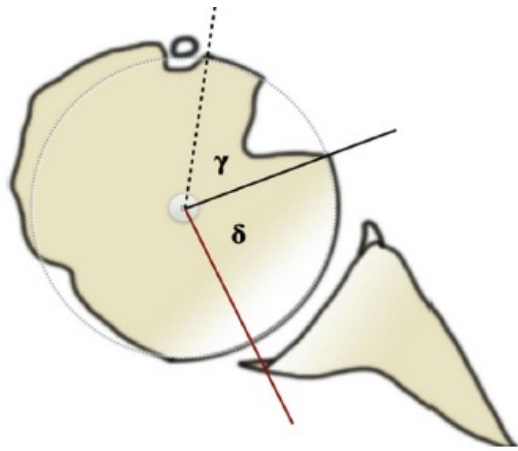
## Defecto bipolar



### Risk of Engagement of Bipolar Bone Defects in Posterior Shoulder Instability

Philipp Moroder,<sup>\*†</sup> MD, Fabian Plachel,<sup>†‡</sup> MD, Mark Tauber,<sup>§</sup> MD, Peter Habermeyer,<sup>§</sup> MD, Andreas Imhoff,<sup>||</sup> MD, Dennis Liem,<sup>¶</sup> MD, Helmut Lill,<sup>#</sup> MD, Herbert Resch,<sup>‡</sup> MD, Christian Gerhardt,<sup>†</sup> MD, and Markus Scheibel,<sup>†</sup> MD  
*Investigation performed by the German Society for Shoulder and Elbow Surgery (DVSE)*

# Definición del paciente... Defecto bipolar



... ¿ **Cómo** ?



# Revisión...

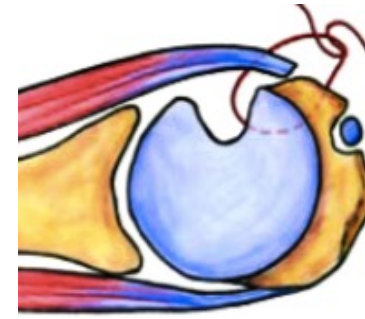
## Tratamiento defecto humeral

### Técnicas no anatómicas:

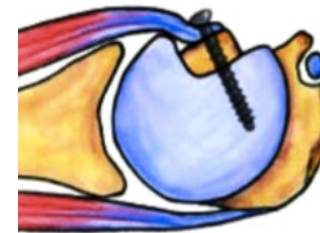
@ “Reverse” Remplissage

Osteotomía rotacional ( NAV )

Baja demanda / Inveteradas ( ¿artroplastias? )



McLaughlin, 1952



McLaughlin Modificado, Neer, 1987

## Treatment of The Posterior Unstable Shoulder

Eduardo Sánchez Alepuz<sup>1,\*</sup>, Jaime Alonso Pérez-Barquero<sup>1</sup>, Nadia Jover Jorge<sup>1</sup>, Francisco Lucas García<sup>2</sup> and Vicente Carratalá Baixauli<sup>2</sup>


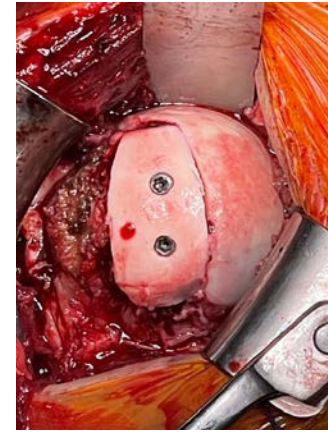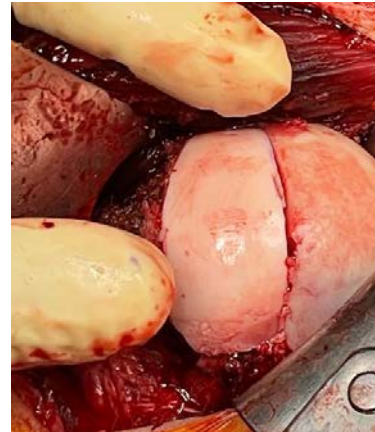
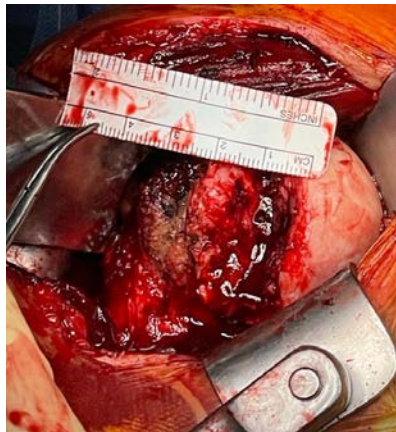# Revisión...

## Tratamiento defecto humeral

### Técnicas anatómicas:

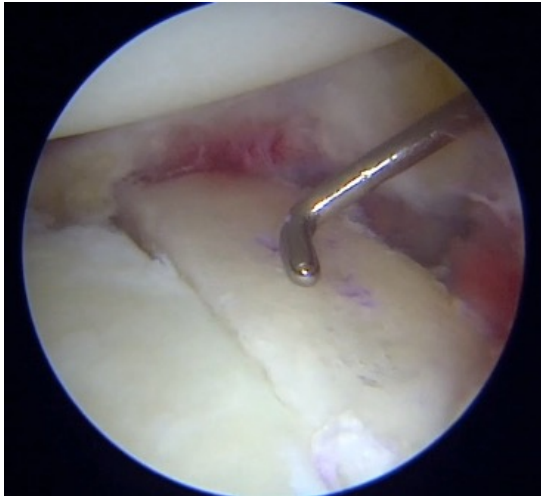Desimpactar – Injertar < 50 % ( ¿¿ cartílago ??)

Aloinjerto estructural > 50 %



# Revisión...

## Tratamiento defecto, displasia / retroversión glenoidea



@ BBC

Arthroscopic “Bone Block Cerclage” Technique for Posterior Shoulder Instability

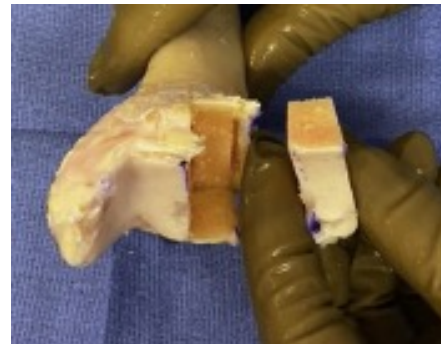Abdul-ilah Hachem, M.D., Rafael Rondanelli, M.D., Gino Costa D’O, M.D., Iñigo Verdalet, M.D., and Xavier Rius, M.D.

### Otros...

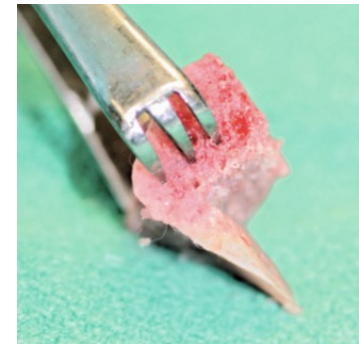
Acromion pediculado  
Clavícula distal  
Osteotomía glenoides ...

Giovanni Di Giacomo • Alberto Costantini  
Andrea De Vita • Nicola de Gasperis

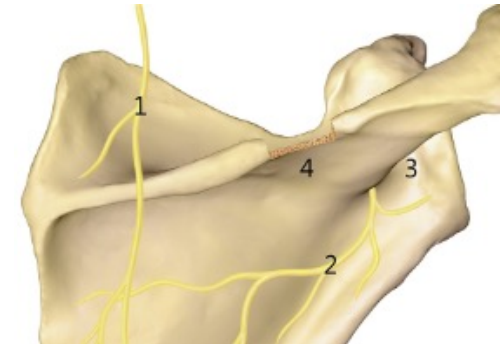
## Shoulder Instability



Tibia Distal



Injerto “J”



Espina escapula

**Unpublished**



**EFORT** open reviews

**Bone block augmentation for recurrent posterior shoulder instability: surgical indications and a description of an arthroscopic technique**

Journal:	<i>EFORT Open Reviews</i>
Manuscript ID	EOR-2022-0009.R2
Manuscript Type:	Review Article
Keywords:	Shoulder, Recurrent Posterior Instability, Bone Block

Hachem et al. 2022



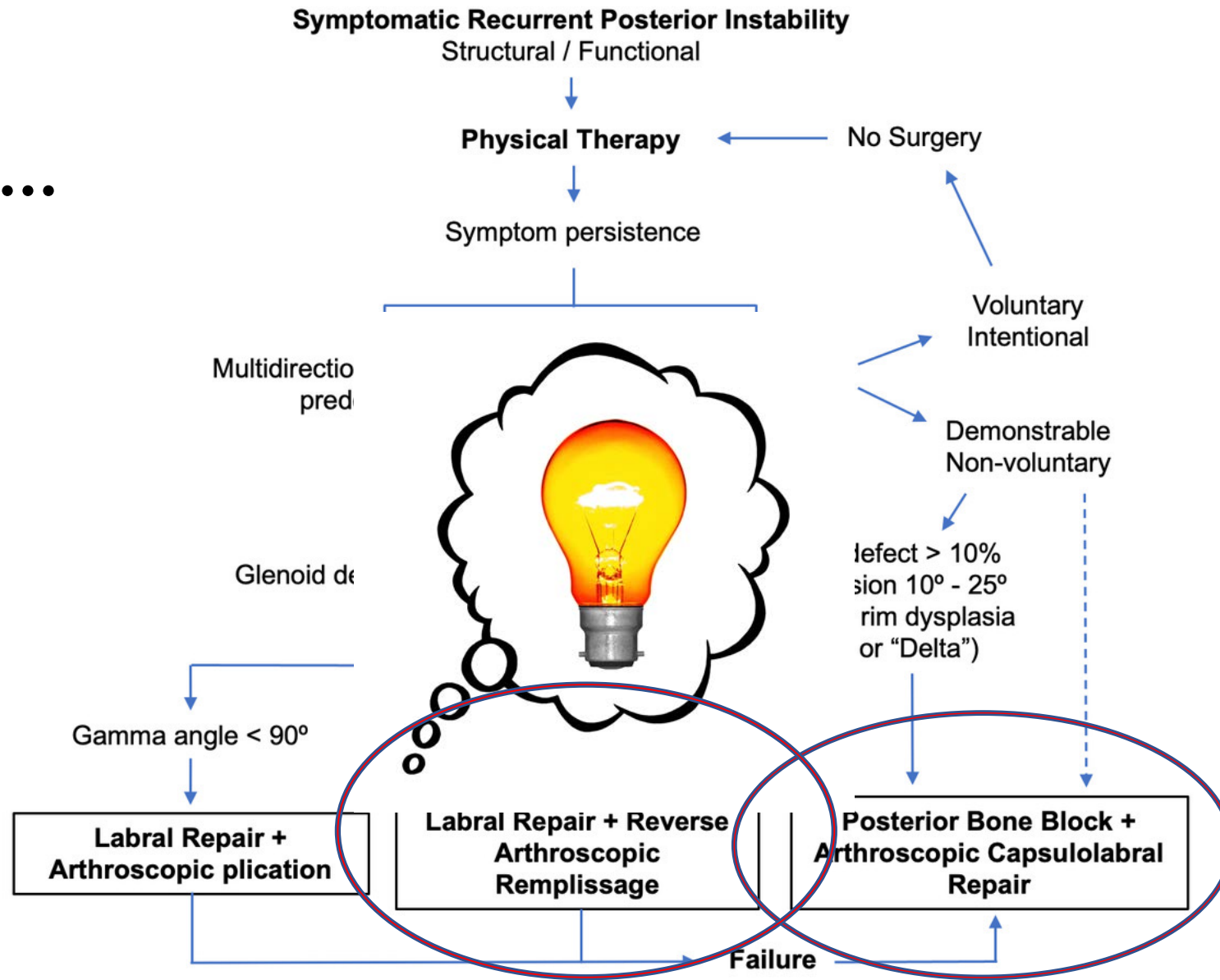
**Unpublished**

#	Onset	Demonstrable instability	Shoulder Hypermobility	Glenoid defect > 10%	Glenoid rim dysplasia	Retroversion	Failed Previous surgery	Poor posterior soft tissue
1	Non-Traumatic	-	-	Yes	-	-	-	-
2	Non-Traumatic	Yes	Yes	-	-	-	-	Yes
3	Non-Traumatic	Yes	Yes	-	-	Yes	-	-
4	Non-Traumatic	-	-	Yes	-	-	Yes	-
5	Non-Traumatic	Yes	Yes	-	Yes	-	Yes	-
6	Traumatic	-	-	Yes	-	-	Yes	-
7	Traumatic	Yes	Yes	Yes	-	-	-	-
8	Non-Traumatic	Yes	-	Yes	-	-	Yes	Yes

Hachem et al. 2022

# Algoritmo Propuesto...

Unpublished



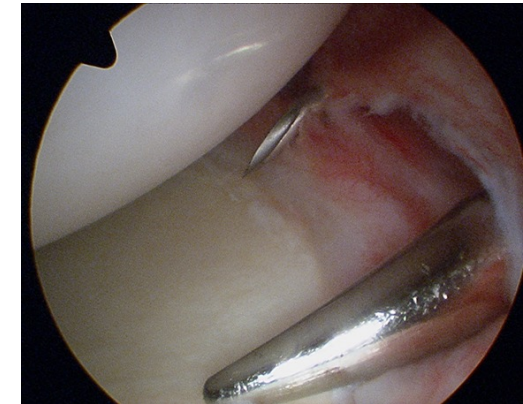
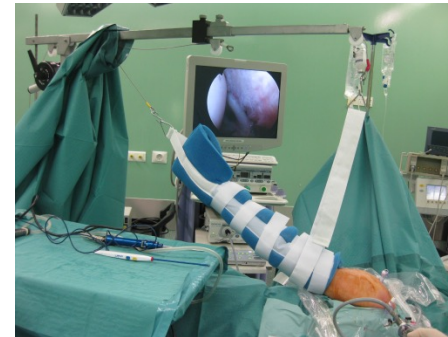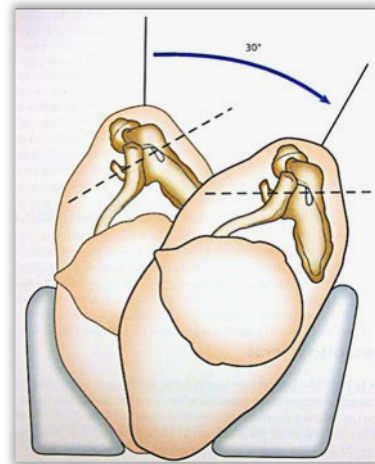
# Antes de empezar...

**Exploración bajo anestesia**

**Portales percutáneos 5 y 7**

**Pasadores hilos indirectos**

**Implantes todo hilos sin nudos**

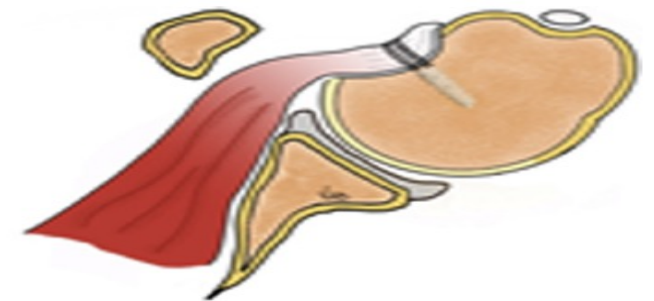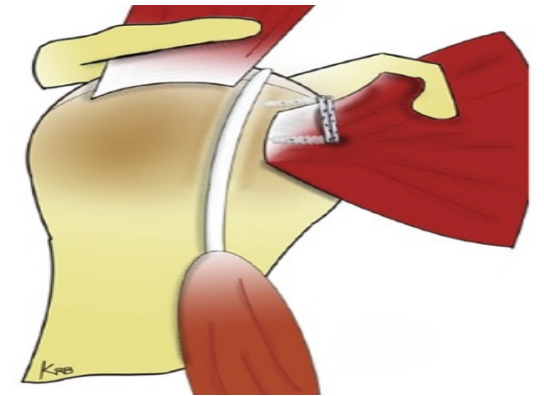
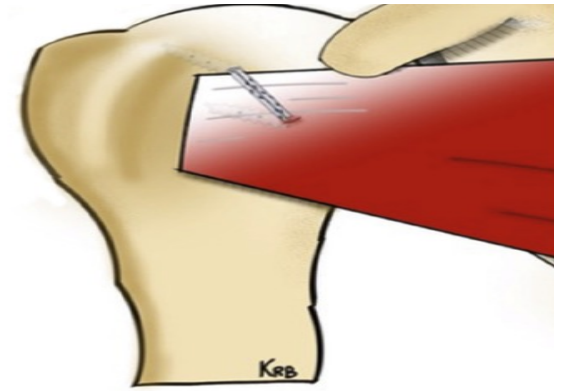


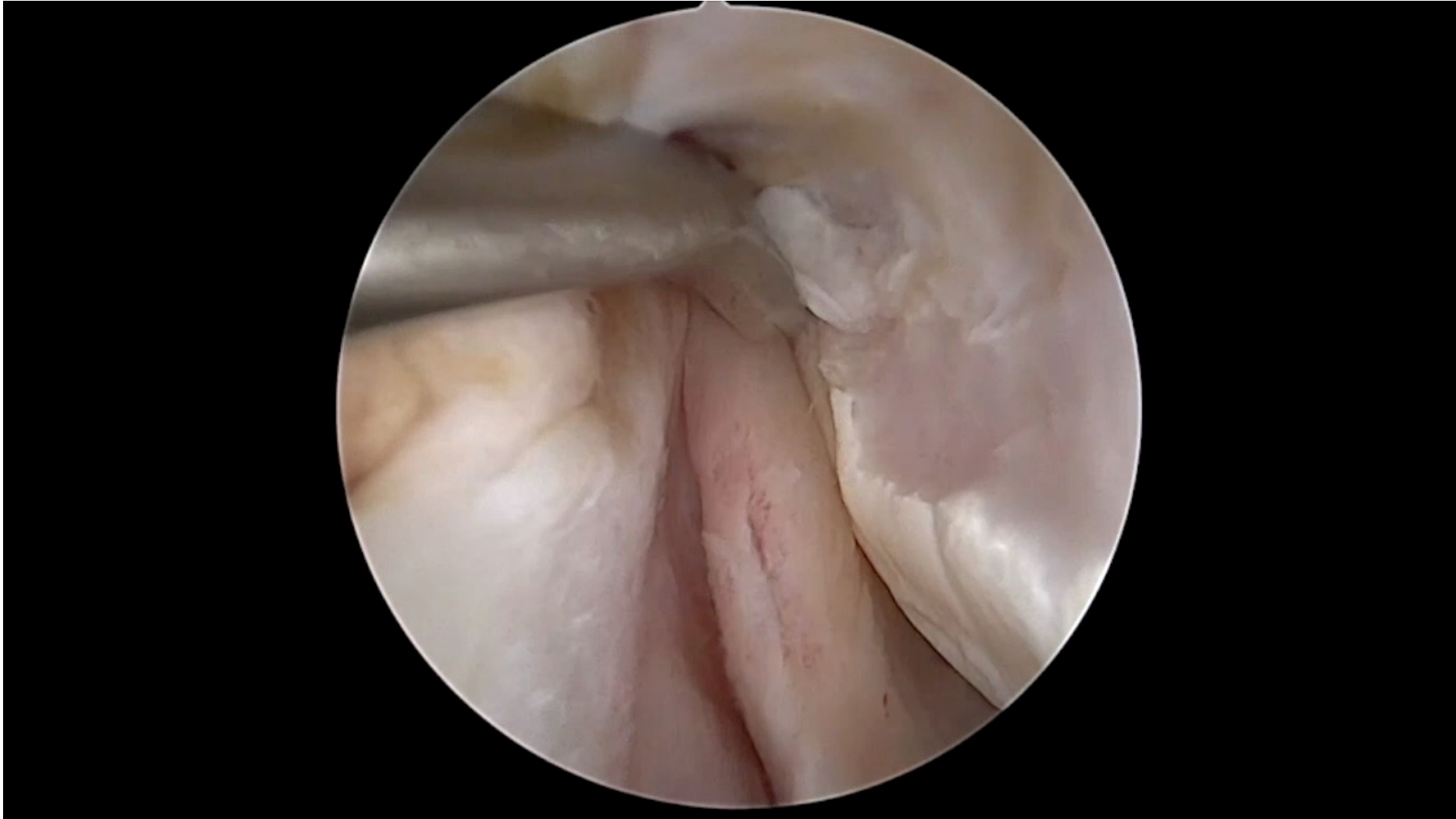# @ “Reverse” Remplissage Subscapular bridge

**Glenoides < 10 %**  
**Gamma >90°**

Arthroscopic Knotless Subscapularis Bridge  
Technique for Reverse Hill-Sachs Lesion With  
Posterior Shoulder Instability

Abdul-ilah Hachem, M.D., Karla R. Bascones, M.D., Gino Costa D’O, M.D.,  
Rafael Rondanelli S, M.D., and Xavi Rius, M.D.





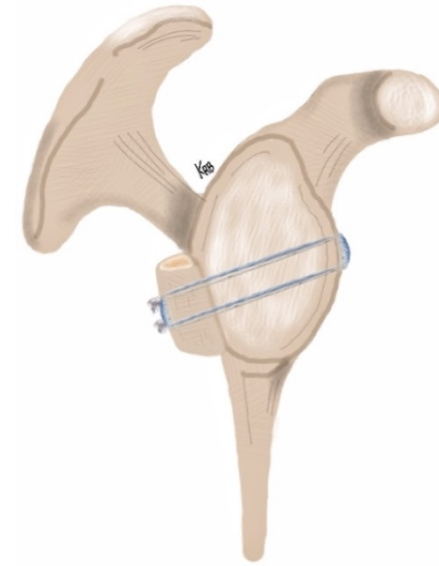
# @ Posterior Bone Block Cerclage

**Retroversión > 15° / Displasia**

**Defecto óseo > 10%**

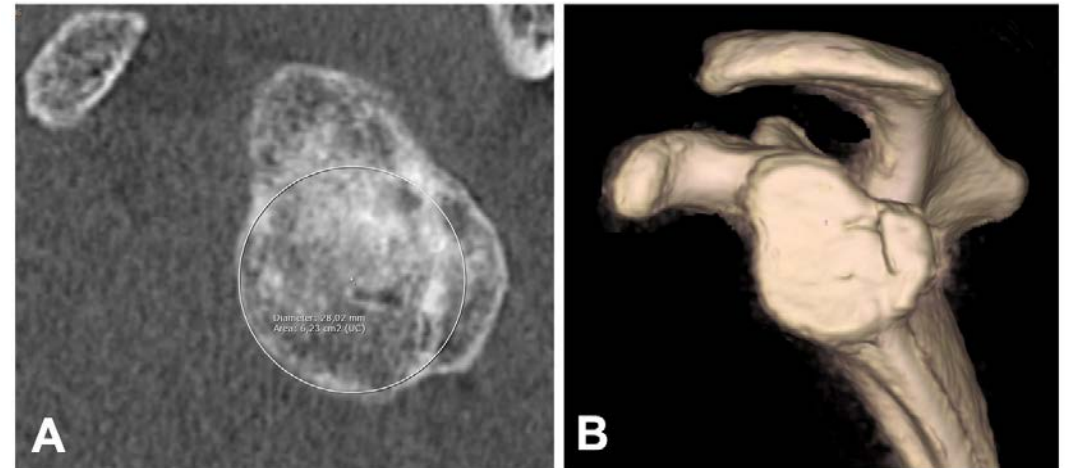
**Demostrable Involuntaria**

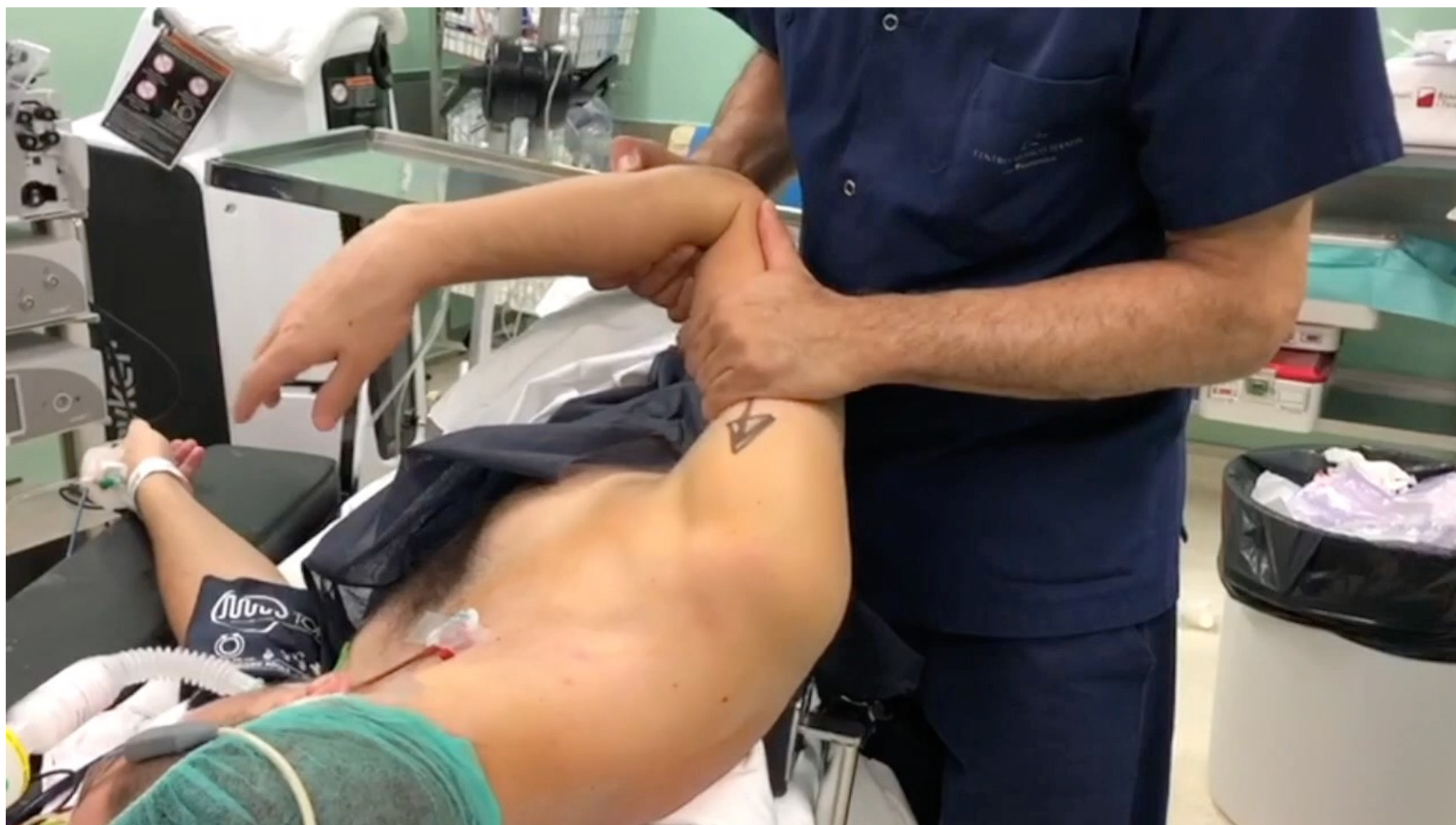**Fracaso de la reparación labral**



Arthroscopic “Bone Block Cerclage” Technique for  
Posterior Shoulder Instability

Abdul-ilah Hachem, M.D., Rafael Rondanelli, M.D., Gino Costa D’O, M.D.,  
Iñigo Verdalet, M.D., and Xavier Rius, M.D.





DANKSCHEEN  
 SHUKURIA  
 GRACIAS  
 ARIGATO  
 SHUKURIA  
 TASHAKKUR ATU  
 YAQHANYELAY  
 SUKSAMA  
 MEHRBANI  
 MAAKE  
 GRAZIE  
 BOLZIN  
 TINGKI  
 BIYAN  
 SHUKRIA  
 THANK  
 YOU  
 MERCY


**Bellvitge**  
 Hospital Universitari

[jrius@bellvitgehospital.cat](mailto:jrius@bellvitgehospital.cat)