

9 CONGRESO CONJUNTO
AEA - SEROD
9th JOINT AEA-SEROD CONGRESS


MURCIA
1, 2, 3 DE JUNIO | 2022


REACA: escuela de autores

Jorge Díaz Heredia
Unidad Hombro y Codo


SaludMadrid **Hospital Universitario
Ramón y Cajal**

www.fichasdecaligrafia.com





"EARLY POSTOPERATIVE TRANSTIBIAL ARTICULAR FISTULA FORMATION AFTER ANTERIOR CRUCIATE LIGAMENT RECONSTRUCTION: A REVIEW OF 3 CASES"

Comments to authors

GENERAL

The authors report on three cases. Those cases had postoperative fistula formation on the tibial side after transtibial approach to an ACL reconstruction.

These are three case reports that are quite similar. It is correct that this is uncommon. I don't think this has anything to do with surgical technique or tibial fixation methods. This is something that sometimes happens. Probably it is due to mismatch in the graft size and the tunnel size.

I have seen this on a few occasions during my long career. I have also seen this happens late and there is nothing really new in this context. The scientific value of this paper is therefore limited. It might be correlated to the bioabsorbable screws, however there is very little proof here.

In two of the cases there was persistent wound drainage and in the third case there was a pretibial cyst. The interesting thing is how the authors treated this. In previous studies on this authors have treated with bone transplantation. This was not done and the fistulas were just closed.

I think this should be considered as a technical note. However, the news value is very, very limited. I really doubt that no bone transplantation was performed in order to close the bone tunnels and I question this approach. I have seen this happen also late after ACL surgery.

The conclusions are somewhat speculative. The figures do not add anything. References are reasonable, however, for papers already in print DOI numbers should be deleted.

My suggestion is to reject this paper due to the low scientific news value.

Numbered Reviewer Remark and Manuscript Line Number	Author Response	Revised Manuscript Line Number and Text Change
Reviewer 1:		
Needs to be structured according to Author guidelines	Done	Line 6-23
Line 10 early postoperative phase. Was MRI performed in all cases	MRI was done only in the third case	Line 119
Line 14 during revision	Corrected	Line 15
Generally well written. A little more detailed Literature presentation on pretibial cyst formation is necessary.	Done	
Line 31 satisfying	Corrected	Line 34
Line 39 pathophysiological	Corrected	Line 50
Line 42 The purpose of this article....(This is a case report!)	Changed	Line 52
Well written and clear protocoll. Body mass index of patients would be interesting	Added	Line 111
Was MRI performed in all cases?	MRI was done only in the third case	Line 119
Line 70 suspension implant	Corrected	Line 81
Blood sample results of case 3 should be added	Added	Line 129
Short result section.	More information included in material, methods and discussion	
Line 164 At ... follow up all patients	Not understand	
How was joint function and stability defined and measured? Detailed decription necessary.	Done	Line 170
Insufficient closure of the periosteum over the tibial drill tunnel seems to be the main reason for the cyst formation.	Added	Line 223
The current article is just a case report, and this should be clearly stated	Changed	Line 253
Line 245 An insufficient suture is more likely as soft tissue healing takes more than 6 days.	Changed	Line 264

Revista Española de Artroscopia y Cirugía Articular

40 AEA
1982-2022

REVISTA OFICIAL DE LA ASOCIACIÓN ESPAÑOLA DE ARTROSCOPIA (AEA)

Vol. 29. Fasc. 2. Núm. 76. Abril 2022

ISSN: 2386-3129 (Impreso), 2443-9754 (Online)

Editorial

La importancia del control del dolor
S. Moros Marco

Aprendiendo del dolor para mejorar al paciente
L. J. Roca Ruiz

Monográfico: Manejo del dolor perioperatorio en artroscopia

Manejo perioperatorio del dolor en cirugía artroscópica de hombro

P. Carnero Martín de Soto, A. Gómez Cáceres, I. De Rus Aznar, M. Martiarena Moreno, J. Diaz Heredia

Manejo perioperatorio del dolor en artroscopia de codo
S. Moros Marco, J. L. Ávila Lafuente, O. Jacobo Edo, J. M. García Pequeruf

Analgesia perioperatoria en cirugía artroscópica de muñeca y mano

F. Polo Simón, V. Triviño Sánchez-Mayoral, A. C. Prada Cañizares, P. J. Delgado Serrano

Analgesia perioperatoria en artroscopia de cadera
A. Castel Oñate, O. Marín Peña

Analgesia perioperatoria en cirugía artroscópica de rodilla

M. Ibáñez, L. Valls, S. Gil, J. I. Erquicia

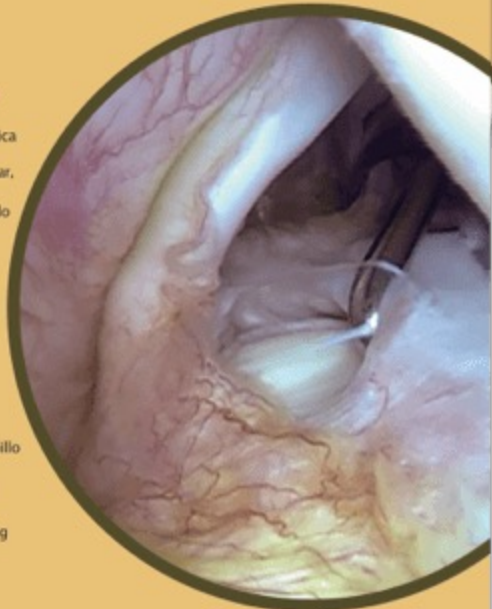
Manejo perioperatorio del dolor en artroscopia de tobillo
A. Lorente Gómez

Dolor neuropático posquirúrgico en traumatología
L. J. Roca Ruiz

Técnica de aplicación del parche de capsaicina 179mg
A. Touza Fernández

Imagen de portada

SLAP tipo 3: desgarro en asa de cubo
K. Rodríguez Bascones



Patrocinadores principales de la AEA:

FS FONDOSCIENCE





Arthrex

CONMED






STORZ

SmithNephew

Escuela de autores



Escuela de autores



Animaros a mandarnos artículos